

# Dental and Medical Problems

QUARTERLY ISSN 1644-387X (PRINT) ISSN 2300-9020 (ONLINE)

[www.dmp.umed.wroc.pl](http://www.dmp.umed.wroc.pl)

2018, Vol. 55, No. 3 (July–September)

Ministry of Science and Higher Education – 11 pts.  
Index Copernicus (ICV) – 109.28 pts.



WROCLAW  
MEDICAL UNIVERSITY



# Dental and Medical Problems

ISSN 1644-387X (PRINT)

ISSN 2300-9020 (ONLINE)

www.dmp.umed.wroc.pl

**QUARTERLY**  
**2018, Vol. 55, No. 3**  
**(July–September)**

“Dental and Medical Problems” is a peer-reviewed open access journal published by Wrocław Medical University and Polish Dental Society. Journal publishes articles from different fields of dentistry and other medical, biological, deontological and historical articles, which were deemed important to dentistry by the Editorial Board – original papers (clinical and experimental), reviews, clinical cases, and letters to the Editorial Board.

## Address of Editorial Office

Marcinkowskiego 2–6  
50-368 Wrocław, Poland  
Tel.: +48 71 784 11 33  
E-mail: dental@umed.wroc.pl

## Publisher

Wrocław Medical University  
Wybrzeże L. Pasteura 1  
50-367 Wrocław, Poland

Polish Dental Society  
Krakowska 26  
50-425 Wrocław, Poland

© Copyright by Wrocław Medical University  
and Polish Dental Society, Wrocław 2018

Online edition is the original version of the journal

## Editor-in-Chief

Tomasz Konopka

## Vice-Editor-in-Chief

Raphael Olszewski

## Thematic Editors

Teresa Bachanek (Cariology)  
Mariusz Lipski (Endodontics)  
Urszula Kaczmarek (Pedodontics  
and Dental Prevention)  
Renata Górka (Oral Pathology)  
Alina Pürienè (Periodontology)  
Piotr Majewski (Implantology)

Andrzej Wojtowicz (Oral Surgery)  
Marcin Kozakiewicz (Maxillofacial Surgery)  
Teresa Sierpińska (Prosthodontics)  
Jolanta Kostrzewa-Janicka (Disorders  
of Mastification System)  
Beata Kawala (Orthodontics)  
Ingrid Różyło-Kalinowska (Dental Radiology)

## International Advisory Board

Akira Aoki (Japan)  
Einar Berg (Norway)  
Wojciech Blonski (USA)  
Maria Buscemi (Italy)  
Ewa Czochrowska (Poland)  
Petr Dítě (Czech Republic)  
Marzena Dominiak (Poland)  
Barbara Dorocka-Bobkowska (Poland)  
Omar El-Mowafy (Canada)  
Katarzyna Emerich (Poland)  
Piotr Fudalej (Switzerland)  
Thomas Gedrange (Germany)  
Hanna Gerber (Poland)  
David Herrera (Spain)  
Michał Jeleń (Poland)  
Milan Kamínek (Czech Republic)  
Kazimierz Kobus (Poland)  
Krystyna Konopka (USA)  
Tadeusz F. Krzemiński (Poland)

Nazan Küçükkeleş (Turkey)  
Monika Łukomska-Szymańska (Poland)  
Marina V. Maevskaya (Russia)  
Marcin Mikulewicz (Poland)  
Joseph Nissan (Israel)  
Hyo-Sang Park (Korea)  
Małgorzata Radwan-Oczko (Poland)  
Monique-Marie Rousset-Caron (France)  
Mykola Mychajlovykh Rozhko (Ukraine)  
Franciszek Szatko (Poland)  
Jacek C. Szepietowski (Poland)  
Selena Toma (Belgium)  
Danuta Waszkiel (Poland)  
Dariusz Wołowicz (Poland)  
Grażyna Wyszyńska-Pawelec (Poland)  
Anna Zalewska (Poland)  
Marek Ziętek (Poland)  
Elena Borisovna Zueva (Uzbekistan)

### **Statistical Editor**

Krzysztof Topolski

### **Technical Editorship**

Adam Barg

Joanna Gudarowska

Paulina Kunicka

Marek Misiak

Aleksandra Raczkowska

### **English Language Copy Editors**

Sherill Howard Pociecha

Jason Schock

Marcin Tereszewski

### **Editorial Policy**

During the review process, the Editorial Board conforms to the "Uniform Requirements for Manuscripts Submitted to Biomedical Journals: Writing and Editing for Biomedical Publication" approved by the International Committee of Medical Journal Editors (<http://www.icmje.org/>). Experimental studies must include a statement that the experimental protocol and informed consent procedure were in compliance with the Helsinki Convention and were approved by the ethics committee.

Indexed in: MEDLINE, Scopus, GFMER, Index Copernicus, Ministry of Science and Higher Education, CiteFactor, WorldCat, Directory of Research Journal Indexing.

This publication has been co-financed by the Ministry of Science and Higher Education.

Typographic design: Monika Kołęda, Piotr Gil

Cover: Monika Kołęda

DTP: Wrocław Medical University Press

Printing and binding: EXDRUK

## Contents

### Original papers

- 233 Tolga Genç, Onurcem Duruel, Hüseyin Burak Kutlu, Erhan Dursun, Erdem Karabulut, Tolga Fikret Tözüm  
**Evaluation of anatomical structures and variations in the maxilla and the mandible before dental implant treatment**
- 241 Asmaa Mohammad Alammam, Omar Ahmad Heshmeh  
**Lip repositioning with a myotomy of the elevator muscles for the management of a gummy smile**
- 247 Elham Fathy Mahmoud, Ola Moustafa Omar  
**Erosive and cariogenic potential of various pediatric liquid medicaments on primary tooth enamel: A SEM study**
- 255 Alma Y. Ceballos-Jiménez, Laura E. Rodríguez-Vilchis, Rosalía Contreras-Bulnes, Jesús Á. Arenas Alatorre, Ulises Velazquez-Enriquez, Maria M. García-Fabila  
**Acid resistance of dental enamel treated with remineralizing agents, Er:YAG laser and combined treatments**
- 261 Alper Özdoğan, Musa Şamil Akyıl, Zeynep Yeşil Duymuş  
**Evaluating the microleakage between dentin and composite materials**
- 267 Pezhman Hadadi, Farzane Ostovarrad, Ava Nikbin, Hadi Ranjzad, Farzane Ghasemi, Somayeh Nemati  
**Evaluation of the gray level of restorative materials using cone-beam computed tomography: A cross-sectional study**
- 275 Eshamsul Sulaiman, Nada Alarami, Yuh Ing Wong, Wen Hui Lee, Afaf Al-Haddad  
**The effect of fiber post location on fracture resistance of endodontically treated maxillary premolars**
- 281 Aneta Furtak, Elżbieta Leszczyńska, Aleksandra Sender-Janeczek, Wojciech Bednarz  
**The repeatability and reproducibility of gingival thickness measurement with an ultrasonic device**
- 289 Bartłomiej Górski, Tomasz Kaczyński, Andrzej Miskiewicz, Renata Górski  
**Early postoperative healing following guided tissue regeneration in aggressive periodontitis patients**
- 299 Tahmineh Razi, Sedigheh Razi  
**Association between the morphology and thickness of bony components of the temporomandibular joint and gender, age and remaining teeth on cone beam CT images**
- 305 Vahid Molabashi, Masoud Abolvardi, Marzieh Akhlaghian, Mohammad Ibrahim Ghaffari  
**Smile attractiveness perception regarding buccal corridor size among different facial types**
- 313 Renata Górski, Bartłomiej Górski  
**Self-reported oral status and habits related to oral care in adult Poles: A questionnaire study**

### Reviews

- 321 Tuqa Rashad Raghis, Ghiath Mahmoud, Omar Hamadah  
**Effectiveness of laser irradiation in preventing enamel demineralization during orthodontic treatment: A systematic review**
- 333 Małgorzata Szulc, Aneta Zakrzewska, Jacek Zborowski  
**Local drug delivery in periodontitis treatment: A review of contemporary literature**

## Clinical cases

- 343 Anna Jodłowska, Jacek Pająk, Lidia Postek-Stefańska  
**Microdontia after chemotherapy in a patient treated for neuroblastoma: Histopathological findings**

## Spis treści

### Prace oryginalne

- 233 Tolga Genç, Onurcem Duruel, Hüseyin Burak Kutlu, Erhan Dursun, Erdem Karabulut, Tolga Fikret Tözüm  
**Ocena struktur anatomicznych i ich zmienności w szczęce oraz zuchwie przed leczeniem implantologicznym**
- 241 Asmaa Mohammad Alammari, Omar Ahmad Heshmeh  
**Repozycja wargi przez przecięcie przyczepów mięśni dźwigacza w leczeniu uśmiechu dziąsłowego**
- 247 Elham Fathy Mahmoud, Ola Moustafa Omar  
**Erozyjny i próchnicotwórczy potencjał wybranych płynnych leków pediatrycznych w odniesieniu do szkliwa zębów mlecznych – badanie w mikroskopii elektronowej**
- 255 Alma Y. Ceballos-Jiménez, Laura E. Rodríguez-Vilchis, Rosalía Contreras-Bulnes, Jesús Á. Arenas Alatorre, Ulises Velazquez-Enriquez, Maria M. García-Fabila  
**Odporność szkliwa na kwasy po zastosowaniu środków remineralizujących, lasera Er:YAG i ich połączenia**
- 261 Alper Özdoğan, Musa Şamil Akyl, Zeynep Yeşil Duymuş  
**Ocenianie mikroprzecieku pomiędzy zębiną a materiałami złożonymi**
- 267 Pezhman Hadadi, Farzane Ostovarrad, Ava Nikbin, Hadi Ranjzad, Farzane Ghasemi, Somayeh Nemati  
**Ocena poziomu szarości materiałów stomatologicznych w tomografii stożkowej – badanie przekrojowe**
- 275 Eshamsul Sulaiman, Nada Alarami, Yuh Ing Wong, Wen Hui Lee, Afaf Al-Haddad  
**Wpływ umiejscowienia wkładu z włókna szklanego na odporność na złamanie zębów przedtrzonowych szczęki, leczonych endodontycznie**
- 281 Aneta Furtak, Elżbieta Leszczyńska, Aleksandra Sender-Janeczek, Wojciech Bednarz  
**Powtarzalność i odtwarzalność pomiaru grubości dziąsła biometrem ultrasonograficznym**
- 289 Bartłomiej Górski, Tomasz Kaczyński, Andrzej Miskiewicz, Renata Górski  
**Wczesne gojenie pozabiegowe po sterowanej regeneracji tkanek u pacjentów z agresywnym zapaleniem przyzębia**
- 299 Tahmineh Razi, Sedigheh Razi  
**Związek pomiędzy morfologią i grubością części kostnych stawu skroniowo-zuchwowego a płcią, wiekiem oraz liczbą zachowanych zębów na postawie przekrojów tomografii stożkowej**
- 305 Vahid Molabashi, Masoud Abolvardi, Marzieh Akhlaghian, Mohammad Ibrahim Ghaffari  
**Percepcja atrakcyjności uśmiechu w zależności od wielkości korytarza policzkowego w różnych typach twarzy**
- 313 Renata Górski, Bartłomiej Górski  
**Samocena stanu jamy ustnej i nawyków związanych z opieką stomatologiczną dorosłych Polaków – badanie ankietowe**

### Prace poglądowe

- 321 Tuqa Rashad Raghis, Ghiath Mahmoud, Omar Hamadah  
**Skuteczność promieniowania laserowego w zapobieganiu demineralizacji szkliwa podczas leczenia ortodontycznego – systematyczny przegląd piśmiennictwa**
- 333 Małgorzata Szulc, Aneta Zakrzewska, Jacek Zborowski  
**Miejscowe dokieszonkowe podawanie leków w zapaleniu przyzębia – przegląd współczesnego piśmiennictwa**

## Prace kazuistyczne

- 343 Anna Jodłowska, Jacek Pająk, Lidia Postek-Stefańska  
**Mikrodoncja po chemioterapii u pacjenta leczonego z powodu nerwiaka zarodkowego – badania histopatologiczne**



# Evaluation of anatomical structures and variations in the maxilla and the mandible before dental implant treatment

## Ocena struktur anatomicznych i ich zmienności w szczęce oraz żuchwie przed leczeniem implantologicznym

Tolga Genç<sup>1,B</sup>, Onurcem Duruel<sup>1,D</sup>, Hüseyin Burak Kutlu<sup>1,B,E</sup>, Erhan Dursun<sup>1,B,E</sup>, Erdem Karabulut<sup>2,C</sup>, Tolga Fikret Tözüm<sup>3,A,C,E,F</sup>

<sup>1</sup> Department of Periodontology, Faculty of Dentistry, Hacettepe University, Ankara, Turkey

<sup>2</sup> Department of Biostatistics, Faculty of Medicine, Hacettepe University, Ankara, Turkey

<sup>3</sup> Department of Periodontics, College of Dentistry, University of Illinois at Chicago, Chicago, United States

A – research concept and design; B – collection and/or assembly of data; C – data analysis and interpretation;

D – writing the article; E – critical revision of the article; F – final approval of the article

Dental and Medical Problems, ISSN 1644-387X (print), ISSN 2300-9020 (online)

Dent Med Probl. 2018;55(3):233–240

### Address for correspondence

Tolga F. Tözüm

E-mail: ttozum@icloud.com

### Funding sources

None declared

### Conflict of interest

None declared

Received on May 18, 2018

Reviewed on July 24, 2018

Accepted on August 14, 2018

### DOI

10.17219/dmp/94303

### Copyright

© 2018 by Wrocław Medical University and Polish Dental Society

This is an article distributed under the terms of the Creative Commons Attribution Non-Commercial License (<http://creativecommons.org/licenses/by-nc-nd/4.0/>)

## Abstract

**Background.** Cone beam computed tomography (CBCT) allows a detailed visualization of the anatomic structures of the jaw. There have been presented variations of the anatomic structures between genders after evaluating the structures in detail.

**Objectives.** The aim of this study was to investigate the anatomic variations of the jaws according to gender and age in an effort to avoid complications during implant surgeries.

**Material and methods.** In this retrospective study, a total of 159 scans (87 of the maxilla, 72 of the mandible) were evaluated in order to analyze the effect of age and gender on these anatomic variations.

**Results.** According to statistical analysis, gender affected the crestal dimensions above the mandibular canal and sinus mucosal thickening. The mean value of the width of the mandibular canal, the distance between the mandibular canal and the superior border of the mandible, the distance between the mandibular canal and the inferior border of the mandible, the diameter of the mental foramen, the distance between the mental foramen and the inferior border of the mandible, and the distance between the lingual foramen and the inferior border of the mandible were significantly greater in female patients than in male subjects ( $p < 0.001$ ). However, sinus mucosal thickening and the diameter of the posterior superior alveolar artery (PSAA) were significantly greater in males as compared to females ( $p < 0.001$ ). While the configuration of the nasopalatine canal was funnel-shaped in female patients, this configuration was found to be cylinder-shaped in male subjects. A high prevalence of sinus septa (43.7%) and PSAA (87.4%) was detected in the scans.

**Conclusions.** When planning dental implants, radiographic examinations, alongside clinical examinations, have become necessary to reduce the risk of implant surgery failure and complications. The CBCT imaging is a valuable tool to determine the anatomic structures before carrying out any surgeries, including implant surgery. Gender affects anatomical variations and dimensions significantly, even when they are not affected by age. Large population focused and multicenter studies may provide a better understanding of the need to evaluate the anatomical structures in detail.

**Key words:** dental implant, mandible, maxilla, anatomy, cone beam computed tomography

**Słowa kluczowe:** implant stomatologiczny, żuchwa, szczęka, anatomia, stożkowa tomografia komputerowa

## Introduction

Edentulous patients live a life with some physical, emotional and psychological complaints, such as decreased chewing efficiency, decreased esthetic appearance and decreased self-confidence. One possible solution to this problem are teeth-supported fixed partial prostheses, overdentures and dental implant-supported prostheses.<sup>1</sup>

Dental implant placement is a routine and predictable technique, used to replace the missing teeth for esthetic, phonetic and biomechanical reasons. Sufficient bone quantity and quality are important for proper dental implant placement and for long-term satisfactory treatment outcome.<sup>2</sup> The alveolar ridge resorption and the maxillary sinus expansion are the main limiting factors that make reconstruction of the posterior maxilla more difficult. Apart from that, compromised bone height and width, as well as localization of the mental foramen and the mandibular canal are the main disadvantageous factors in the reconstruction of the mandible. It is important to know the anatomic features in these areas when performing surgeries (e.g., dental implant, sinus lifting procedures and bone augmentation).<sup>3,4</sup> Data about the anatomic structures and variations reduces the risk of complications, such as bleeding of the posterior superior alveolar artery (PSAA), sinus membrane perforation, neurosensory disturbance of the lower lip and chin, and lingual plate perforation.<sup>2,5</sup>

Dental implant site evaluation, oral and maxillofacial trauma, and orthodontics are some of the most frequent indications for cone beam computed tomography (CBCT). Cone beam computed tomography uses a cone or pyramid-shaped beam to obtain multiple projections in only 1 rotation.<sup>6</sup> The CBCT images allowed us to examine more precisely the location of the anatomic structures and provided information about bone morphology and sinus pathologies, which is of great importance for dental implant planning.<sup>2</sup> Although a few studies have examined the anatomic structures separately,<sup>2,7,8</sup> full-mouth radiological examinations have not been reported yet. Hence, the aim of this study was to examine the anatomic structures and variations according to gender and age in order to prevent complications, using the CBCT scans.

## Material and methods

A total of 159 CBCT scans (87 maxillae and 72 mandibles) from patients undergoing mandible and/or maxilla hard tissue augmentation surgeries and/or implant therapy in the Department of Periodontology at the Hacettepe University (Ankara, Turkey) were chosen for this retrospective clinical study. Only high-quality computerized images, axial sections with 1-millimeter intervals were included in the study, whereas low-quality images, such as scattering, and inferior or superior level of window

exposure, were excluded. The scans were evaluated by 1 calibrated investigator (T.G.). This retrospective study was reviewed and approved by Non-Interventional Clinical Research Ethics Board of the Hacettepe University (GO 14/279 – May 9, 14, 2014).

### Evaluation of the maxilla via the cone beam computed tomography scans

Fifty-four patients were female and 33 were male. The mean age was  $51.9 \pm 11.4$  years. All 87 CBCT scans were evaluated for the following items bilaterally: mesiodistal and buccopalatal dimensions of the maxillary sinus; prevalence of sinus septa  $>2.5$  mm; localization of sinus septa – anterior (mesial side of first molar), middle (between mesial border of first molar and distal border of second molar) and posterior (distal side of second molar)<sup>9</sup>; thickening of the Schneiderian membrane<sup>10</sup>; height and width of the posterior alveolar ridge; diameter and location of PSAA – intraosseous (type 1), below the membrane (type 2), on the outer cortex of the lateral sinus wall (type 3)<sup>2</sup>; diameter of the nasopalatine canal – crestal, medial, apical; length of the nasopalatine canal; and canal morphology of the nasopalatine canal – cylindrical, banana-like, hourglass-like, funnel-like.<sup>7</sup>

### Evaluation of the mandible via the cone beam computed tomography scans

Forty-two patients were female and 30 were male. The mean age was  $52.9 \pm 10.7$  years. All 72 CBCT scans were evaluated bilaterally. The selected landmarks were the following: vertical size of the mandibular canal; distance between the mandibular canal and the inferior border of the mandible; distance between the mandibular canal and the crest; localization of the mental foramen – mesial side of first premolar, between first premolar and second premolar, distal side of second premolar; diameter of the mental foramen; distance between the mental foramen and the inferior border of the mandible; distance between the mental foramen and the crest; prevalence of the anterior alveolar loop (aAL); size of the anterior loop – anteroposterior and caudal; location of the lingual foramen; diameter of the lingual foramen; vertical distance from the mandibular border; distance between the lingual foramen and the crest; vascular type of the lingual canal – mono, bifid and triple. They were measured according to protocol.<sup>8,11</sup>

### Statistical analyses

All statistical data was processed using SPSS v. 11.5 software for Windows (IBM, Chicago, USA). Using the Kolmogorov-Smirnov statistical analysis, it was determined that intermittent and continuous numeric variables did/did not present normal distribution. The homogeneity

of variance was tested by the Levene test. The mean and standard deviation were used for descriptive statistics in the case of intermittent and continuous numeric variables. Categorical variables were shown as the number of events and percentage.

Student's t-test was used to calculate the average of independent pairs; for more than 2 independent groups, one-way analysis of variance (ANOVA) was utilized. If one-way ANOVA results were statistically significant, the parameters causing the difference were determined by using post hoc Tukey's honest significant difference (HSD) test. Categorical variables were calculated using Pearson's  $\chi^2$ , likelihood ratio and Fischer's exact tests. The correlations between continuous and intermittent numeric variables were investigated using Pearson's correlation test. The comments and assessments were based on comparisons with a statistical significance of 0.05.

## Results

### Maxilla

No statistically significant difference was detected between the mean age of 33 male and 54 female patients ( $p = 0.202$ ) (Table 1). The presence of posterior teeth did not differ significantly according to gender ( $p = 0.396$ ). Similar results were observed for the presence of sinus septa in male subjects compared with female subjects ( $p = 0.110$ ). In presenting sinus septa subjects, the location of sinus septa did not differ significantly according to gender ( $p = 0.828$ ). Sinus membrane thickening in male patients was observed more often than in female patients ( $p = 0.008$ ). However, there was no significant difference between the types of sinus membrane thickening in both genders ( $p = 0.174$ ). The presence of PSAA was not significantly different between genders ( $p = 0.195$ ). In presenting PSAA subjects, the localization of PSAA was similar in genders ( $p = 0.416$ ). In male subjects, the diameters of PSAA were mostly wider than 1 mm. However, they were 1 mm in female subjects ( $p = 0.035$ ).

The canal morphology of the nasopalatine canal differed between genders significantly ( $p = 0.043$ ). A cylindrical canal shape (60.6%) was the most prevalent shape in male subjects, whereas a funnel-like shape (46.3%) was the most prevalent in female patients. The mesiodistal and buccopalatal dimensions of the sinus, the height and width of the posterior alveolar ridge, the diameter of the nasopalatine canal (apical), and the length of the nasopalatine canal were not significantly different in genders ( $p > 0.05$ ). Although the diameter of the nasopalatine canal (middle:  $p = 0.003$ ; crestal:  $p = 0.009$ ) was significantly wider in male patients than in female patients, no significant correlation between age and the radiological measurements were observed ( $p > 0.05$ ).

Table 1. Demographic and clinical parameters of patients according to gender with regard to the maxilla

Parameters	Males (n = 33)	Females (n = 54)	p-value
Age [years]	53.9 ±10.3	50.7 ±11.9	0.202
Presence/absence of posterior teeth			0.396
none	12 (36.4)	15 (27.8)	
several	19 (57.6)	31 (57.4)	
dentate	2 (6.1)	8 (14.8)	
Presence of septa	18 (54.5)	20 (37.0)	0.110
Localization of septa			0.828
anterior	1 (5.6)	2 (10.0)	
middle	14 (77.8)	14 (70.0)	
posterior	3 (16.7)	4 (20.0)	
Sinus membrane thickening	31 (93.9)	38 (70.4)	0.008*
Classification of membrane thickening			0.174
flat	8 (25.8)	19 (50.0)	
hemispheric	10 (32.3)	9 (23.7)	
mucosal-like	7 (22.6)	7 (18.4)	
mixed	6 (19.4)	3 (7.9)	
Visualization of PSAA	31 (93.9)	45 (83.3)	0.195
Localization of PSAA			0.416
below the membrane	12 (38.7)	23 (51.1)	
intraosseous	15 (48.4)	15 (33.3)	
on the outer cortex of the lateral sinus wall	4 (12.9)	7 (15.6)	
Width of PSAA			0.035*
<1 mm	9 (29.0)	21 (46.7)	
1 mm	9 (29.0)	17 (37.8)	
>1 mm	13 (41.9)	7 (15.6)	
Canal morphology of the nasopalatine canal			0.043*
cylindrical	20 (60.6)	20 (37.0)	
banana-like	1 (3.0)	–	
hourglass-like	5 (15.2)	9 (16.7)	
funnel-like	7 (21.2)	25 (46.3)	

Data presented as mean ± standard deviation (SD) or as number (percentage). PSAA – posterior superior alveolar artery; \* statistically significant ( $p < 0.05$ ).

With regard to the mean value of age, male and female subjects edentulous in the posterior regions were expectedly older than dentate men and women ( $p = 0.019$ ). The presence of sinus septa ( $p = 0.061$ ) and the location of sinus septa ( $p = 0.946$ ) did not differ significantly for the mean value of age. The mean value of age was found similar between the presence and absence of sinus membrane thickening ( $p = 0.446$ ). Furthermore, there was no significant difference between the types of sinus membrane thickening for the mean value of age ( $p = 0.303$ ). No significant difference for the mean value of age was observed between the presence and absence of PSAA ( $p = 0.605$ ).

The localization of PSAA ( $p = 0.428$ ) and the diameter of PSAA ( $p = 0.065$ ) did not differ significantly for the mean value of age. The canal morphology of the nasopalatine canal did not differ significantly for the mean value of age ( $p = 0.419$ ).

The average buccopalatal dimensions of the sinus between the groups were similar with regard to the presence of posterior teeth. The mean value of mesiodistal dimensions of the sinus was similar ( $p = 0.713$ ). There was no statistically significant difference between the groups in terms of sinus membrane thickening ( $p = 0.346$ ). However, the classification of membrane thickening, in the groups where sinus membrane thickening was detected, showed a statistically significant difference depending on the presence of posterior teeth ( $p = 0.029$ ). Compared with posterior edentulous jaws, flat sinus membrane thickening was found statically significantly frequently ( $p = 0.049$ ), whereas semi-aspherical sinus membrane thickening was observed rarely ( $p = 0.035$ ) (Table 2).

## Mandible

No statistically significant difference was detected between the mean age of 30 male and 42 female patients ( $p = 0.317$ ) (Table 3). The distribution of the presence of posterior teeth did not differ significantly according to gender ( $p = 0.798$ ). The mental foramen localization in terms of gender distribution was statistically similar ( $p = 1.000$ ). There was no statistically significant difference between men and women in relation to the loop presence ( $p = 0.265$ ). There was no statistically significant gender difference in terms of the presence of the lingual foramen groups ( $p = 0.643$ ). The lingual foramen localizations, in the cases determined by the distribution of men and women, were statistically similar ( $p = 0.679$ ). There was no statistically significant difference in terms of the lingual canal branching between genders ( $p = 0.606$ ). The distribution of the lingual foramen width was statistically similar between men and women ( $p = 0.701$ ).

**Table 3.** Demographic and clinical parameters of patients according to gender with regard to the mandible

Parameters	Males (n = 30)	Females (n = 42)	p-value
Age [years]	54.4 ± 9.5	51.8 ± 11.5	0.317
Presence/absence of posterior teeth			0.798
none	11 (36.7)	13 (31.0)	
several	17 (56.7)	27 (64.3)	
dentate	2 (6.7)	2 (4.8)	
Localization of the mental foramen			1.000
between first premolar and second premolar	26 (86.7)	36 (85.7)	
distal side of second premolar	4 (13.3)	6 (14.3)	
Prevalence of aAL	5 (16.7)	3 (7.1)	0.265
Visualization of the lingual foramen	27 (90.0)	40 (95.2)	0.643
Localization of the lingual foramen			0.679
middle	24 (88.9)	37 (92.5)	
lateral sides	3 (11.1)	3 (7.5)	
Vascular type of the lingual canal			0.606
mono	14 (51.9)	21 (52.5)	
bifid	9 (33.3)	16 (40.0)	
triple	4 (14.8)	3 (7.5)	
Diameter of the lingual foramen			0.701
<1 mm	17 (63.0)	27 (67.5)	
≥1 mm	10 (37.0)	13 (32.5)	

Data presented as mean ± standard deviation (SD) or as number (percentage). PSAA – posterior superior alveolar artery; aAL – anterior alveolar loop; \* statistically significant ( $p < 0.05$ ).

The mean value of the width of the mandibular canal, the distance between the mandibular canal and the crest, the distance between the mandibular canal and the inferior border of the mandible, the diameter of the mental foramen, the distance between the mental foramen and the inferior border of the mandible, and the distance between the lingual foramen and the inferior border of the mandible measurements were significantly higher in male

**Table 2.** Clinical measurements of cases according to gender with regard to the maxilla

Clinical measurements	Males			Females			p-value
	n	mean	SD	n	mean	SD	
Buccopalatal dimensions of the sinus [mm]	33	12.51	2.12	54	12.69	1.90	0.671
Mesiodistal dimensions of the sinus [mm]	33	18.02	2.87	54	17.55	2.52	0.427
Height of the posterior alveolar ridge [mm]	33	8.02	3.31	54	9.61	3.84	0.051
Width of the posterior alveolar ridge [mm]	33	7.76	2.22	54	7.51	1.97	0.588
Diameter of the nasopalatine canal (apical) [mm]	33	2.53	1.19	54	1.86	1.11	0.009*
Diameter of the nasopalatine canal (middle) [mm]	33	2.27	1.03	54	1.64	0.86	0.003*
Diameter of the nasopalatine canal (crestal) [mm]	33	3.23	1.04	54	3.51	1.61	0.372
Length of the nasopalatine canal [mm]	33	11.35	2.96	54	10.83	2.22	0.358

SD – standard deviation; \* statistically significant ( $p < 0.05$ ).

subjects than in females ( $p < 0.05$ ). However, the distance between the mental foramen and the crest, and the mean value of the distance between the lingual foramen and the inferior border of the mandible were statistically similar ( $p > 0.05$ ). Statistical comparisons of the anteroposterior and caudal length of the loop could not be made due to an insufficient number of evaluations. There was no statistically significant correlation between age and all the clinical measurements in all cases ( $p > 0.05$ ). The mean age of patients edentulous in the posterior region was higher than in the case of dentate patients. Hence, the presence of posterior teeth in relation to age indicates significant differences ( $p = 0.012$ ). There was no statistically significant difference in the mean age in relation to the mental foramen localization ( $p = 0.208$ ). No statistical difference was observed between the mean age of subgroups depending on the presence/absence of aAL ( $p = 0.796$ ).

The difference between the mean age of subjects based on the visualized/non-visualized lingual foramen was not significant ( $p = 0.678$ ). In subjects presenting the lingual foramen, there was no statistically significant difference between the groups in terms of the lingual foramen localization ( $p = 0.790$ ). There was no statistically significant difference in terms of the lingual canal branching with regard to the mean age of groups ( $p = 0.927$ ). The width of the lingual foramen did not differ significantly for the mean value of age ( $p = 0.400$ ). The mean value of distance between the lingual foramen and the crest of dentate patients was significantly greater than in edentulous patients ( $p < 0.001$ ). According to the presence of posterior teeth, the mean value of the distance between the lingual foramen and the inferior border of the mandible was statistically similar ( $p = 0.388$ ) (Table 4).

## Discussion

Having knowledge about the anatomic features in surgical areas while performing surgeries is important for treatment success.<sup>3,4</sup> Data about the anatomic structures and variations reduces the risk of such complications

as neurosensory disturbance, lingual plate perforation, etc.<sup>2,5</sup> Cone beam computed tomography is preferred for dental implant site evaluation.<sup>12</sup> Cone beam computed tomography uses a cone or pyramid-shaped beam to obtain multiple projections in only a single 360° rotation. In this study, the CBCT scans from the upper and lower jaws were examined. Using all the data and calculated rates of anatomic variations, comparisons based on gender and correlation analysis between age and the measurements were performed. For maxillary evaluation studies, the percentage of membrane thickening was 79.3% and membrane thickening in men had a significantly higher incidence than in females. There was no significant correlation between membrane thickening and age. Membrane thickening was most often classified as a flat-shaped thickening (39.1%), and when membrane thickening was evaluated in terms of gender classification, there was no significant difference between the groups. Schneider et al. reported that the membrane thickening ratio was 64.49% and flat-shaped thickening was observed in 45.65% of the subjects.<sup>13</sup> In the same study, there was no significant correlation between membrane thickening and age, and it was reported that the presence of membrane thickening was greater in male subjects.<sup>13</sup> Bornstein et al. reported that the presence of teeth with apical sinus pathology increases the presence of membrane thickening and the risk of sinusitis.<sup>14</sup> In our study, membrane thickening rates in both genders were similar to those reported in the literature. Furthermore, the ratio of detecting membrane thickening in male subjects was higher than in females.

The presence of sinus septa in this study was calculated at 43.7% in all subjects, and sinus septa in the central region (between distal sides of second premolar and second molar) was observed in 73.7% of patients. No relation was found between the presence of sinus septa and gender and/or age. Underwood reported that the presence and location of sinus septa were most often observed (66.7%) in the posterior region (distal side of tooth number 7).<sup>15</sup> Kim et al. stated that the presence of sinus septa was reported in 38% of the patients and the location of septa was most often observed in the central region.<sup>16</sup> The

**Table 4.** Clinical measurements of cases according to gender with regard to the mandible

Clinical measurements	Males			Females			p-value
	n	mean	SD	n	mean	SD	
Vertical size of the mandibular canal [mm]	30	2.71	0.52	42	2.34	0.50	0.003*
Distance between the mandibular canal and the crest [mm]	30	12.46	3.17	42	10.69	3.67	0.037*
Distance between the mandibular canal and the inferior border of the mandible [mm]	30	8.05	1.51	42	7.11	1.14	0.004*
Diameter of the mental foramen [mm]	30	3.27	0.78	42	2.87	0.64	0.022*
Distance between the mental foramen and the crest [mm]	30	9.85	3.08	42	8.60	3.43	0.117
Distance between the mental foramen and the inferior border of mandible [mm]	30	12.13	2.01	42	10.87	1.71	0.005*
Distance between the lingual foramen and the crest [mm]	27	14.70	4.81	40	12.54	3.89	0.046*
Distance between the lingual foramen and the mandibular border [mm]	27	12.31	3.37	40	10.93	3.44	0.106

SD – standard deviation; \* statistically significant ( $p < 0.05$ ).

literature about the presence and localization of sinus septa presents various results. The presence of septa has not been associated with age and gender, as in our study. Although the relation between the status of dentation and septa prevalence was not evaluated in the present study, the literature reveals that the presence of sinus septa is detected more frequently in totally edentulous subjects rather than in dentate subjects.<sup>9</sup>

The presence of PSAA was found in 87.4% of subjects. The posterior superior alveolar artery was often observed in the inner surface of the lateral wall of the sinus (46.1%). In addition, the width of PSAA was <1 mm with a ratio of 39.5%. Age and gender did not have a significant effect on the PSAA presence. The width of PSAA was greater in male subjects than in females. Güncü et al. reported that the visualization of PSAA was 64.5% in 242 CBCT scans<sup>2</sup>; however, Mardinger et al. reported 55%.<sup>17</sup> The latter authors reported a significant positive correlation between age and the width of PSAA, and found no relation between gender and the width of PSAA.<sup>17</sup> Güncü et al. noted that age did not have a significant effect on the visualization of PSAA and reported that there was a positive correlation between age and the PSAA width.<sup>2</sup>

A cylindrical canal shape was often observed in the present study (46%). A cylindrical canal shape was the most prevalent in male patients (60.6%), whereas a funnel-like canal was identified mostly in females (46.3%). No correlation between age and the shape of the nasopalatine canal was found. The mean value of the length of the nasopalatine canal was  $11.03 \pm 2.52$  mm. It was concluded that age and gender had no effect on the length of the nasopalatine canal. The mean values of the diameter of the nasopalatine canal were  $2.11 \pm 1.18$  mm (apical),  $1.88 \pm 0.97$  mm (middle) and  $3.4 \pm 1.42$  mm (crestal). There was no correlation between age and the diameter of the nasopalatine canal, whereas it was noted that gender affects the diameter of the nasopalatine canal. The diameter of the nasopalatine canal was greater in male subjects than in females in apical and middle regions. Tözüm et al. reported that a cylindrical canal shape was the most prevalent canal morphology in both genders.<sup>7</sup> Bornstein et al. determined the mean value of the length of the nasopalatine canal as 10.99 mm,<sup>18</sup> whereas Tözüm et al. noted 10.86 mm.<sup>7</sup> These results are similar to those of our study. They also measured the mean value of the apical region of the nasopalatine canal as  $2.76 \pm 1.4$  mm and the mean value of the crestal region of the nasopalatine canal was  $2.93 \pm 1.01$  mm. However, they reported that age and gender had no effect on these measurements, which is in line with the present study. According to these papers, the anatomic structures should be measured carefully by using the CBCT scans when planning implant surgery.<sup>7</sup>

The height of the residual alveolar ridge of the posterior maxilla is important for implant planning and advanced surgery (internal sinus lifting or lateral approach

technique). In this study, measurements were taken from the first premolar and the first and second molar regions, respectively. The average of these measurements was  $9.01 \pm 3.71$  mm. There was no difference between male and female subjects. Shanbhag et al. calculated the average value of the height of the residual alveolar ridge of the posterior maxilla as  $6.39 \pm 3.52$  mm. A negative correlation was found between age and the height of the residual alveolar ridge, in accordance with the results of our study.<sup>19</sup>

In the present study, the localization of the mental foramen was observed between the first and second premolar regions in 86.1%. Age and gender did not affect the localization of the mental foramen as expected. Von Arx et al. and Kalender et al. found that the localization of the mental foramen between the first and second premolar region was higher than in other regions, i.e., 56% and 59.8%, respectively.<sup>11,20</sup> Kalender et al. reported that gender did not have any effect on the localization of the mental foramen, which is in line with the results of the present study.<sup>20</sup> In this study, the average diameter of the mental foramen was  $3.04 \pm 0.73$  mm and was significantly greater in male than in female subjects. Von Arx et al. and Kalender et al. measured the mean value of the diameter of the mental foramen with the results of 3.1 and 3.55 mm, respectively.<sup>11,20</sup> They both reported that the diameter of the mental foramen was greater in males than in females, which is in line with the results of the present study.<sup>11,20</sup> The mean values of the distance between the mental foramen and the inferior border of the mandible, and the distance between the mental foramen and the crest were  $11.4 \pm 1.93$  mm and  $9.12 \pm 3.32$  mm, respectively. No correlation was found between these measurements and age. The distance between the mental foramen and the inferior border of the mandible was smaller in female subjects than in male subjects. Haktanır et al. reported that gender was not correlated with the distance between the mental foramen and the inferior border of the mandible.<sup>21</sup> However, Kalender et al. reported that gender had an effect on the distance between the mental foramen and the inferior border of the mandible, which is in line with the results of this study.<sup>20</sup>

The presence of aAL was 11.1% in this study. Age and gender did not affect the presence of aAL. The anterior length and caudal height of aAL were  $5.34 \pm 1.13$  mm and  $7.16 \pm 4.11$  mm, respectively. In the literature, various data about the presence of aAL has been found. In cadaver studies, the presence of aAL was found to be between 0 and 88%.<sup>22</sup> In the CT scans, the presence of aAL was found to be 7–83%,<sup>23,24</sup> although the presence of aAL was determined to be 48–84% in the CBCT scans.<sup>24,25</sup> In the literature, the results of papers on the aAL size have shown variability. The size of aAL was 1.5–5 mm in cadaver studies.<sup>26</sup> In addition, the size of aAL was 2.09–5.3 mm in the CT scans and the maximum size of aAL was determined as 5.7 mm.<sup>27</sup> In the CBCT scans, the size of aAL was between 0.89 mm and

3.54 mm, and the maximum size of aAL was 5.7 mm.<sup>11</sup> These various measurements in the literature might be the result of different measurement techniques and different reference points; therefore, the results of the present study must be evaluated accurately.

In the present study, the lingual foramen was detected in 93.1% of the CBCT scans. The most prevalent vascular type of the lingual canal was monovascular, in 52.2% of the cases. The mean value of the distance between the lingual foramen and the crest was  $13.41 \pm 4.38$  mm. Yıldırım et al. measured the distance between the lingual foramen and the crest, and their result was different from that of the present study.<sup>8</sup> This might be the result of different measurement techniques and anatomic variations of the population. Detecting the lingual canal by using 3-dimensional (3D) imaging techniques should be essential during implant planning. In this study, the diameter of the lingual foramen classified 2 groups as  $\leq 1$  mm and  $> 1$  mm. The diameter of the lingual foramen  $\leq 1$  mm was found in 65.7% of subjects. Age and gender did not have an effect on the diameter of the lingual foramen. Yıldırım et al. reported that the diameter of the lingual foramen  $\leq 1$  mm was found in 75.6% of the patients.<sup>8</sup>

In the present study, the mean value of the vertical size of the mandibular canal was  $2.49 \pm 0.54$  mm. The average distance between the mandibular canal and the crest was  $11.43 \pm 3.55$  mm. The mean value of the distance between the mandibular canal and the inferior border of the mandible was  $7.5 \pm 1.38$  mm. These measurements were greater in male subjects than in females. In dentate subjects, the distance between the mandibular canal and the crest was greater than in edentulous subjects.

Hsu et al. found that the mean value of the vertical size of the mandibular canal was  $2.16 \pm 0.44$  mm,<sup>26</sup> whereas Al-Siweedi et al. calculated it as  $2.27 \pm 0.39$  mm,<sup>28</sup> Levine et al. reported that the average distance between the mandibular canal and the crest was  $13.18 \text{ mm} \pm 3.7$ .<sup>29</sup> Kilic et al. reported that the mean value of the distance between the mandibular canal and the inferior border of the mandible was  $10.09 \pm 3.69$  mm.<sup>30</sup> These various results might be explained by different measurement techniques and different reference points. 3-dimensional imaging techniques should be preferred to reduce the risk of complications, such as neurosensory disturbance, before implant surgeries are carried out in the posterior mandible region.

## Conclusions

When planning dental implants, carrying out radiographic examinations, alongside clinical examinations, has become necessary to reduce the risk of implant surgery failure and complications. The CBCT imaging is a valuable tool to determine the anatomic structures before any surgery, including implant surgery. Gender

affects anatomical variations and dimensions significantly, although they are not affected by age. Dimensions of the anatomic structures (i.e., diameter of PSAA, diameter of the nasopalatine canal, dimensions of the mandibular) were found to be greater in male subjects. In addition, a cylindrical canal shape is most frequently found in male subjects, whereas females tend to have a funnel-like shape. Large population focused and multicenter studies may provide a better understanding of the need to evaluate the anatomical structures in detail.

## References

- Asawa N, Bulbule N, Kakade D, Shah R. Angulated implants: An alternative to bone augmentation and sinus lift procedure: Systematic review. *J Clin Diagn Res.* 2015;9(3):ZE10–13.
- Güncü GN, Yıldırım YD, Wang HL, Tözüm TF. Location of posterior superior alveolar artery and evaluation of maxillary sinus anatomy with computerized tomography: A clinical study. *Clin Oral Implants Res.* 2011;22(10):1164–1167.
- Jensen OT, Shulman LB, Block MS, Iacono VJ. Report of the sinus consensus conference of 1996. *Int J Oral Maxillofac Implants.* 1998;13(Suppl):11–45.
- Leite GM, Lana JP, de Carvalho Machado V, Manzi FR, Souza PE, Horta MC. Anatomic variations and lesions of the mandibular canal detected by cone beam computed tomography. *Surg Radiol Anat.* 2014;36(8):795–804.
- Misch C, Crawford E. Predictable mandibular nerve location: A clinical zone of safety. *Int J Oral Implantol.* 1990;7(1):37–40.
- Koong B. Cone beam imaging: Is this the ultimate imaging modality? *Clin Oral Implants Res.* 2010;21(11):1201–1208.
- Tözüm TF, Güncü GN, Yıldırım YD, et al. Evaluation of maxillary incisive canal characteristics related to dental implant treatment with computerized tomography: A clinical multicenter study. *J Periodontol.* 2012;83(3):337–343.
- Yıldırım YD, Güncü GN, Galindo-Moreno P, et al. Evaluation of mandibular lingual foramina related to dental implant treatment with computerized tomography: A multicenter clinical study. *Implant Dent.* 2014;23(1):57–63.
- Krennmaier G, Ulm CW, Lugmayr H, Solar P. The incidence, location, and height of maxillary sinus septa in the edentulous and dentate maxilla. *J Oral Maxillofac Surg.* 1999;57(6):667–672.
- Soikkonen K, Ainamo A. Radiographic maxillary sinus findings in the elderly. *Oral Surg Oral Med Oral Pathol Oral Radiol Endod.* 1995;80(4):487–491.
- Von Arx T, Friedli M, Sendi P, Lozanoff S, Bornstein MM. Location and dimensions of the mental foramen: A radiographic analysis by using cone-beam computed tomography. *J Endod.* 2013;39(12):1522–1528.
- Ritter L, Lutz J, Neugebauer J, et al. Prevalence of pathologic findings in the maxillary sinus in cone-beam computerized tomography. *Oral Surg Oral Med Oral Pathol Oral Radiol Endod.* 2011;111(5):634–640.
- Schneider AC, Bragger U, Sendi P, Caversaccio MD, Buser D, Bornstein MM. Characteristics and dimensions of the sinus membrane in patients referred for single-implant treatment in the posterior maxilla: A cone beam computed tomographic analysis. *Int J Oral Maxillofac Implants.* 2013;28(2):587–596.
- Bornstein MM, Wasmer J, Sendi P, Janner SFM, Buser D, von Arx T. Characteristics and dimensions of the Schneiderian membrane and apical bone in maxillary molars referred for apical surgery: A comparative radiographic analysis using limited cone beam computed tomography. *J Endod.* 2012;38(1):51–57.
- Underwood AS. An inquiry into the anatomy and pathology of the maxillary sinus. *J Anat Physiol.* 1910;44(Pt 4):354–369.
- Kim MJ, Jung UW, Kim CS, et al. Maxillary sinus septa: Prevalence, height, location, and morphology. A reformatted computed tomography scan analysis. *J Periodontol.* 2006;77:903–908.
- Mardinger O, Abba M, Hirschberg A, Schwartz-Arad D. Prevalence, diameter and course of the maxillary intraosseous vascular canal with relation to sinus augmentation procedure: A radiographic study. *Int J Oral Maxillofac Surg.* 2007;36:735–738.

18. Bornstein MM, Balsiger R, Sendi P, von Arx T. Morphology of the nasopalatine canal and dental implant surgery: A radiographic analysis of 100 consecutive patients using limited cone-beam computed tomography. *Clin Oral Implants Res.* 2011;22:295–301.
19. Shanbhag S, Karnik P, Shirke P, Shanbhag V. Cone-beam computed tomographic analysis of sinus membrane thickness, ostium patency, and residual ridge heights in the posterior maxilla: Implications for sinus floor elevation. *Clin Oral Implants Res.* 2014;25:755–760.
20. Kalender A, Orhan K, Aksoy U. Evaluation of the mental foramen and accessory mental foramen in Turkish patients using cone-beam computed tomography images reconstructed from a volumetric rendering program. *Clin Anat.* 2012;25(5):584–592.
21. Haktanir A, Ilgaz K, Turhan-Haktanir N. Evaluation of mental foramina in adult living crania with MDCT. *Surg Radiol Anat.* 2010;32(4):351–356.
22. Neiva RF, Gapski R, Wang HL. Morphometric analysis of implant-related anatomy in Caucasian skulls. *J Periodontol.* 2004;75(8):1061–1067.
23. Li X, Jin ZK, Zhao H, Yang K, Duan JM, Wang WJ. The prevalence, length and position of the anterior loop of the inferior alveolar nerve in Chinese, assessed by spiral computed tomography. *Surg Radiol Anat.* 2013;35(9):823–830.
24. Jacobs R, Mraiwa N, vanSteenberghe D, Gijbels F, Quirynen M. Appearance, location, course, and morphology of the mandibular incisive canal: An assessment on spiral CT scan. *Dentomaxillofac Radiol.* 2002;31(5):322–327.
25. Parnia F, Moslehifard E, Hafezeqoran A, Mahboub F, Mojaver-Kahn-amoui H. Characteristics of anatomical landmarks in the mandibular interforaminal region: A cone-beam computed tomography study. *Med Oral Patol Oral Cir Bucal.* 2012;17(3):e420–425.
26. Hsu JT, Huang HL, Fuh LJ, et al. Location of the mandibular canal and thickness of the occlusal cortical bone at dental implant sites in the lower second premolar and first molar. *Comput Math Methods Med.* 2013;2013:608570.
27. Apostolakis D, Brown JE. The anterior loop of the inferior alveolar nerve: Prevalence, measurement of its length and a recommendation for interforaminal implant installation based on cone beam CT imaging. *Clin Oral Implants Res.* 2012;23(9):1022–1030.
28. Al-Siweedi SY, Nambiar P, Shanmugasantharam P, Ngeow WC. Gaining surgical access for repositioning the inferior alveolar neurovascular bundle. *Sci World J.* 2014;2014:719243.
29. Levine MH, Goddard AL, Dodson TB. Inferior alveolar nerve canal position: A clinical and radiographic study. *J Oral Maxillofac Surg.* 2007;65(3):470–474.
30. Kilic C, Kamburoglu K, Ozen T, et al. The position of the mandibular canal and histologic feature of the inferior alveolar nerve. *Clin Anat.* 2010;23(1):34–42



# Lip repositioning with a myotomy of the elevator muscles for the management of a gummy smile

## Repozycja wargi przez przecięcie przyczepów mięśni dźwigacza w leczeniu uśmiechu dziąsłowego

Asmaa Mohammad Alammari<sup>1,D</sup>, Omar Ahmad Heshmeh<sup>2,D</sup>

<sup>1</sup> Faculty of Dentistry, Damascus University, Syria

<sup>2</sup> Department of Oral and Maxillofacial Surgery, Faculty of Dentistry, Damascus University, Syria

A – research concept and design; B – collection and/or assembly of data; C – data analysis and interpretation; D – writing the article; E – critical revision of the article; F – final approval of the article

Dental and Medical Problems, ISSN 1644-387X (print), ISSN 2300-9020 (online)

Dent Med Probl. 2018;55(3):241–246

### Address for correspondence

Asmaa Alammari  
E-mail: asma.alammari90@gmail.com

### Funding sources

None declared

### Conflict of interest

None declared

Received on April 16, 2018  
Reviewed on May 19, 2018  
Accepted on June 15, 2018

### DOI

10.17219/dmp/92317

### Copyright

© 2018 by Wrocław Medical University  
and Polish Dental Society  
This is an article distributed under the terms of the  
Creative Commons Attribution Non-Commercial License  
(<http://creativecommons.org/licenses/by-nc-nd/4.0/>)

## Abstract

**Background.** Excessive gingival display  $\geq 4$  mm is commonly referred to as a “gummy smile”, which is caused by several different etiologies and can be corrected using various techniques. Therefore, the etiology of a gummy smile dictates the most appropriate treatment approach.

**Objectives.** The aim of this study was to evaluate the surgical lip repositioning technique (a full-thickness flap with a myotomy of the elevator muscles) in the management of a gummy smile in the range of 4–6 mm, caused by soft tissue disorders (short upper lip, hyperactive lip elevator muscles).

**Material and methods.** A prospective study was conducted between April 2016 and May 2017. Fourteen adult patients, aged 18–38 years, with a gummy smile of 4–6 mm, caused by soft tissue disorders were included in the study. All patients were treated by the surgical lip repositioning technique (a full-thickness flap with a myotomy of the elevator muscles) in the Department of Oral and Maxillofacial Surgery at Damascus University, Syria. The amount of gingival display in a full smile and complications after surgery were evaluated in the current study.

**Results.** The results were as follows: the mean amount of gingival display in a full smile was 6.36 mm preoperatively, after 1 month postoperatively – 0.91 mm, after 3 months – 2.27 mm, after 6 months – 2.45 mm. The post-surgery complications were as follows: the infection did not appear in any patient, flap dehiscence appeared in 2 patients (14.2%), numbness appeared in 9 patients (64.2%). Pain recurrences varied between mild pain in 5 patients (35.7%) and moderate pain in 3 patients (21.4%).

**Conclusions.** The proposed surgical lip repositioning technique showed effectiveness in reducing the amount of gingival display in a full smile through postoperative follow-up periods. All the postoperative complications are temporary and fade within a short period after the surgical procedure, making lip repositioning a safe surgical technique.

**Key words:** gingival display, gummy smile, lip repositioning, myotomy of elevator muscles

**Słowa kluczowe:** ekspozycja dziąseł, uśmiech dziąsłowy, repozycja wargi, przecięcie przyczepów mięśni dźwigacza

## Introduction

An attractive, esthetic smile is one of the basic demands for most people all over the world.<sup>1</sup> The ideal smile is a result of the harmonious interaction between 3 important components: the lip, teeth and gingiva. Normal gingival display in a full smile is about 1–3 mm between the lower border of the upper lip and the marginal gingiva of anterior superior incisors.<sup>2</sup> On the other hand, abnormal gingival display reaching 4 mm or more is commonly referred to as a “gummy smile”, and it is classified as an unattractive smile by dentists and people.<sup>2,3</sup> The percentage of men and women with a gummy smile amounts to approx. 7% and 14%, respectively.<sup>4</sup> There are several different etiologies that can cause a gummy smile, such as vertical maxillary excess (skeletal factors), passive delayed eruption or compensatory eruption of maxillary teeth, especially in class 2 malocclusion (dentoalveolar factors),<sup>1,5,6</sup> short upper lip or hyperactive lip elevator muscles, which are known as soft tissue factors,<sup>7,8</sup> in addition to genetic factors, which can also play a role in causing a gummy smile.<sup>9</sup> According to the above-mentioned etiologies, a gummy smile can be treated by using several techniques, such as orthodontic surgery, gingivectomy or surgical crown lengthening, botox injection, myotomy of the lip elevator muscles, and surgical lip repositioning. Sometimes, a gummy smile can be caused by multiple etiologies and requires a multi-dimensional approach.<sup>1,3</sup> That is why the underlying etiology of a gummy smile dictates the most appropriate treatment approach.<sup>10,11</sup>

Lip repositioning is an innovative surgical technique for correcting a gummy smile. It was first reported in 1973 by Rubinstein and Kostianovsky, who performed it by removing a strip of the labial mucosa, involving the upper lip frenum, apical to the mucogingival junction.<sup>acc.12</sup> Since then, the procedure has undergone many different alterations. In 1979, as a modification of the original lip repositioning, the midline maxillary labial frenum was not recommended to be excised to facilitate maintaining the position of the labial midline.<sup>acc.1</sup> In 1983, Miskinyar performed lip repositioning with a myotomy of the upper lip elevator muscles, which was again endorsed by Litton and Fournier by using the same technique in cases with short upper lip.<sup>acc.6,13</sup> In 2010, Ishida et al. reported cases treated with a myotomy of the lip elevator muscles and a frenectomy.<sup>14</sup> Furthermore, Ellenbogen and Swara supported the method of inserting a spacer in 2 schemes: nasal cartilage or prosthesis between the stumps.<sup>15</sup> This last method was to prevent the reunion of the muscles and re-elevation of the lip. Rees and Latrenta described a camouflage procedure through the columella, by performing a subperiosteal dissection of the upper lip elevator muscles.<sup>acc.14</sup> According to the medical literature

on surgical lip repositioning, there are some contraindications in the following cases<sup>4,5</sup>:

- patients with inadequately attached gingiva (<3 mm) in the maxillary anterior sextant, which can create difficulties in the flap design, stabilization and suturing;
- patients with a gummy smile caused by skeletal factors, such as vertical maxillary excess (gingival display in a smile >6 mm) (such patients should be treated with orthognathic surgery);
- uncontrolled systemic disease patients and smokers.

Reports in the literature have shown some postoperative complications, such as discomfort, bruising and swelling of the upper lip. A less frequent complication may be the formation of mucocele due to severed minor salivary glands in the upper lip, which resolves on its own and relapses postoperatively. Other rare complications that have been reported in the literature are paresthesia and transient paralysis.<sup>4,12</sup> However, it appears that medical literature lacks systematic clinical studies on the different techniques of surgical lip repositioning. There are no previous studies concerning our modified technique, which is a full-thickness flap (V-shaped in the upper lip frenum) with a myotomy of the elevator muscles for lip repositioning in the management of a gummy smile.

Our research aimed at evaluating the modified lip repositioning technique (a full-thickness flap with a myotomy of the elevator muscles) in the management of a gummy smile ranging from 4 to 6 mm, caused by soft tissue disorders (short upper lip, hyperactive lip elevator muscles), as well as postoperative complications.

## Material and methods

The study sample included 14 adult patients aged 18–38 years, diagnosed with a gummy smile ranging between 4 and 6 mm, caused by soft tissue disorders (short upper lip, hyperactive lip elevator muscles), referred to the Department of Oral and Maxillofacial Surgery at the Faculty of Dentistry, Damascus University, Syria, between April 2016 and May 2017. These patients were treated using a surgical lip repositioning technique (a full-thickness flap with a myotomy of the lip elevator muscles).

Inclusion criteria were as follows: 18–38 years of age, safety of gingival health and good oral health, good general health or a controlled systemic disease, and a gummy smile ranging from 4 to 6 mm, caused only by short upper lip and hyperactive lip elevator muscles (lip mobility >8 mm).

Exclusion criteria comprised: smoking, pregnancy or lactation, insufficient amount of attached gingiva (<3 mm), vertical maxillary excess (gingival display in a smile >6 mm), and a systemic disease considered a contraindication for a surgical procedure under local anesthesia.

Informed consent was signed by each of the subjects after the objectives, design, risks, and potential benefits of our study were explained.

## Preoperative procedure

Photographic images of full smiles were taken preoperatively to compare with postoperative images (Fig. 1A). In the full-smile position, gingival display was measured by a gingival probe, which was placed parallel to the longitudinal axis of the teeth between the left and right second upper premolars; gingival display was measured from the inferior border of the upper lip vermilion to the gingival margin of the anterior maxillary teeth (Fig. 1B). Extraoral and intraoral antisepsis was applied with 2.0% chlorhexidine solution and 0.12% chlorhexidine rinse for 1 min.

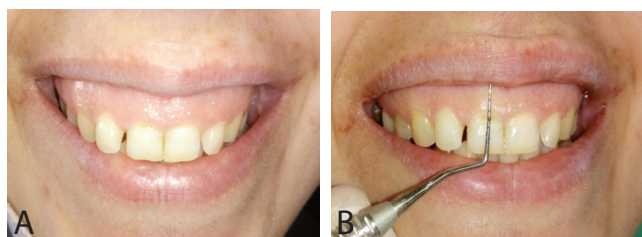

Fig. 1. Preoperative smile (A); measurement of gingival display from the inferior border of the upper lip to the free gingival margin of the anterior maxillary teeth in a full smile (B)

## Surgical technique

Firstly, anesthesia was administered by an infraorbital injection on both sides (2% lidocaine with 1:80,000 epinephrine). Then, a sterile surgical marking pen was used to mark the incision outline on the dried tissues (Fig. 2A,2B). Following this, a full-thickness incision was made nearly 1 mm coronal to the mucogingival junction from the mesial line angle of the right first molar to the mesial line angle of the left first molar, which was V-shaped in the upper lip frenum area. Such a modification is implemented to help preserve the position of the labial midline. The 2<sup>nd</sup> full-thickness incision was made in the labial mucosa, parallel to the 1<sup>st</sup> incision and 10–12 mm apical to it. The 2 incisions were connected at each first molar on both sides, creating an elliptical outline. The epithelium was removed within the outline of the incisions. Then, the attachments of the perioral muscles were dissected from the bone (Fig. 2C–2E). It has to be noted that the amount of tissue excision should be double the amount of gingival display that needs to be reduced, with a maximum of 10–12 mm of tissue. In the present study, all patients had a gummy smile in the range of 4–6 mm, so the width of the tissue strip removed was 8–10 mm. The 2 incision lines were approximated by suturing the muscle layers with Vicryl® 4/0 (GarnTec GmbH, Neidenfels, Germany) (Fig. 2F). Then, the mucosa layer was sutured with interrupted stabilization sutures (silk 3/0) (GarnTec GmbH) at the midline and other locations along the borders of the incision to ensure proper

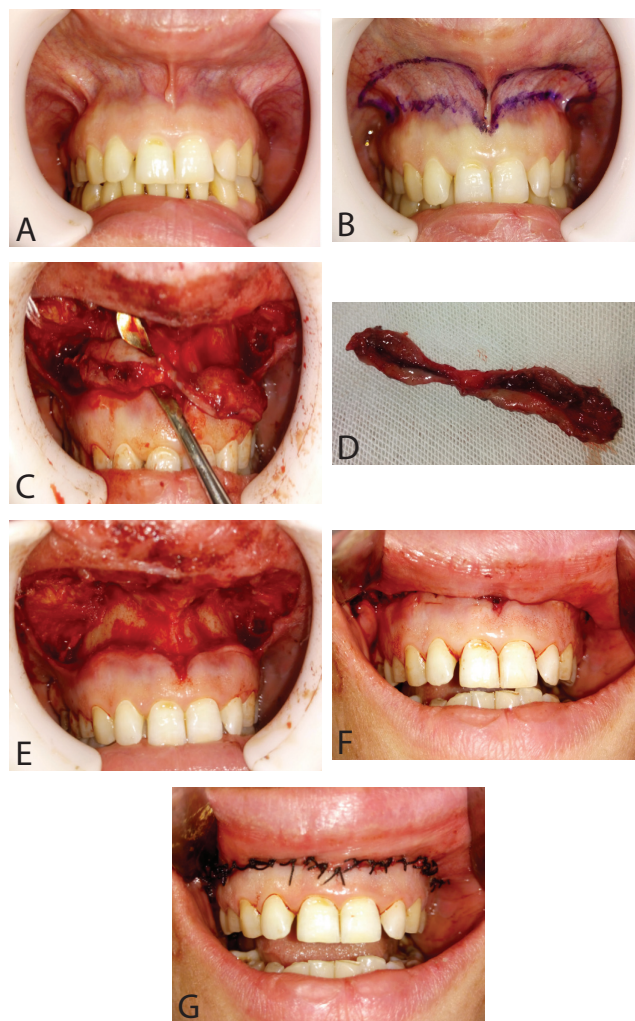


Fig. 2. Preoperative smile (A); the incision outline is made with a sterile surgical marking pen (B); the epithelial and muscle layers are removed (C); the removed strip of the epithelial and muscle layers (D); a full-thickness flap exposes the flap underlying the connective tissue (E); the muscle layer sutures (F); interrupted mucosal sutures (G)

alignment of the lip midline of the teeth. Afterwards, additional interrupted sutures were used to approximate both flap ends (Fig. 2G).

All patients were given nonsteroidal anti-inflammatory drugs (Flam-K®; Neopharma, Damascus, Syria; 50 mg, 3 times/day), oral antibiotics (Augmentin®; SmithKline Beecham, New York, USA; 1g, 2 times/day) and 0.12% chlorhexidine rinse for 1 week postoperatively. Postoperative instruction for all patients included the application of ice packs over the upper lip for several hours, minimizing lip movement when smiling or talking during the first 2 weeks, and avoiding any mechanical trauma to the surgery sites by limiting food intake to only soft foods during the first week. Pain was managed with analgesics. Finally, the suture was removed 2 weeks later (Fig. 3A) and the suture outline was treated, leaving a scar that was not visible when the patient smiled, as it was hidden in the upper lip mucosa (Fig. 3B). Most of the patients reported only tension in the upper lip with a minimum of discomfort and ecchymosis postoperatively.

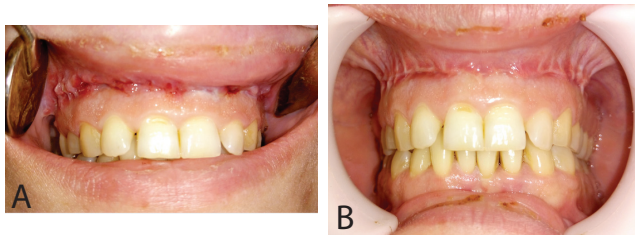


Fig. 3. Sutures removed after 2 weeks (A); healing site after 6 months (B)

### Follow-up after surgery

All patients were followed up at 1, 3 and 6 months postoperatively. The parameter that was assessed during a full active smile (Fig. 4) was the amount of gingival display from the inferior border of the upper lip vermilion to the gingival margin of the anterior maxillary teeth, from the right second premolar to the left second one, measured with a gingival probe placed parallel to the longitudinal axis over the mid-buccal region of the anterior maxillary teeth. All measurements were registered to the nearest millimeter. If part of the clinical crown was covered by the lip (postoperatively), the gingival display level was set at zero point. The follow-up included the recording of postoperative complications, such as infection, dehiscence, numbness, and other complications, as well as questions to the patients to determine if the complications had occurred or not. The postoperative pain was assessed using the visual analog scale (VAS) during follow-up periods. Furthermore, the whole surgical procedure and clinical measurements, taken postoperatively at 1-, 3- and 6-month follow-ups, were set by 1 surgeon to avoid partiality and the variance of results.

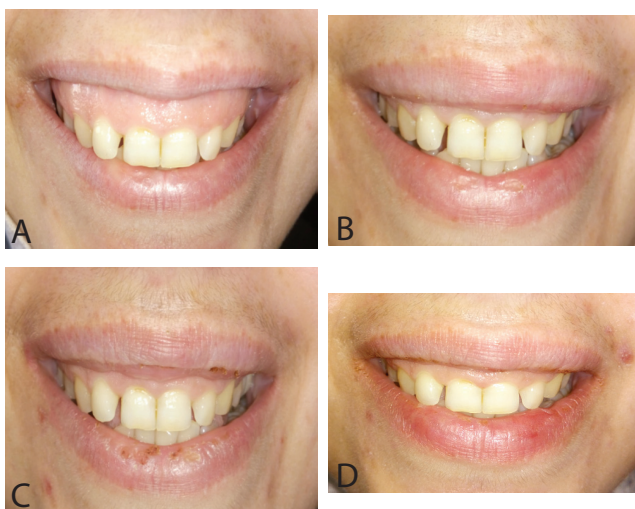

Fig. 4. Preoperative smile (A); smile at 1-month follow-up postoperatively (B); smile at 3-month follow-up postoperatively (C); smile at 6-month follow-up postoperatively (D)

### Statistical analysis

Statistical analysis was conducted using the SPSS v. 13 (IBM Corp., Armonk, USA) and the data was analyzed using a descriptive analysis and the t-test, where p-value <0.05 was considered significant.

### Results

The most important complaint of most patients at the early stage of the postoperative follow-up period was tension feeling in the circumoral area and the upper lip. Specifically, 2 patients expressed blood oozing through the suture in the initial days following the surgery. Most patients expressed edema at a moderate rate, which disappeared in 7 days postoperatively, while only in 3 patients perioral area edema was extended to the lower eyelids with ecchymosis, which lasted for 14 days. Pain recurrences varied between mild pain in 5 patients (35.7%) and moderate pain in 3 patients (21.4%), which was controlled by means of analgesics. Flap dehiscence appeared in 2 patients (14.2%) and numbness appeared in 9 patients (64.2%). No infection was reported in any of the patients. Only 2 patients complained of dry mouth after surgery due to damage to the minor salivary glands in the upper lip mucosa during surgery. The mean rate of gingival display at baseline was 6.36 mm and changed significantly ( $p < 0.05$ ) at 1, 3 and 6 months postoperatively. At 1, 3 and 6 months, gingival display was 0.91 mm, 2.27 mm and 2.45 mm, respectively (Table 1). There was a significant difference in gingival display between the results obtained after 1 and 6 months, but there was no significant difference in gingival display between the 3- and 6-month follow-up, so the results were fairly stable. At 1, 3 and 6 months postoperatively, the obtained reduction was 5.45 mm, 4.09 mm and 3.91 mm, respectively (Table 2, Fig. 5). The present study showed that no complete relapse was recorded in any case during the follow-up periods. However, a partial relapse was recorded in 6 patients.

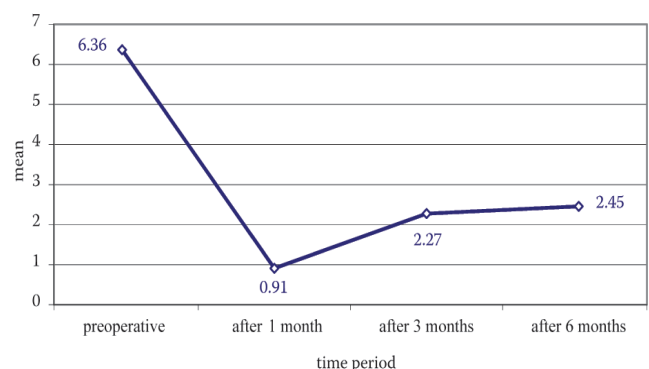


Fig. 5. The mean amount of gingival display in a full smile [mm] in relation to the time period

**Table 1.** The mean, standard deviation, standard error, min, and max of the amount of gingival display in a full smile [mm] in the study sample

Time period	Number of patients	Mean	Standard deviation	Standard error	Min	Max
Preoperative	14	6.36	1.12	0.34	4	6
After 1 month	14	0.91	1.22	0.37	0	4
After 3 months	14	2.27	1.27	0.38	0	4
After 6 months	14	2.45	1.13	0.34	0	4

**Table 2.** Results of the interrelated-samples t-test to show significant differences in the mean values of gingival display in a full smile [mm] at 1, 3 and 6 months postoperatively

Periods compared	Difference between the 2 means	t-test value	Degrees of freedom	p-value
Preoperative – after 1 month	–5.45	–11.066	10	0.000
Preoperative – after 3 months	–4.09	–8.964	10	0.000
Preoperative – after 6 months	–3.91	–10.618	10	0.000
After 1 month – after 3 months	1.36	4.404	10	0.001
After 1 month – after 6 months	1.55	4.949	10	0.001

## Discussion

Excessive gingival display or a “gummy smile” is considered undesirable by many people, which is why an attractive smile can improve the quality of life. The standard amount of gingival display varies between 1 mm and 3 mm.<sup>16</sup> When the amount of gingival display in a full smile is  $\geq 4$  mm, the demand of most patients for an attractive smile is increased. In the literature, many treatment techniques have been reported for the management of a gummy smile, such as botulinum toxin injections, orthodontic surgery, crown lengthening, etc.<sup>1,4,12</sup> In about 20% of patients, a gummy smile is caused by the hypermobility of the upper lip elevator muscles, so a myotomy of the lip elevator muscles can decrease a gummy smile by reducing the function of the muscles.<sup>4</sup> Most patients prefer minor surgical techniques for the management of a gummy smile to major ones. The main goal of this study was to assess the outcomes of lip repositioning surgery (a full-thickness flap with a myotomy of the lip elevator muscles) in the treatment of a gummy smile, caused only by soft tissue disorders (short upper lip, hyperactive lip elevator muscles), to reduce the postoperative relapse in order to maintain stable surgical results for as long as possible and to assess the postoperative complications. All patients treated in this study had gingival display at the baseline ranging from 4 to 6 mm. The technique presented in this article involved 2 full-thickness incisions connected together at the second upper premolar area, outlining an elliptical area of soft tissue which was removed; then, the attachments of the perioral muscles were dissected from the bone. This included the upper lip frenum area being V-shaped to facilitate and maintain the position of the labial midline. The 2 incision lines were approximated by suturing the muscle layers; then, the mucosa layer was sutured with interrupted stabilization sutures. Accordingly, our results exhibited

significant differences in the reduction of gingival display at 1, 3 and 6 months postoperatively. The mean postoperative gingival display at 1, 3 and 6 months postoperatively was 0.91 mm, 2.27 mm and 2.45 mm, respectively. Successful rates at 1 and 6 months were 85.4% and 61.5%, respectively. The results were stable for up to 6 months postoperatively. Only a partial relapse was noticed in 6 patients, without any complete relapse noted. This can be explained by incomplete stripping of the muscles from the bone during the surgical procedure or as a result of muscle memory reattachment to the previous pre-bone bases. These results are consistent with other studies concerning modified lip repositioning surgery.<sup>4,17</sup> Our findings also correlate with a study conducted by Ellenbogen and Swara on 21 patients with a gummy smile, who were treated by a myotomy of the lip elevator muscles through the nose.<sup>15</sup> In their study, silicone implants were used to prevent the relapse after surgery and they appeared to be effective in reducing gingival display. The most pronounced postoperative complication was the feeling of tension in the circumoral area and the upper lip as a result of removing during the operation a strip of the mucosa and muscles, and then suturing. That feeling disappeared within the first 2 weeks after surgery. Pain recurrences varied between mild pain in 5 patients (35.7%) and moderate pain in 3 patients (21.4%) during a few days postoperatively. The pain was controlled by analgesics. Flap dehiscence appeared in 2 patients (14.2%) as a result of strong upper lip movement during the first 2 weeks after surgery. The patients with flap dehiscence were treated using disinfectant solution until the secondary healing was achieved. Numbness in the upper lip appeared in 9 patients (64.2%), which gradually disappeared in the first month after surgery, after the patients were given a course of vitamin B-complex to enhance healing. No infection was reported in any of the patients as a result of infection control principles being followed during surgery and postoperatively.

In the literature, there have been no studies on lip repositioning surgery by means of a myotomy of the lip elevator muscles for the management of a gummy smile and on its postoperative complications.

## Conclusions

The surgical lip repositioning technique proposed in the current study is a less invasive procedure, carried out under local anesthesia, which has shown its effectiveness in reducing the amount of gingival display in a full smile through postoperative follow-up periods; therefore, it can be used to correct a gummy smile in patients with gingival display between 4 and 6 mm. However, additional studies with longer follow-up periods and larger sample sizes may still be needed to evaluate the effectiveness of this technique.

## References

1. Iqbal C, Nandakumar K, Padmakumar TP. Laser assisted treatment of excessive gingival display along with modified lip re-positioning. *IOSR J Dent Med Sci*. 2015;14(7):28–33.
2. Peck S, Peck L, Kataja M. The gingival smile line. *Angle Orthod*. 1992;62(2):91–100.
3. Levine RA, McGuire M. The diagnosis and treatment of the gummy smile. *Compend Contin Educ Dent*. 1997;18(8):757–762,quiz 766.
4. Abdullah W, Khalil H, Alhindi M, Marzook H. Modifying gummy smile: A minimally invasive approach. *J Contemp Dent Pract*. 2014;15(6):821–826.
5. Martins AT, Sakakura CE, Correcirc BE, et al. A modified technique that decreases the height of the upper lip in the treatment of gummy smile patients: A case series study. *J Dent Oral Hyg*. 2012;10:21–28.
6. Pandurić DG, Blašković M, Brozović J, Sušić M. Surgical treatment of excessive gingival display using lip repositioning technique and laser gingivectomy as an alternative to orthognathic surgery. *J Oral Maxillofac Surg*. 2014;72(2):404.e1–11.
7. Miron H, Calderon S, Allon D. Upper lip changes and gingival exposure on smiling: Vertical dimension analysis. *Am J Orthod Dentofacial Orthop*. 2012;141(1):87–93.
8. Hwang W-S, Hur M-S, Hu K-S, et al. Surface anatomy of the lip elevator muscles for the treatment of gummy smile using botulinum toxin. *Angle Orthod*. 2009;79(1):70–77.
9. Livada R, Shiloah J. Gummy smile: Could it be genetic? Hereditary gingival fibromatosis. *J Tenn Dent Assoc*. 2012;92(1):23–26.
10. Garber DA, Salama MA. The aesthetic smile: Diagnosis and treatment. *Periodontol 2000*. 1996;11:18–28.
11. Monaco A, Streni O, Marci MC, Marzo G, Gatto R, Giannoni M. Gummy smile: Clinical parameters useful for diagnosis and therapeutical approach. *J Clin Pediatr Dent*. 2005;29(1):19–25.
12. Simon Z, Rosenblatt A, Dorfman W. Eliminating a gummy smile with surgical lip repositioning. *J Cosmet Dent*. 2007;23(1):100–108.
13. Wei J, Herrler T, Xu H, Li Q, Dai C. Treatment of gummy smile: Nasal septum dysplasia as etiologic factor and therapeutic target. *J Plast Reconstr Aesthet Surg*. 2015;68(10):1338–1343.
14. Ishida LH, Ishida LC, Ishida J, Grynglas J, Alonso N, Ferreira MC. Myotomy of the levator labii superioris muscle and lip repositioning: A combined approach for the correction of gummy smile. *Plast Reconstr Surg*. 2010;126(3):1014–1019.
15. Ellenbogen R, Swara N. The improvement of the gummy smile using the implant spacer technique. *Ann Plast Surg*. 1984;12(1):16–24.
16. Silva CO, Ribeiro-Júnior NV, Campos TV, Rodrigues JG, Tatakis DN. Excessive gingival display: Treatment by a modified lip repositioning technique. *J Clin Periodontol*. 2013;40(3):260–265.
17. Benlier E, Top H, Aygit AC. A new approach to smiling deformity: Cutting of the superior part of the orbicularis oris. *Aesthetic Plast Surg*. 2005;29(5):373–377.

# Erosive and cariogenic potential of various pediatric liquid medicaments on primary tooth enamel: A SEM study

## Erozyjny i próchnicotwórczy potencjał wybranych płynnych leków pediatrycznych w odniesieniu do szkliwa zębów mlecznych – badanie w mikroskopii elektronowej

Elham Fathy Mahmoud<sup>1,A–D,F</sup>, Ola Moustafa Omar<sup>2,A,C–F</sup>

<sup>1</sup> Department of Oral Biology, Faculty of Oral and Dental Medicine, Suez Canal University, Ismailia, Egypt

<sup>2</sup> Department of Pediatric Dentistry, Faculty of Oral and Dental Medicine, Cairo University, Egypt

A – research concept and design; B – collection and/or assembly of data; C – data analysis and interpretation; D – writing the article; E – critical revision of the article; F – final approval of the article

Dental and Medical Problems, ISSN 1644-387X (print), ISSN 2300-9020 (online)

*Dent Med Probl.* 2018;55(3):247–254

### Address for correspondence

Ola Omar  
E-mail: omaromo@yahoo.com

### Funding sources

None declared

### Conflict of interest

None declared

Received on March 3, 2018

Reviewed on April 25, 2018

Accepted on May 23, 2018

### DOI

10.17219/dmp/92317

### Copyright

© 2018 by Wrocław Medical University  
and Polish Dental Society

This is an article distributed under the terms of the  
Creative Commons Attribution Non-Commercial License  
(<http://creativecommons.org/licenses/by-nc-nd/4.0/>)

## Abstract

**Background.** Oral pediatric liquid medications (PLMs) are commonly used in children who suffer from chronic diseases. The physicochemical parameters of PLMs can have a deleterious effect on tooth structure.

**Objectives.** The purpose of the present study was to investigate the erosive and cariogenic effect of widespread PLMs on the surface roughness and structure of primary tooth enamel.

**Material and methods.** The erosive potential of 8 common PLMs used in Egypt was assessed by measuring their inherent pH, using a digital pH electrode meter. The total sugar content was measured according to the Fehling method. The erosive effect of each liquid medicine on the enamel surface of primary teeth was assessed using scanning electron microscopy (SEM) and energy dispersive X-ray (EDX) microanalysis for calcium (Ca) and phosphorus (P) content.

**Results.** Most PLMs revealed an acidic nature, with pH values ranging between 3.47 and 6.92. About 93.8% of analgesics had pH values  $\leq 5.5$ , critical for enamel demineralization, whereas most antitussives and 1 antibiotic (Augmentin®) had pH values  $\geq 6.2$ . Sucrose was present in all the samples studied. The SEM analysis revealed observable differences in the tooth enamel in the experimental groups, with different degrees of surface roughness and erosion.

**Conclusions.** The current results suggest that the pH, sugar content and Ca dissolution ability of PLMs can significantly influence erosion in primary tooth enamel.

**Key words:** scanning electron microscopy, primary teeth, dental erosion, caries, pediatric liquid medications

**Słowa kluczowe:** skaningowy mikroskop elektronowy, zęby mleczne, erozja zębów, próchnica, płynne leki pediatryczne

## Introduction

Dental caries is the most prevalent infectious disease affecting children. This multifactorial disease occurs through the interaction of oral bacteria, carbohydrates, teeth, and time. The production of acids through the fermentation of dietary carbohydrates by the biofilm on tooth surfaces leads to a fall in plaque pH, which results in enamel dissolution and tooth cavitation.<sup>1,2</sup>

Oral pediatric liquid medications (PLMs), such as suspensions, syrups and solutions, are the best line of treatment for younger children. The prolonged use of such liquid medications, particularly in children who suffer from chronic diseases (asthma, respiratory sensitivity and convulsions) or frequent acute conditions (allergic rhinitis, sinusitis, otitis media, and tonsillitis) can have a deleterious effect on tooth structure.<sup>3</sup>

Sugar is added to the majority of oral PLMs to make them palatable and hence acceptable for the child.<sup>4</sup> Sucrose is the most commonly used sweetener for such medications, as it is an easily processed as well as cost-effective substance. Fructose and glucose are also added to some of these medications.<sup>5</sup> These sugars, particularly sucrose, act as a substrate for the oral bacteria, which are responsible for their fermentation, leading to the production of acids and a subsequent drop in intraoral pH.<sup>6</sup>

Acids are added to medicines as buffering agents in order to maintain the chemical consistency and regulate the tonicity of the medicines, or to ensure their physiological compatibility. Acids are commonly used to ameliorate flavor. They are necessary for the acid-base reactions that are used in the case of dispersible and effervescent tablets, designed to be added to water.<sup>7</sup> Since many PLMs have low pH, which is mostly <5.5, they can also promote dental erosion.<sup>8,9</sup>

Several studies have investigated the physicochemical parameters of PLMs to determine their cariogenic and erosive potential. Xavier et al. found that all classes of pediatric drugs showed acidic pH and high total sugar content.<sup>10</sup> In 47.5% of the formulations, sucrose was added, as well as citric acid (39.0%), sodium saccharin (36.4%) and sorbitol (34.8%).<sup>10</sup>

In another study, the average value of the endogenous pH of PLMs was  $4.63 \pm 0.57$ , ranging between 3.93 and 5.68, and nearly all (93.8%) analgesics had pH values  $\leq 5.5$ . In 11 (68.75%) analgesics, sugars were revealed and the sugar content ranged from 5.38 to 69.4 g%, with a mean concentration of  $24.97 \pm 23.24$  g%.<sup>11</sup>

Gupta and Panda also found that PLMs had pH values extending from 4.22 to 6.10. Most PLMs included sucrose at the concentration of 5.38–11.41 g%.<sup>12</sup>

Pediatric liquid medications are potentially erosive and cariogenic due to low pH, high total sugar content

and high viscosity. Furthermore, many studies have shown a positive association between the habitual intake of these drugs and the prevalence of dental caries, which represents a major children's oral health concern, leaving children with chronic or recurrent health problems, who take PLMs frequently or in long-term treatment, at a high risk.<sup>5,11,13–15</sup>

Few studies have investigated the effect of PLMs on the enamel structure. Babu et al. concluded that all the PLMs used in their study revealed an erosive effect on the primary teeth enamel surface, regardless of their pH, when examined under a scanning electron microscope (SEM).<sup>3</sup> An atypical bore-like erosion area was observed in all specimens, differing from one site to another, which could be due to the prismatic nature and structure of the influenced enamel.<sup>3</sup>

For these reasons, the current study aimed to investigate and compare the cariogenic and erosive effect of the PLMs most commonly prescribed in Egypt on primary tooth enamel. The endogenous pH value of PLMs, as well as the concentration of sugars in them, were also evaluated, as they can be indicative of their cariogenic and erosive potential.

## Material and methods

The 8 different PLMs that are most commonly used in Egypt were selected for this study. The PLMs included usually prescribed analgesics and antipyretics, antibiotics, antitussive drugs, and nutritional supplements (Table 1). Their endogenous pH was determined using a pH electrode meter, and the Fehling method was used to measure the total sugar content.

The erosive effect of each liquid medicine on primary tooth enamel was assessed by SEM. Specimens were prepared from 50 extracted or exfoliated sound primary teeth free from any carious lesion and/or restorations. Enamel specimens were cut at the dentin-enamel junction, and the samples were placed in Teflon molds and embedded in self-curing acrylic resin (Paladur 1; Heraeus Kulzer, Bad Homburg v. d. Höhe, Germany), exposing approx. 2 mm × 2 mm of the buccal surface, parallel to the bottom of the mold.

The control group tooth samples (n = 10) were immersed in artificial saliva (Pickering Laboratories, Mountain View, USA) for 3 different time intervals: 3, 5 and 8 days, 20 min for each session. The study group tooth samples (n = 40) were also maintained for 3 different time intervals: 3, 5 and 8 days, 20 min for each session, in the various selected PLMs, and then immersed in artificial saliva to apply a pH circulation model for the rest. Primary tooth specimens were observed under a SEM after each time interval.



**Table 1.** The pH values of PLMs and sucrose concentration in different samples

PLMs	Generic name	Trade name	mean pH	Concentration of sucrose [g%] (mean ±SD)
Analgesics	paracetamol	Adol®	5.33	16.02 ±0.01
	ibuprofen	Brufen®	4.42	9.08 ±0.03
Antibiotics	amoxicillin	Amoxil®	5.68	11.04 ±0.06
	amoxicillin + clavulanate potassium	Augmentin®	6.22	3.17 ±0.04*
Nutritional supplements	multivitamin	Vitamount®	3.47*	17.18 ±1.05*
	multivitamin	Omega-3®	4.01	8.22 ±0.21
Antitussives	dextromethorphan diphenhydramine Hcl ephedrine Hcl guaiphenesin	Bronchophane®	6.74	7.01 ±2.03
	oxomemazine/guaiphenesin	Toplexil N®	6.92*	9.04 ±0.02

PLMs – pediatric liquid medications; SD – standard deviation; \* the highest amount of sucrose.

## Measurement of pH

The pH of the PLMs was measured using a digital pH meter (Hanna Instruments, Woonsocket, USA). The amount of 20 mL of each PLM in a glass beaker was placed in a water bath thermostatically controlled at 37°C. A glass electrode was inserted into the syrup, displaying pH on the meter. Each sample was tested 3 times to record a mean measurement.

## Measurement of total sugar content

The Fehling method was used for total sugar content determination in the PLM samples used in this study.<sup>acc.16</sup> The total sugar percentage was calculated from the following equation:

$$\text{Total sugars [\%]} = \frac{\text{FEQ} \times \text{dilution} \times 100}{\text{VTITRATION}}$$

where

FEQ – equivalence factor;

VTITRATION – titration volume required.

## Observation with scanning electron microscopy and energy dispersive X-ray microanalysis

For the SEM examination, the teeth were mounted on the SEM holder using removable adhesive. Each tooth was coated under vacuum conditions with gold by means of a sputter coater and adjusted to be examined under low vacuum using a SEM (SEM JEOL-JSM® 6360LV; Japan Electron Optics Laboratory Co., Ltd., Tokyo, Japan) at the SEM Unit, National Research Center, Cairo, Egypt. The

surface morphology of the collected teeth was evaluated, and representative photomicrographs were captured and stored digitally. The analysis of the calcium (Ca) and phosphorus (P) content in wt% of enamel was additionally determined in each group using energy dispersive X-ray (EDX) microanalysis at the SEM Unit.

## Statistical analysis

The results of the EDX microanalysis were used to determine the Ca and P content in wt% of enamel in all groups. The Ca and P content were then converted into Ca/P ratios, which reflect the level of mineralization of teeth. Collecting, coding and analyzing the obtained data were done with The Statistical Package for the Social Sciences (SPSS) software v. 20 (SPSS Inc., Chicago, USA) for Windows 7. The inferential statistics were done after the descriptive analysis, followed by the analysis of variance (ANOVA, F-test) to compare the mean content of Ca and P, and Ca/P ratios in the study groups. Then, the least significant difference (LSD) post hoc test was done to compare the 2 groups. A cut-off point of 0.05 was established for the p-value.

## Results

Most PLMs revealed an acidic nature, with pH values ranging between 3.47 and 6.92. Most of the analgesics, about 93.8%, had pH values ≤5.5, critical for enamel dissolution, whereas most antitussives and the antibiotic Augmentin® had pH values ≥6.2. Sucrose was present in all the samples and the multivitamin drug Vitamount® contained the highest amount of sucrose (17.18 ±1.05 g%). The concentration of sucrose in the samples studied is given in Table 1.

## Observation of primary tooth enamel with scanning electron microscopy and energy dispersive X-ray microanalysis

In general, the SEM analysis revealed observable differences in the tooth enamel in the experimental groups, with different degrees of surface roughness and erosion. The primary teeth specimens submerged in artificial saliva (the control group I) showed an intact, relatively flat and smooth enamel surface with no morphological irregularities and no evidence of erosion after 3, 5 and 8 days (Fig. 1). The specimens immersed in analgesic PLMs (group II) showed a mildly roughened enamel surface with minimal surface loss after 3 days; then, incremental zones of porosity and intraprismatic dissolution with a fish-scale appearance occurred on the enamel surface after 5 and 8 days (Fig. 2).

The enamel surface of the primary teeth specimens that were submerged in antibiotic PLMs (group III) revealed an irregular, pitted and rough, damaged, cracked surface, having numerous pores of different size and depth (Fig. 3).

The specimens that were immersed in multivitamin PLMs (group IV) revealed a severely irregular, rough, damaged enamel surface with a fish-scale appearance, having multiple craters with elevated peripheries. Some areas of dentin were exposed, being the evidence of generalized structure loss (Fig. 4).

The examination of the specimens exposed to antitussive PLMs (group V) revealed a relatively smooth enamel surface with little porosity and minimal surface loss, with no evidence of erosion even after 8 days (Fig. 5).

The comparison of the element content within the groups using one-way ANOVA revealed statistically highly significant differences in regard to Ca, P and Ca/P ratios between all groups (Table 2). For intergroup comparison, the results of the post hoc test suggested that the Ca and P content were significantly lower in the antibiotic PLMs group III and multivitamin PLMs group IV as compared to the control group. The antitussive PLMs group V showed similar Ca content and higher P content compared to the control group. All statistical results are summarized in Table 3.

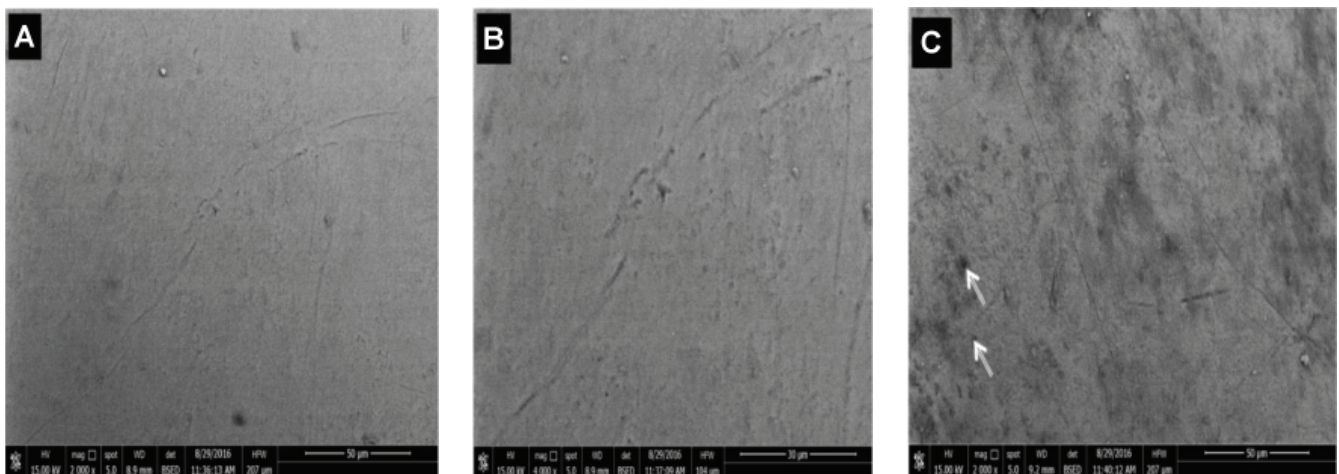


Fig. 1. Scanning electron micrograph of the enamel surface in group I (control): a smooth, intact enamel surface with no evidence of erosion (A, B); characteristic minute depressions representing rod ends (arrows) (C)

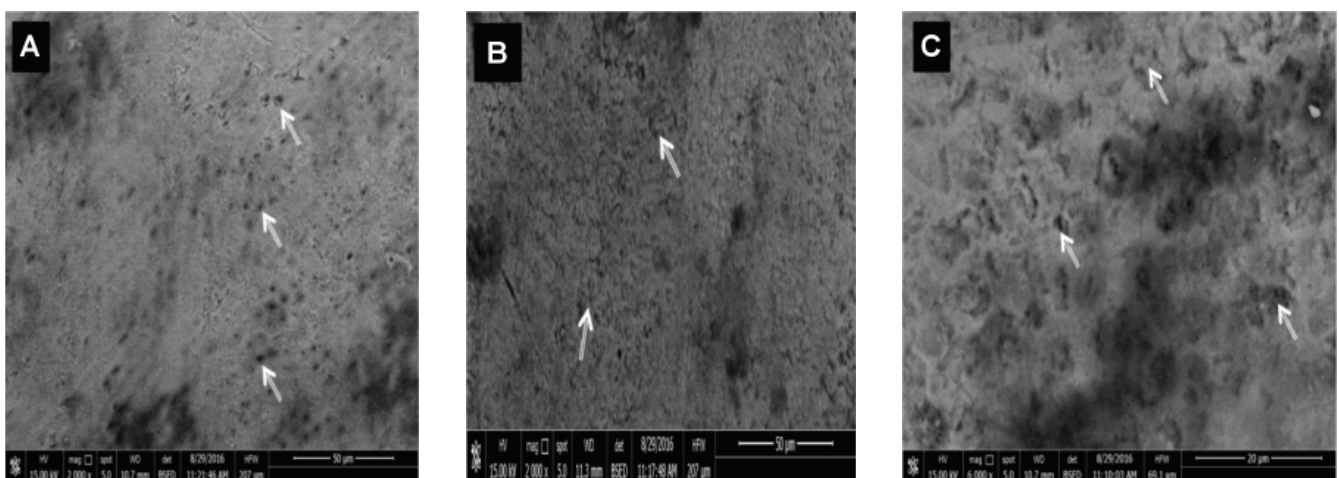
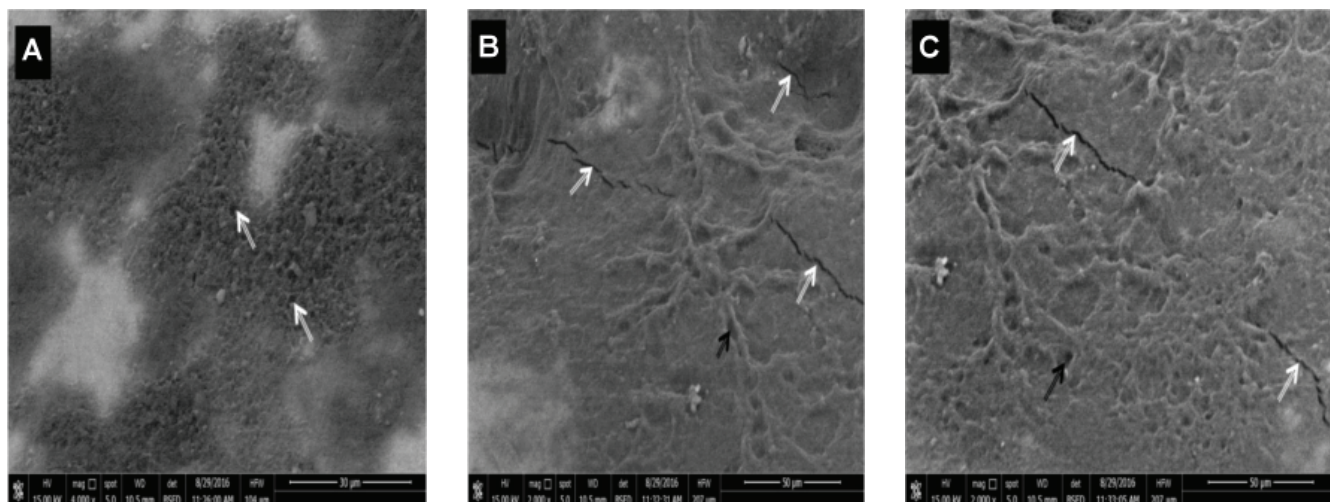
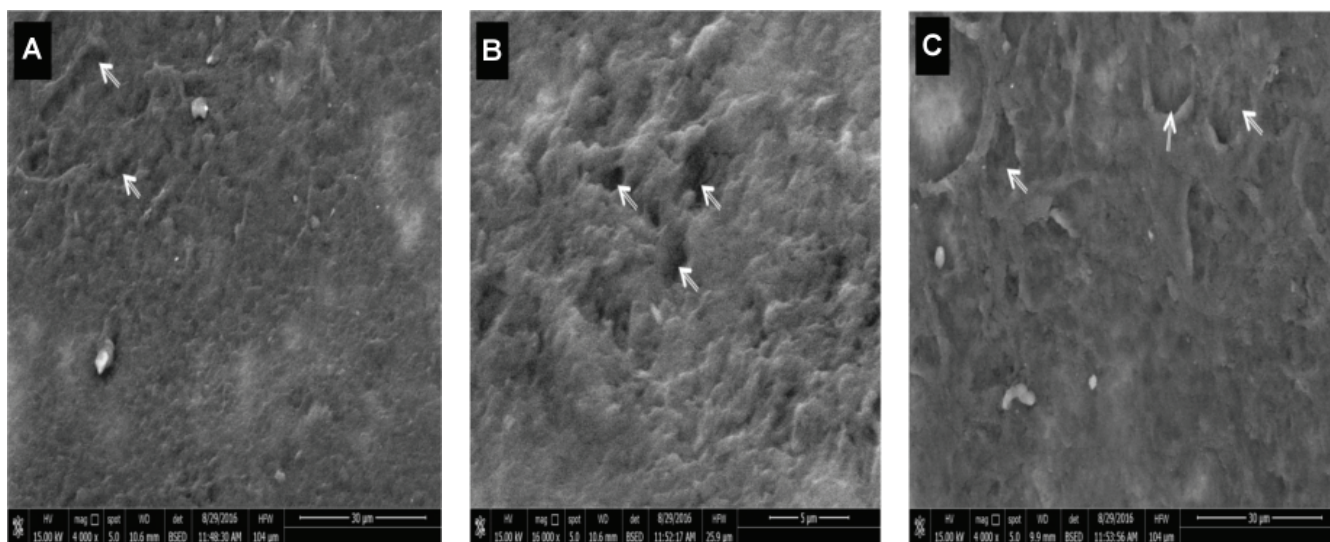


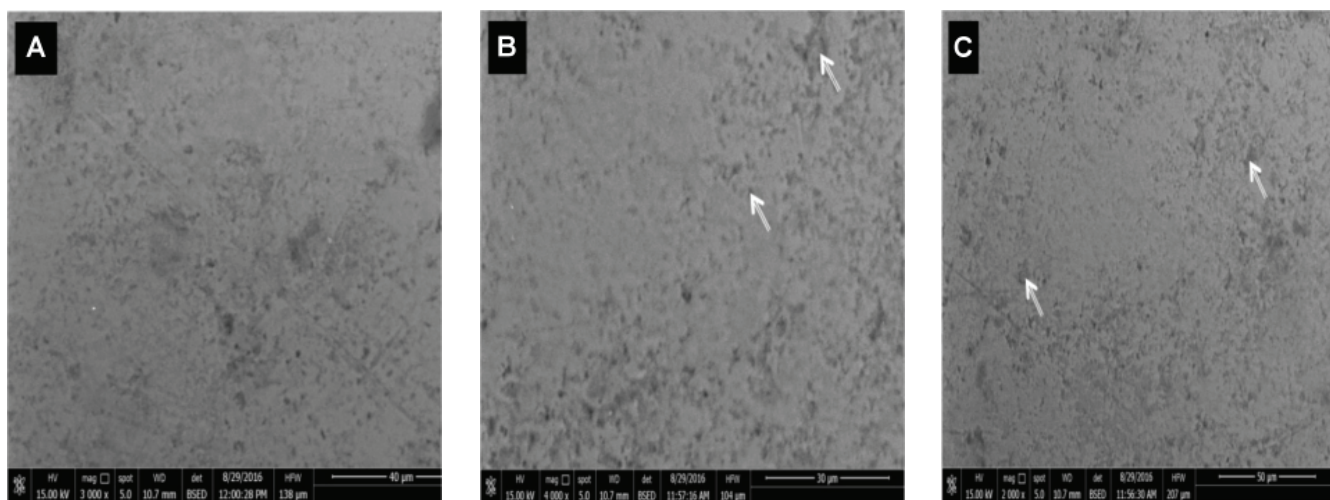
Fig. 2. Scanning electron micrograph of the enamel surface of group II (analgesic PLMs) showing zones of porosity and intraprismatic dissolution with a fish-scale appearance (arrows)  
PLMs – pediatric liquid medications.



**Fig. 3.** Scanning electron micrograph of the enamel surface of group III (antibiotic PLMs): an irregular, pitted and rough surface (arrows) (A); a rough, damaged, cracked surface (white arrows), having numerous pores of different size and depth (black arrows) (B, C)  
PLMs – pediatric liquid medications.



**Fig. 4.** Scanning electron micrograph of the enamel surface of group IV (multivitamin PLMs): an irregular, rough, damaged enamel surface, having multiple craters with elevated peripheries and some areas of dentin exposed (arrows) (A, B); (D3) the enamel surface roughness and generalized structure loss, and some areas in the enamel surface with a fish-scale appearance (arrows) (C)  
PLMs – pediatric liquid medications.



**Fig. 5.** Scanning electron micrograph of the enamel surface of group V (antitussive PLMs) showing a smooth enamel surface with little porosity, with no evidence of erosion (arrows)  
PLMs – pediatric liquid medications.

**Table 2.** Comparison of the mean calcium (Ca) and phosphorus (P) content [wt%], and Ca/P ratios of all groups, using one-way ANOVA

Group	Value	Ca	P	Ca/P ratio
Group I	mean	48.861	22.413	2.180
	±SD	±0.587	±0.759	±0.211
Group II	mean	35.961	16.734	2.149
	±SD	±1.001	±0.103	±0.211
Group III	mean	30.853	13.012	2.371
	±SD	±0.691	±0.843	±0.101
Group IV	mean	27.801	10.762	2.583
	±SD	±0.806	±0.419	±0.738
Group V	mean	47.922	23.639	1.985
	±SD	±0.902	±0.839	±0.216
ANOVA		231.468	112.122	21.254
p-value		0.000 highly significant	0.000 highly significant	0.000 highly significant

Group I – control; group II – analgesic PLMs; group III – antibiotic PLMs; group IV – multivitamin PLMs; group V – antitussive PLMs; PLMs – pediatric liquid medications; SD – standard deviation; ANOVA – analysis of variance.

**Table 3.** Intergroup comparison of calcium (Ca) and phosphorus (P) content [wt%], and Ca/P ratios using the post hoc test

Dependent variable	Control group	Other groups	p-value
Ca	group I	group II	0.000*
		group III	0.000*
		group IV	0.000*
		group V	0.832
P	group I	group II	0.000*
		group III	0.000*
		group IV	0.000*
		group V	0.672
Ca/P ratio	group I	group II	0.000*
		group III	0.000*
		group IV	0.000*
		group V	0.713

Group I – control; group II – analgesic PLMs; group III – antibiotic PLMs; group IV – multivitamin PLMs; group V – antitussive PLMs; PLMs – pediatric liquid medications; \* a statistically significant difference ( $p < 0.05$ ) among group I and groups II & III & IV ( $n = 10$ ), where the post hoc test was used for intergroup comparison.

## Discussion

In spite of a large number of studies on dental erosion, there is still a deficiency of information regarding the erosive influence of PLMs on primary teeth. In the present study, we investigated the erosive effect of various PLMs on primary tooth enamel.

Pediatric liquid medications may possess a high erosive potential due to the presence of an acid component in their formula. Therefore, the analysis of their pH is an important factor when studying dental erosion. The findings of our study showed that the pH of the studied medications ranged between 3.47 and 6.92, with multivitamins followed by analgesics having the lowest pH values. This range was

similar to the findings of Gupta and Panda, where the pH of the studied medications ranged from 4.22 to 6.10.<sup>12</sup> Our results are also in agreement with other studies, where the pH of PLMs ranged from 2.5 to 6.9.<sup>17,18</sup> Furthermore, another study found that the pH of most of the investigated medications were  $<5.5$ .<sup>10</sup> A pH of 5.5 is considered critical for enamel dissolution.<sup>19</sup> In an in vivo study, it was concluded that PLMs cause a drop in plaque pH sufficient to cause decalcification within 2–10 min following the initial exposure of teeth to those medicaments.<sup>20</sup> Multivitamins and analgesics are widely used by children, usually without medical supervision; therefore, children using these drugs will most probably experience a deleterious accumulative effect that might lead to erosive and carious lesions on the tooth enamel surface.

Sugars are commonly added to oral liquid medications to give them a pleasant taste.<sup>17</sup> Sugar-rich medicines cause a drop in the pH of dental plaque, increasing the risk of demineralization.<sup>21</sup> Pediatric medicines including sucrose and/or other fermentable carbohydrates and having low pH display cariogenic and erosive effects. Other factors are also noted, e.g., frequency of administration, dose and pattern of use, as well as acidity of the formulation.<sup>22,23</sup> All the medicines tested in the present study contained sucrose, with mean concentrations varying from 3.17 to 17.18 g%, which is in accordance with various studies. Similarly, all the PLMs in a study by Gupta and Panda contained sucrose and it ranged from 5.38 to 11.41 g%.<sup>12</sup> On the other hand, our results are lower compared to those reported in other studies, where not all the studied PLMs contained sugars. Other authors noted that the amount of sucrose in PLMs ranged from 0 to 67 g%.<sup>15</sup> Some studies showed a wider range of sugar content, where the concentrations varied from 11.36 to 85.99 g%,<sup>24</sup> from 5 to 54 g%<sup>8</sup> and from 5.38 to 69.4 g%.<sup>11</sup> Additionally, higher percentages were observed by some authors, ranging from 53.2 to 86.9 g%.<sup>10,17</sup> Differences in

sugar concentration between studies might be attributed to the method of sugar identification; in the current study, we used the Fehling method for total sugar content determination.

All the PLMs tested in this study showed an erosive effect on the primary enamel surface, irrespective of their pH, when viewed under a SEM. Although antibiotics showed pH of 5.68 and 6.22, which were slightly higher than the pH value critical for enamel, under a SEM the enamel specimens exposed to antibiotics showed an irregular, pitted and rough surface with numerous pores of different size and depth. These results are in agreement with other studies, which showed that although the pH of the PLMs was not near the critical value, erosion was observable on the enamel surfaces during SEM examination.<sup>3,25</sup> Furthermore, specimens immersed in multivitamin PLMs (group IV) revealed a severely irregular, rough, damaged enamel surface with areas of exposed dentin being the evidence of generalized structural loss, which indicated high erosive potential of these medications. Other studies reported similar typical prism patterns on enamel surfaces treated with amoxicillin for 1 min, theophylline for 1 min and multivitamin for 10 min.<sup>3</sup> Similar results were also reported in the cases where the specimens exposed to ferrous sulfate (an iron supplement) and salbutamol sulfate (a bronchodilator) clearly exhibited structural enamel loss with an irregular enamel surface.<sup>26</sup>

The SEM results of our study can be explained by the fact that primary teeth are more liable to erosion, as they are known to be less mineralized than permanent teeth, and the enamel surface is also less mature and thus more prone to dental caries and erosion.<sup>27</sup>

Tooth enamel is composed of calcium ( $\text{Ca}^{2+}$ ), phosphate ( $\text{PO}_4^{3-}$ ), hydroxide ( $\text{OH}^-$ ), and minimal amounts of fluoride ( $\text{F}^-$ ) ions. Enamel crystals are in a persistent balance with the saliva, where a constant substitution of  $\text{Ca}^{2+}$ ,  $\text{PO}_4^{3-}$ ,  $\text{OH}^-$ , and  $\text{F}^-$  between enamel and the saliva takes place. Enamel is likely to lose more of these ions to the surrounding medium in order to acquire a new state of equilibrium when the teeth are subjected to substances that have a low concentration of these ions.<sup>28</sup> Furthermore, the dissolution of enamel is highly dependent on the pH of the substance surrounding it.<sup>29,30</sup> That is why, in our study, the pH analysis played a significant role in the assessment of the dental erosion process, which was also reported by West et al.<sup>31</sup>

All the PLMs used in the current work demonstrated calcium dissolution, with the maximum amount of dissolution at the 8-day interval, followed by the 5-day and 3-day intervals. Similar results were obtained in a study performed by Hunter et al.<sup>32</sup> The analysis of the results revealed a significantly lower Ca and P content of all groups studied compared to the control, except group V (antitussives). A higher Ca concentration in a given solution increases its degree of saturation, which consequently decreases its erosive effect.<sup>33</sup> This statement explains our

findings, where group V showed a smooth enamel surface with no evidence of erosion and with little porosity observable under a SEM, which was coupled with high Ca content in this group, similar to that noted for the control group. Moreover, similar results showed that Ca ions are dissolved from the hydroxyapatite before phosphate ions, thus explaining the relationship between Ca concentration and erosion, and the lack of association between phosphate concentration and erosion.<sup>34</sup>

## Conclusions

The current study emphasizes the positive association between PLMs and erosion and/or dental caries, which is deleterious to children's oral health.

## Recommendations

Parents should be strictly advised to apply oral hygiene measures for their children after each therapeutic dose of PLMs. Sugar-free medications (or with non-cariogenic artificial sweeteners) should be suggested. Administering PLMs with a dropper hinders the contact of such medications with the tooth surfaces.

## References

- Sharma A, Deshpande S. Effect of sucrose in different commonly used pediatric medicines upon plaque pH in human subjects. *J Ind Soc Pedod Prev Dent*. 2011;29(2):144–148.
- Lussi A, Megert B, Shellis RP, Wang X. Analysis of the erosive effect of different dietary substances and medications. *Br J Nutr*. 2012;107(2):252–262.
- Babu KL, Rai K, Hedge AM. Pediatric liquid medicaments: Do they erode the teeth surface? An in vitro study: Part I. *J Clin Pediatr Dent*. 2008;32(3):189–194.
- Nunn JH, Ng SK, Sharkey I, Coulthard M. The dental implications of chronic use of acidic medicines in medically compromised children. *Pharm World Sci*. 2001;23(3):118–129.
- Bigeard L. The role of medication and sugars in pediatric dental patients. *Dent Clin North Am*. 2000;44(3):443–456.
- Pierro VS, Abdelnur JP, Maia LC, Trugo LC. Free sugar concentration and pH of paediatric medicines in Brazil. *Community Dent Health*. 2005;22(3):180–183.
- Maguire A, Baqir W, Nunn JH. Are sugars-free medicines more erosive than sugars containing medicines? An in vitro study of paediatric medicines with prolonged oral clearance used regularly and long-term by children. *Int J Paediatr Dent*. 2007;17(4):231–238.
- Pomarico L, Czauski G, Portela MB, et al. Cariogenic and erosive potential of the medication used by HIV-infected children: pH and sugar concentration. *Community Dent Health*. 2008;25(3):170–172.
- Nankar M, Walimbe H, Ahmed Bijle MN, Kontham U, Kamath A, Muchandi S. Comparative evaluation of cariogenic and erosive potential of commonly prescribed pediatric liquid medicaments: An in vitro study. *J Contemp Dent Pract*. 2014;15(1):20–25.
- Xavier AFC, Moura EF, Azevedo WF, Vieira FF, Abreu MH, Cavalcanti AL. Erosive and cariogenicity potential of pediatric drugs: Study of physicochemical parameters. *BMC Oral Health*. 2013;13:71.
- Saeed S, Bshara N, Trak J, Mahmoud G. An in vitro analysis of the cariogenic and erosive potential of pediatric liquid analgesics. *J Indian Soc Pedod Prev Dent*. 2015;33(2):143–146.
- Gupta M, Panda S. Cariogenic potential of the commonly prescribed pediatric liquid medicaments in the Kingdom of Saudi Arabia: An in vitro study. *J Contemp Dent Pract*. 2017;18(4):307–311.

13. Shaw L, Glenwright HD. The role of medications in dental caries formation: Need for sugar-free medication for children. *Paediatrician*. 1989;16(3-4):153-155.
14. Neves BG, Pierro VS, Maia LC. Perceptions and attitudes among parents and guardians on the use of pediatric medicines and their cariogenic and erosive potential [in Portuguese]. *Cien Saude Colet*. 2007;12(5):1295-1300.
15. Peres KG, Oliveira CT, Peres MA, Raymundo Mdos S, Fett R. Sugar content in liquid oral medicines for children. *Rev Saude Publica*. 2005;39(3):486-489.
16. Lane JH, Eynon L. Determination of reducing sugars by means of Fehling's solution with methylene blue as internal indicator. *J Soc Chem Ind Trans*. 1923:32-36. Cited from: Cavalcanti AL, Sousa RIM, Clementino MA, Vieira FF, Cavalcanti CL, Xavier AFC. In vitro analysis of the cariogenic and erosive potential of paediatric antitussive liquid oral medications. *Tanzan J Health Res*. 2012;14(2):1-8.
17. Cavalcanti AL, Sousa RIM, Clementino MA, Vieira FF, Cavalcanti CL, Xavier AFC. In vitro analysis of the cariogenic and erosive potential of paediatric antitussive liquid oral medications. *Tanzan J Health Res*. 2012;14(2):1-8.
18. Passos IA, Sampaio FC, Martínez CR, Freitas CHM. Sucrose concentration and pH in liquid oral pediatric medicines of long-term use for children. *Rev Panam Salud Publica*. 2010;27(2):132-137.
19. Cavalcanti AL, Fernandes LV, Barbosa AS, Vieira FF. pH, titratable acidity and total soluble solid content of pediatric antitussive medicines. *Acta Stomatol Croat*. 2008;42(2):164-170.
20. Sunitha S, Prashanth GM, Shanmukhappa, Chandu GN, Subba Reddy VV. An analysis of concentration of sucrose, endogenous pH, and alteration in the plaque pH on consumption of commonly used liquid pediatric medicines. *J Indian Soc Pedod Prev Dent*. 2009;27(1):44-48.
21. Rekola M. In vivo acid production from medicines in syrup form. *Caries Res*. 1989;23(6):412-416.
22. Costa CC, Almeida IC, Raymundo MS, Fett R. Analysis of the endogenous pH, acidity and sucrose concentration in pediatric medicines. *Rev Odonto Ciênc*. 2004;19:164-169.
23. Marquezan M, Marquezan M, Pozzobon RT, Oliveira MDM. Medicines used by pediatric dentistry patients and its cariogenic potential. *RPG Rev Pós Grad*. 2007;13(4):334-339.
24. Neves BG, Farah A, Lucas E, Sousa VP, Maia LC. Are paediatric medicines risk factors for dental caries and dental erosion? *Community Dent Health*. 2010;27(1):46-51.
25. Tupalli AR, Satish B, Shetty BR, Battu S, Kumar JP, Nagaraju B. Evaluation of the erosive potential of various pediatric liquid medications: An in vitro study. *J Int Oral Health*. 2014;6(1):59-65.
26. Scatena C, Galafassi D, Gomes-Silva JM, Borsatto MC, Serra MC. In vitro erosive effect of pediatric medicines on deciduous tooth enamel. *Braz Dent J*. 2014;25(1):22-27.
27. Johansson AK, Sorvari R, Birkhed D, Meurman JH. Dental erosion in deciduous teeth – an in vivo and in vitro study. *J Dent*. 2001;29(5):333-340.
28. Shellis RP, Featherstone JD, Lussi A. Understanding the chemistry of dental erosion. *Monogr Oral Sci*. 2014;25:163-179.
29. Barbour ME, Parker DM, Allen GC, Jandt KD. Enamel dissolution in citric acid as a function of calcium and phosphate concentrations and degree of saturation with respect to hydroxyapatite. *Eur J Oral Sci*. 2003;111(5):428-433.
30. Attin T, Meyer K, Hellwig E, Buchalla W, Lennon AM. Effect of mineral supplements to citric acid on enamel erosion. *Arch Oral Biol*. 2003;48(11):753-759.
31. West NX, Hughes JA, Addy M. The effect of pH on the erosion of dentine and enamel by dietary acids in vitro. *J Oral Rehabil*. 2001;28(9):860-864.
32. Hunter M, West N, Hughes J, Newcombe R, Addy M. Erosion of deciduous and permanent dental hard tissues in the oral environment. *J Dent*. 2000;28(4):257-263.
33. Dawes C. What is the critical pH and why does a tooth dissolve in acid? *J Can Dent Assoc*. 2003;69(11):722-724.
34. Hemingway CA, Parker DM, Addy M, Barbour ME. Erosion of enamel by non-carbonated soft drinks with and without toothbrushing abrasion. *Br Dent J*. 2006;201(7):447-450.

# Acid resistance of dental enamel treated with remineralizing agents, Er:YAG laser and combined treatments

## Odporność szkliwa na kwasy po zastosowaniu środków remineralizujących, lasera Er:YAG i ich połączenia

Alma Y. Ceballos-Jiménez<sup>1,B–D,F</sup>, Laura E. Rodríguez-Vilchis<sup>1,A–F</sup>, Rosalía Contreras-Bulnes<sup>1,A–F</sup>, Jesús Á. Arenas Alatorre<sup>2,A,C,F</sup>, Ulises Velazquez-Enriquez<sup>1,C,E,F</sup>, Maria M. García-Fabila<sup>3,B,F</sup>

<sup>1</sup> Advanced Studies and Research Center, Faculty of Dentistry, Autonomous University of the State of Mexico, Toluca, Mexico

<sup>2</sup> Department of Condensed Matter, Institute of Physics, National Autonomous University of Mexico, Mexico City, Mexico

<sup>3</sup> Instrumental Analysis Laboratory, Institute of Chemistry, Autonomous University of the State of Mexico, Toluca, Mexico

A – research concept and design; B – collection and/or assembly of data; C – data analysis and interpretation;

D – writing the article; E – critical revision of the article; F – final approval of the article

Dental and Medical Problems, ISSN 1644-387X (print), ISSN 2300-9020 (online)

Dent Med Probl. 2018;55(3):255–259

### Address for correspondence

Laura E. Rodríguez-Vilchis  
E-mail: rovilaster@gmail.com

### Funding sources

None declared

### Conflict of interest

None declared

### Acknowledgements

This research was supported by the Autonomous University of the State of Mexico and the National Autonomous University of Mexico.

Received on June 5, 2018

Reviewed on June 28, 2018

Accepted on August 3, 2018

### DOI

10.17219/dmp/93960

### Copyright

© 2018 by Wrocław Medical University  
and Polish Dental Society

This is an article distributed under the terms of the  
Creative Commons Attribution Non-Commercial License  
(<http://creativecommons.org/licenses/by-nc-nd/4.0/>)

## Abstract

**Background.** It has been reported that lasers can increase resistance to enamel acids, and when it is associated with fluoride, both are reported to work in synergy, achieving a reduction of the solubility of enamel. Currently, other remineralizing agents have been shown to effectively inhibit enamel demineralization.

**Objectives.** The aim of the study was to evaluate acid resistance in the occlusal surface of permanent teeth, treated with remineralizing agents, erbium-doped yttrium aluminum garnet (Er:YAG) laser and combined treatments.

**Material and methods.** Eighty samples of enamel were randomly assigned to 8 groups ( $n = 10$ ): a control group, and groups treated with sodium fluoride (NaF), casein phosphopeptide-amorphous calcium phosphate with NaF (CPP-ACPF), hydroxyapatite-NaF-xylitol (HA-NaF-X), Er:YAG laser (L), L+NaF, L+CPP-ACPF, and L+HA-NaF-X. The samples were placed in an acid solution and the released calcium (Ca) was quantified by atomic absorption spectrometry.

**Results.** In the groups treated with NaF and L+NaF, a lower loss of Ca was observed —  $15.27 \pm 5.17$  mg/L and  $15.20 \pm 3.85$  mg/L, respectively — compared to the control group, which had the highest Ca loss:  $21.93 \pm 13.24$  mg/L.

**Conclusions.** Although the combination of Er:YAG laser plus NaF and the single application of NaF showed values suggesting superior resistance to demineralization of dental enamel compared to all the other groups in the study, no statistically significant differences were found to support this assertion.

**Key words:** erbium-doped yttrium aluminum garnet laser, occlusal surface, remineralizing agents, acid resistance

**Słowa kluczowe:** laser erbowo-jagowy, powierzchnia żująca, środki remineralizujące, odporność na kwasy

## Introduction

Dental enamel is the hardest of the mineralized tissues of the human body.<sup>1</sup> Loss of this tissue can be caused by different processes in the oral cavity, namely attrition, erosion, abrasion, and tooth decay.<sup>2</sup> In dental caries, this phenomenon occurs due to the presence of acids, which are a result of bacterial carbohydrate metabolism. First, a mineral loss occurs, and when it increases, it develops into a cavity.<sup>2,3</sup> Once a cavity is formed, enamel cannot be repaired in a natural way and tooth restoration is necessary.<sup>3</sup> Therefore, enamel resistance against acid attack must be increased before cavitation.

The effectiveness of fluoride for the prevention of dental caries has been clearly established in several studies.<sup>4</sup> Furthermore, it enhances resistance to acid attack through the transformation of hydroxyapatite (HA) into fluorapatite. At the same time, it reduces the ability of bacteria to produce acid, having joint bactericide and remineralizing effects.<sup>5</sup>

Nowadays fluoride is added to several remineralizing agents available on the market in order to improve the ability of fluoride to restore the balance of minerals of the dental structure, such as casein phosphopeptide-amorphous calcium phosphate (CPP-ACP) and HA, among others. The anticariogenic properties of such remineralizing agents are explained by their mineral contribution to the dental structure – calcium (Ca) and phosphorus (P) ions, which inhibit demineralization and promote remineralization, resulting in the restoration of the dental surface.<sup>6–11</sup>

Several studies have shown that laser irradiation using erbium-doped yttrium aluminum garnet (Er:YAG) laser at low energy settings increases fluoride absorption, and increases enamel resistance to acid attack more effectively than fluoride by itself.<sup>12–16</sup> However, there are few studies that combine Er:YAG laser irradiation with remineralizing agents added to fluoride, such as CPP-ACP.<sup>17</sup> Therefore, the purpose of this study was to evaluate acid resistance in the occlusal surface of permanent teeth, treated with remineralizing agents, Er:YAG laser and combined treatments.

## Material and methods

### Ethical considerations

This study was carried out after obtaining the approval of the Research Ethics Committee at the Advanced Studies and Research Center in the Faculty of Dentistry at the Autonomous University of the State of Mexico (Toluca, Mexico). All the subjects included in this research signed a consent form.

### Tooth selection and sample preparation

Unerrupted third molars, extracted for therapeutic reasons, were stored in 0.2% thymol solution at 4°C until required. The teeth were evaluated with the DIAGNOdent<sup>®</sup>

pen (KaVo, Biberach, Germany) and 20 of them, with values between 0 and 13 (healthy teeth), were selected for the study. The molars were sectioned at the cement-enamel junction with a BesQual diamond disc (Meta Dental Corp., Glendale, USA), mounted on a low-speed motor (Brasseler USA, Savannah, USA) under deionized water irrigation. The crown was fixed to a glass slide with thermoplasticized epoxy resin (Allied High Tech Products Inc., Rancho Dominguez, USA).<sup>15,18–20</sup> Buccolingual cuts were performed with a diamond wheel (South Bay Technology, Inc., San Clemente, USA) under constant irrigation to obtain 4 samples (2-millimeter wide). A reference line was marked 2 mm from the central occlusal fissure with a diamond disc (MDT Micro Diamond Technologies Ltd., Afula, Israel), mounted on a low-speed handpiece (MTI Dental, Coatesville, USA) to delimit the area to be treated. Subsequently, the specimens were cleaned in an ultrasonic bath (Quantrex<sup>®</sup> Q140; L&R Ultrasonics, Kearny, USA) with deionized water for 5 min and dried at room temperature.<sup>21</sup>

A diagram of the experimental design is shown in Fig. 1.

### Surface treatments

Eighty occlusal enamel samples were randomly assigned to 8 groups (10 per group). The samples were treated individually, as described below (Table 1).

**Sodium fluoride:** In this group, the samples were treated with a sodium fluoride (NaF) gel (Flor-Opal<sup>®</sup>; Ultradent Products, Inc., South Jordan, USA) at a concentration of 1.1% (5,457 ppm) for 4 min.

**CPP-ACPF:** In this group, the specimens were treated with a cream containing CPP-ACP and NaF (900 ppm) (MI Paste Plus; GC Corporation, Tokyo, Japan) for 4 min.

**Hydroxyapatite:** These samples were treated with a cream of HA, NaF (1,450 ppm) and xylitol (X) (Remin Pro<sup>®</sup>, Voco GmbH, Cuxhaven, Germany) for 4 min.

After the application of the mineralizing agents, the samples were rinsed with deionized water for 30 s and dried at room temperature.

Table 1. Treatments by study groups

Group	Treatment
Control	no treatment
NaF	sodium fluoride
CPP-ACPF	casein phosphopeptide-amorphous calcium phosphate with NaF
HA-NaF-X	hydroxyapatite-NaF-xylitol
L	Er:YAG (100 mJ, 12.7 J/cm <sup>2</sup> , 10 Hz)
L+NaF	Er:YAG (100 mJ, 12.7 J/cm <sup>2</sup> , 10 Hz)+NaF
L+CPP-ACPF	Er:YAG (100 mJ, 12.7 J/cm <sup>2</sup> , 10 Hz)+CPP-ACPF
L+HA-NaF-X	Er:YAG (100 mJ, 12.7 J/cm <sup>2</sup> , 10 Hz)+HA-NaF-X

Er:YAG – erbium-doped yttrium aluminum garnet laser.



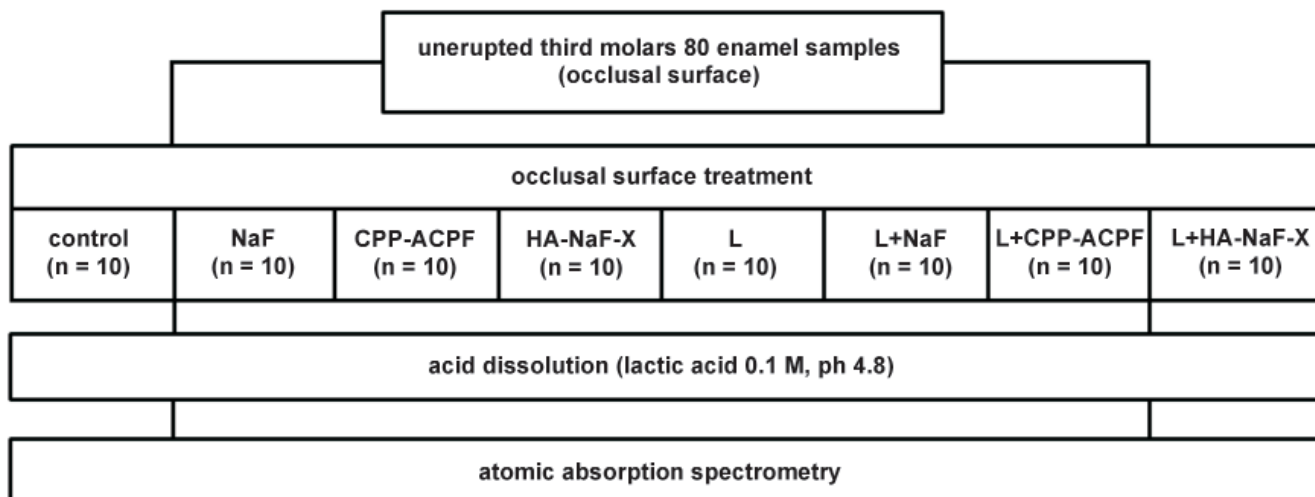


Fig. 1. Diagram of the experimental design

Er:YAG laser irradiation: The irradiation of the samples was carried out using an Er:YAG laser system (OpusDuo AquaLite® EC, Er:YAG+CO<sub>2</sub>; Lumenis Ltd., Yokneam, Israel). The laser parameters used were as follows: wavelength – 2.94 μm; pulse energy – 100 mJ (12.7 J/cm<sup>2</sup>); frequency – 10 Hz; pulse duration – 250–400 μs; and exit tip diameter – 1.0 mm. The energy level was calibrated using the calipers of the equipment and the energy delivered was measured periodically with a power meter (LaserMate®-P; Coherent, Inc., Santa Clara, USA). The dental surface was scanned manually with the sapphire tip of the laser perpendicular to it, at a working distance of 1 mm and with irrigation (distilled water 5 mL/min).<sup>15,18–21</sup> Each sample was irradiated only once for 20 s.

## Combined treatments

In these groups, the samples were irradiated with Er:YAG laser. Then, the respective remineralizing agents were applied using the same techniques described above.

## Acid dissolution

The samples were coated with an acid-resistant varnish, except the experimental area. Subsequently, all the samples were demineralized in 2 mL of 0.1 M lactic acid, pH 4.8, for 24 h in an incubator (Ikemoto Scientific Technology Co., Ltd., Tokyo, Japan) at 37°C and 100% humidity.

## Atomic absorption spectrometry

After acid dissolution, the samples were rinsed with deionized water to remove Ca residues from the tooth surface. The amount of Ca released from the samples

was obtained by atomic absorption spectrometry (atomic absorption spectrometer PU9100X; Philips NV, Amsterdam, the Netherlands).

## Statistical analysis

All the data was analyzed using the SPSS statistical package, v.19 (IBM SPSS, Armonk, USA). The Kolmogorov-Smirnov test was used to assess the data distribution and the one-way analysis of variance (ANOVA) test was used to analyze the differences between the groups. A p-value ≤0.05 was considered significant.

## Results

A lower Ca loss (in mg/L) was observed in the groups treated with NaF and L+NaF. The control group had the highest loss of Ca (in mg/L), followed by the HA-NaF-X group. The statistical analysis revealed no statistically significant differences among the groups (Table 2).

Table 2. Mean values and standard deviations (SD) of calcium (Ca) released by study groups

Group	Ca [mg/L]	p-value (ANOVA)
Control	21.93 (13.24)	0.346
NaF	15.27 (5.17)	
CPP-ACPF	20.67 (6.30)	
HA-NaF-X	21.13 (7.26)	
L	18.80 (5.45)	
L+NaF	15.20 (3.85)	
L+CPP-ACPF	17.00 (5.67)	
L+HA-NaF-X	17.07 (3.66)	

ANOVA – analysis of variance.

## Discussion

Pit-and-fissure caries remains the most common form of this disease,<sup>22</sup> and caries prevention on the occlusal surface continues to be a challenge in dentistry. There are a few reports regarding laser-combined protocols for caries prevention on the occlusal surface that have studied the effect of Nd:YAG+APF (acidulated phosphate fluoride) (1.23%),<sup>23</sup> CO<sub>2</sub>+NaF (5%),<sup>24</sup> and recently Er:YAG+fluoride with CPP-ACP.<sup>17</sup> For the present work, the occlusal enamel surfaces from third molars were selected to evaluate enamel acid resistance after the application of several remineralizing agents (NaF – 1.1%, CPP-ACPF – 900 ppm and HA-NaF-X – 1,450 ppm), Er:YAG laser and combined treatments.

Some studies have tested Er:YAG laser irradiation at lower energy densities and have shown significant inhibition of enamel demineralization.<sup>14,25</sup> This reduction has been attributed to the surface temperature achieved during enamel laser irradiation, and loss of water and carbonate.<sup>26</sup> In the current study, the selected parameters (low energy density – 12.7 J/cm<sup>2</sup>; pulse energy – 100 mJ; frequency – 10 Hz; pulse duration – 250–400 µs, and water irrigation – 5.0 mL/min) were based on previous studies<sup>16,21</sup> and the results of a pilot study.

Three remineralizing agents were chosen, with NaF representing fluoride as the keystone of caries prevention, which has been widely studied.<sup>5</sup> HA-NaF-X and CPP-ACPF were employed as alternative methods to fluoride.

Remin Pro (HA-NaF-X) was selected, because HA is an important biomaterial, a source of Ca and P. Remin Pro additionally promotes the remineralization of demineralized enamel areas,<sup>10</sup> since it contains xylitol, which assists in the remineralization of tooth enamel,<sup>27</sup> and also contains NaF (1,450 ppm).

MI Paste Plus<sup>TM</sup> (CPP-ACPF) was included in this study, because at an acidic pH CPP-ACP separates amorphous calcium phosphate (ACP) from casein phosphopeptide (CPP), thereby increasing salivary Ca and P levels, and promoting carious lesion remineralization.<sup>8</sup> Furthermore, it also contains NaF (900 ppm), whose fluoride ion can be exchanged with the hydroxyl group in the apatite crystal to form fluorapatite, which is a more stable and less soluble crystal.<sup>28</sup>

The groups treated with these remineralizing pastes showed no statistically significant differences in comparison with the control group. The reason could be that a single application of these remineralizing agents to the dental structure may not be enough to increase acid resistance. However, a 30% reduction in the loss of Ca content observed in the NaF and L+NaF groups in comparison with the control group could have clinical significance. Moreover, a previous study reported an increase in the Ca/P ratio under similar conditions for treatments with L+NaF, L+HA-NaF-X, L, and NaF, in decreasing order.<sup>21</sup>

However, Comar et al.<sup>11</sup> reported that fluoride paste (0.2% NaF) is still the best option for reducing dental demineralization *in vitro* when compared to HA, CPP-ACP and CPP-ACPF. The use of lasers in combination with CPP-ACPF and HA-NaF-X showed a superior performance, which was a promising result. The above-mentioned authors found that the reduction in released Ca, caused by the application of each of these remineralizing agents alone amounted to 5.75% and 3.65% respectively, while there was a reduction of 22% for the combined treatments in comparison with the control.

In the present study, Er:YAG laser irradiation as a single treatment had a lower preventive effect than in the NaF group and all the combined groups. Thus, under the conditions studied, it should be applied in combination with a remineralizing agent. Contrary to the results of this study, Díaz-Monroy et al. reported a higher resistance to acidic dissolution when the samples were irradiated at a density of 12.7 J/cm<sup>2</sup>, without using water to irrigate during irradiation.<sup>20</sup> Additionally, Cecchini et al. found that Er:YAG laser irradiation at lower energies can decrease enamel solubility without severe alterations of the tooth structure, even under the cooling effect of water flow.<sup>29</sup> Furthermore, Bevilacqua et al. concluded that Er:YAG laser irradiation combined with topical application of fluoride (APF gel) showed a beneficial effect on enamel acid resistance; they also reported that a higher energy density (31.84 J/cm<sup>2</sup>) resulted in a greater resistance to mineral loss.<sup>13</sup>

The findings of Liu et al. showed that a combination of NaF (2%/9,047 ppm) and Er:YAG laser (5.1 J/cm<sup>2</sup>) provided a higher preventive effect for human dental enamel, followed by laser irradiation (41.2%) and fluoride alone (28.9%), but the treatment conditions and evaluation techniques differed from those used in the current study.<sup>14</sup>

The results indicate that additional studies are required to deepen our knowledge of the insufficiently explored area of remineralizing agents in combination with Er:YAG laser. Evaluation of combined treatments in consecutive applications, as well as higher energy densities for Er:YAG laser irradiation, are suggested.

## Conclusions

A single application of NaF alone and the application of NaF+Er:YAG laser showed similar lower values of Ca released, compared to the control group, the groups treated with CPP-ACPF and HA-NaF-X with (i.e., control+laser, CPP-ACPF+laser and HA-NaF-X+laser) and without laser. These results could imply that a single NaF application and NaF+laser offer a superior resistance to the demineralization of dental enamel in comparison with the other treatments studied; however, the statistical analyses showed no statistically significant differences among the groups, so there is not enough statistical evidence to claim a superior acid resistance.

## References

- Berkovitz BKB, Moxham BJ, Linden RWA, Sloan AJ. *Master Dentistry Volume Three: Oral Biology*. 3<sup>rd</sup> ed. Beijing, China: Elsevier; 2011:142.
- West NX, Joiner A. Enamel mineral loss. *J Dent*. 2014;42s1:s2–s11.
- Featherstone JDB. Dental caries: A dynamic disease process. *Aust Dent J*. 2008;53(3):286–291.
- Splieth CH, Christiansen J, Foster Page LA. Caries epidemiology and community dentistry: Chances for future improvements in caries risk groups. Outcomes of the ORCA Saturday Afternoon Symposium, Greifswald, 2014. Part 1. *Caries Res*. 2016;50(1):9–16.
- Jones S, Burt BA, Petersen PE, Lennon MA. The effective use of fluorides in public health. *Bull World Health Organ*. 2005;83(9):670–676.
- Iijima Y, Cai F, Shen P, Walker G, Reynolds C, Reynolds EC. Acid resistance of enamel subsurface lesions remineralized by sugar-free chewing gum containing casein phosphopeptide-amorphous calcium phosphate. *Caries Res*. 2004;38(6):551–556.
- Kumar VLN, Itthagarum A, King NM. The effect of casein phosphopeptide-amorphous calcium phosphate on remineralization of artificial caries like lesions: An in vitro study. *Aust Dent J*. 2008;53(1):34–40.
- Reynolds EC. Casein phosphopeptide-amorphous calcium phosphate: The scientific evidence. *Adv Dent Res*. 2009;21(1):25–29.
- Tschoppe P, Zandim DL, Martus P, Kielbassa AM. Enamel and dentin remineralization by nano-hydroxyapatite toothpaste. *J Dent*. 2011;39(6):430–437.
- Gjorgievska ES, Nicholson JW, Slipper IJ, Stevanovic MM. Remineralization of demineralized enamel by toothpaste: A scanning electron microscopy, energy dispersive X-ray analysis, and three-dimensional stereo-micrographic study. *Microsc Microanal*. 2013;19(3):587–595.
- Comar LP, Souza BM, Gracindo LF, Buzalaf MA, Magalhães AC. Impact of experimental nano-HAP pastes on bovine enamel and dentin submitted to a pH cycling model. *Braz Dent J*. 2013;24(3):273–278.
- Ana PA, Bachmann L, Zezell DM. Lasers effects on enamel for caries prevention. *Laser Physics*. 2006;16(5):865–875.
- Bevilacqua FM, Zezell DM, Magnani R, da Ana PA, Eduardo Cde P. Fluoride uptake and acid resistance of enamel irradiated with Er:YAG laser. *Lasers Med Sci*. 2008;23(2):141–147.
- Liu Y, Hsu CY, Teo CM, Teoh SH. Potential mechanism for the laser-fluoride effect on enamel demineralization. *J Dent Res*. 2013;92(1):71–75.
- Zamudio-Ortega CM, Contreras-Bulnes R, Scougall-Vilchis RJ, et al. Morphological and chemical changes of deciduous enamel produced by Er:YAG laser, fluoride and combined treatment. *Photomed Laser Surg*. 2014;32(5):252–259.
- Curylofo-Zotti FA, Solano Tanta G, Zugliani AL, Milori Corona SA. The combined use of sodium fluoride and Er:YAG laser to control the progression of enamel caries. *Eur J Pharm Med Res*. 2016;3(9):1–5.
- Yassaei S, Shahraki N, Aghili H, Davari A. Combined effects of Er:YAG laser and casein phosphopeptide-amorphous calcium phosphate on the inhibition of enamel demineralization: An in vitro study. *Dent Res J (Isfahan)*. 2014;11(2):193–198.
- Rodríguez-Vilchis LE, Contreras-Bulnes R, Sánchez-Flores I, Samano EC. Acid resistance and structural changes of human dental enamel treated with Er:YAG. *Photomed Laser Surg*. 2010;28(2):207–211.
- Rodríguez-Vilchis LE, Contreras-Bulnes R, Olea-Mejía OF, Sánchez-Flores I, Centeno-Pedraza C. Morphological and structural changes on human dental enamel after Er:YAG laser irradiation: AFM SEM and EDS evaluation. *Photomed Laser Surg*. 2011;29(7):493–500.
- Diaz-Monroy JM, Contreras-Bulnes R, Olea-Mejía OF, et al. Chemical changes associated with increased acid resistance of Er:YAG laser irradiated enamel. *Sci World J*. 2014;2014:501357:1–6.
- Ceballos-Jiménez AY, Rodríguez-Vilchis LE, Contreras-Bulnes R, et al. Chemical changes of enamel produced by sodium fluoride, hydroxyapatite, Er:YAG laser, and combined treatments. *J Spectroscopy*. 2018;2018:1–7.
- Carvalho JC. Caries process on occlusal surfaces: Evolving evidence and understanding. *Caries Res*. 2014;48(4):339–346.
- Zezell DM, Boari HG, Ana PA, Eduardo Cde P, Powell GL. Nd:YAG laser in caries prevention: A clinical trial. *Lasers Surg Med*. 2009;41(1):31–35.
- Rechmann P, Charland DA, Rechmann BM, Le CQ, Featherstone JD. In-vivo occlusal caries prevention by pulsed CO<sub>2</sub>-laser and fluoride varnish treatment: A clinical pilot study. *Lasers Surg Med*. 2013;45(5):302–310.
- Liu Y, Hsu CY, Teo CM, Teoh SH. Subablative Er:YAG laser effect on enamel demineralization. *Caries Res*. 2013;47(1):63–68.
- Nelson DGA, Wefel JS, Jongebloed WL, Featherstone JD. Morphology, histology and crystallography of human dental enamel treated with pulsed low-energy infrared laser radiation. *Caries Res*. 1987;21(5):411–426.
- Mäkinen KK. Sugar alcohols, caries incidence, and remineralization of caries lesions: A literature review. *Int J Dent*. 2010;2010:1–23.
- Venkatesan K, Ranjan M. Remineralizing agents in dentistry: A review. *J Dent Med Sci*. 2014;13:57–60.
- Cecchini RC, Zezell DM, de Oliveira E, de Freitas PM, Eduardo Cde P. Effect of Er:YAG laser on enamel acid resistance: Morphological and atomic spectrometry analysis. *Laser Surg Med*. 2005;37(5):366–372.



# Evaluating the microleakage between dentin and composite materials

## Ocenianie mikroprzecieku pomiędzy zębina a materiałami złożonymi

Alper Özdoğan<sup>1,B,D–F</sup>, Musa Şamil Akyl<sup>2,A,C,D</sup>, Zeynep Yeşil Duymuş<sup>3,C,E,F</sup>

<sup>1</sup> Department of Prosthodontics, Faculty of Dentistry, Atatürk University, Erzurum, Turkey

<sup>2</sup> Department of Prosthodontics, Faculty of Dentistry, Adnan Menderes University, Aydın, Turkey

<sup>3</sup> Department of Prosthodontics, Faculty of Dentistry, Recep Tayyip Erdoğan University, Rize, Turkey

A – research concept and design; B – collection and/or assembly of data; C – data analysis and interpretation;

D – writing the article; E – critical revision of the article; F – final approval of the article

Dental and Medical Problems, ISSN 1644-387X (print), ISSN 2300-9020 (online)

*Dent Med Probl.* 2018;55(3):261–265

### Address for correspondence

Alper Özdoğan

E-mail: alprozdgn@gmail.com

### Funding sources

None declared

### Conflict of interest

None declared

### Acknowledgements

This study was presented as a poster at the 10<sup>th</sup> International Congress of the Academy of Prosthodontics and Gnathological Society, Antakya, Turkey, April 2012.

Received on January 22, 2018

Reviewed on May 22, 2018

Accepted on May 28, 2018

## Abstract

**Background.** For successful restoration, it is necessary to minimize the microleakage between dentin and the composite material.

**Objectives.** The purpose of this study was to evaluate the microleakage of 2 different resin cements (self-adhesive and conventional) on dentin treated with acid, sodium hypochlorite (NaOCl), the acid–NaOCl mixture, the erbium-doped yttrium aluminum garnet (Er:YAG) laser, and their combination.

**Material and methods.** Seventy dentin specimens were divided into 7 groups ( $n = 10$ ) according to the surface treatment. Then, the specimens were divided into 2 subgroups ( $n = 35$ ) according to the resin cement used during cementation with prepared composite resin blocks  $5 \text{ mm} \times 11 \text{ mm} \times 3 \text{ mm}$ : self-adhesive resin cement or conventional resin cement. Microleakage was scored and recorded at the occlusal and gingival levels, along the resin–dentin interfaces. The data was analyzed with the use of univariate analysis of variance (two-way ANOVA) and the Kruskal–Wallis test for both resin subgroups.

**Results.** The obtained results revealed that self-adhesive resin cement and conventional resin cement showed similar microleakage. Etching with sodium hypochlorite, the Er:YAG laser, the acid–NaOCl mixture, and their combination resulted in microleakage comparable to that achieved in acid etching, which is the conventional method of surface treatment.

**Conclusions.** Microleakage exhibited by self-adhesive resin cement was similar as in the case of conventional resin cement.

**Key words:** dentistry, resin cement, composites

**Słowa kluczowe:** stomatologia, cement żywiczny, materiały złożone

### DOI

10.17219/dmp/92317

### Copyright

© 2018 by Wrocław Medical University  
and Polish Dental Society

This is an article distributed under the terms of the  
Creative Commons Attribution Non-Commercial License  
(<http://creativecommons.org/licenses/by-nc-nd/4.0/>)

## Introduction

In dental procedures, microleakage occurs while placing the restorative material in the cavity wall, and results in the passage of bacteria, oral liquids, molecules, ions, and air to the microspace.<sup>1</sup> A number of studies reported that microleakage was a major risk factor for postoperative sensitivity, secondary caries, pulpal necrosis, and pulpal inflammation.<sup>2–4</sup> Research aimed at identifying materials and methods to prevent microleakage is ongoing.<sup>5</sup> According to one study, laser technology can minimize microleakage in dentistry.<sup>6</sup> Other studies have reported that the erbium-doped yttrium aluminum garnet (Er:YAG) laser holds promise and that it could be safely used to remove hard dental tissue.<sup>7,8</sup>

Sodium hypochlorite (NaOCl) has long been used as a deproteinizing agent on dentin.<sup>9</sup> When NaOCl is used, collagen fibrils in dentin are dissolved and exposed. Accordingly, the intermediate surface stability increases.<sup>10</sup> Nassif et al. reported that applying equal volumes of the acid–NaOCl mixture was more effective than the conventional etching method.<sup>11</sup>

Self-adhesive cements are a new category of resin bonding cements; these cements feature new monomers, fillings and initiator technology.<sup>12</sup> A previous study reported that the use of traditional cements in etching, primer or bonding applications did not require for these cements to bond to dental tissues.<sup>13</sup>

The aim of this study was to investigate the levels of microleakage at the dentin–adhesive interface surface following various treatments (acids, NaOCl, the acid–NaOCl mixture, the Er:YAG laser, and the combinations of these modalities) and cementation with self-adhesive and conventional resin cements.

## Material and methods

The study sample consisted of 70 caries-free molar teeth. The teeth were collected after informed consent had been obtained according to the protocols approved by the review board of the Faculty of Dentistry of Atatürk University, Erzurum, Turkey. The teeth were stored in distilled water at 4°C until use. The teeth were cut by a diamond saw in the occluso-gingival direction, 3 mm below the occlusal surface and at the distance of 1 mm from the cemento-enamel junction under water cooling. The samples were then embedded in autopolymerized acrylic resin blocks using a teflon mold, in which the buccal surfaces were cut out. The buccal surfaces of the teeth were then cut by a diamond bur under water until the dentin of the teeth was reached (Fig. 1). The samples were divided into the following 7 groups (n = 10 in each group) according to the surface treatment applied:

- group 1: phosphoric acid (37%) was applied for 15 s, followed by washing with water; to avoid overdrying the surface, excess water was removed using absorbent paper;
- group 2: NaOCl (5.25%) was applied for 2 min, and the surface was then washed with water for 30 s; to avoid overdrying the surface, excess water was removed using absorbent paper;
- group 3: equal volumes of the acid and NaOCl (50% phosphoric acid and 50% NaOCl) was applied for 15 s, followed by washing with water; to avoid overdrying the surface, excess water was removed using absorbent paper;
- group 4: the Er:YAG laser (DEKA® Smart, Calenzano, Italy) at a wavelength of 2940 nm (output power – 3.2 W, length – 100 mJ, distance – 2 mm) was applied to the dentin surface for 40 s under water;
- group 5: the dentin surface was treated with the Er:YAG laser (as in group 4) and additionally, the surface was treated with phosphoric acid (37%) (as in group 1);

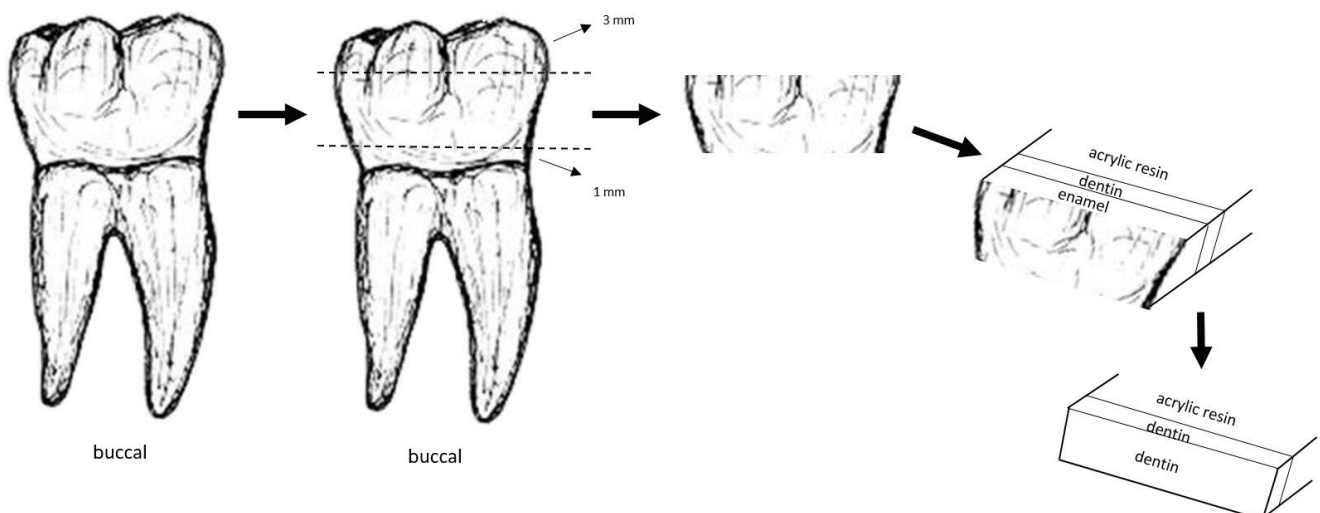


Fig. 1. The schematized tooth preparation

- group 6: the dentin surface was treated with the Er:YAG laser (as in group 4) and additionally, the surface was treated with NaOCl (as in group 2);
- group 7: the dentin surface was treated with the Er:YAG laser (as in group 4) and the acid–NaOCl mixture (as in group 3).

Cementation with resin cement was applied to the sample surfaces using composite blocks, with dimensions of 5 mm × 11 mm × 3 mm (thickness). The composite blocks were produced using a Plexiglas mold. The mold contained blanks of the same dimensions as the blocks. The composite resin (Quadrant Universal<sup>®</sup> LC; Cavex GmbH, Ofterdingen, Germany) was placed in 2 stages, 1.5 mm each time, in accordance with the manufacturer's instructions. At each stage, the surface was polymerized for 40 s using LED light. The cementation surfaces of the obtained blocks were polished using composite rubbers (Sof-Lex<sup>™</sup>; 3M, Maplewood, USA).

After the aforementioned surface treatments, the samples in each group were divided into 2 groups, depending on the type of resin cement (conventional dual-cure resin cement or self-adhesive dual-cure resin cement) used for cementation. In the conventional resin cement (CRC) group, the composite blocks were cemented to half of the samples (n = 35) using conventional dual-cure resin cement (Clearfil Esthetic<sup>®</sup> Cement; Kuraray Co., Ltd., Kurashiki, Japan). During cementation, additional acid etching was not applied to the dentin surface. All other cementation steps were applied according to the manufacturer's recommendations. In the self-adhesive resin cement (SARC) group, the composite blocks were cemented to half of the samples (n = 35) using self-adhesive dual-cure resin cement (Rely X U200; 3M). After the cementation of the composite blocks to the dentin surfaces, finger pressure was applied. To ensure standardization, the same researcher performed all the cementations. Residue cement was cleaned using a brush. The resin cement was polymerized from different directions using LED light for a total of 40 s.

## Evaluation of microleakage

Two consecutive layers of nail varnish were applied to the entire surfaces of the dentin, approx. 1 mm from the bonding area of the composite–dentin interface. The samples were then immersed in 0.5% basic fuchsin solution (Basic Violet 14; Changzhou Xincheng Weiye Chemical Co., Ltd., Changzhou, China) for 24 h at room temperature. Next, the samples were pulled out from the solution, washed with water and dried. Then, they were sectioned into slices using a diamond saw in the bucco-lingual direction under water. Each cut surface was examined under a stereomicroscope (Novex RZ; Euromex, Amsterdam, the Netherlands) at ×40 magnification. Microleakage at the dentin–adhesive interface surface was examined only at the occlu-

sal and gingival levels. The level of microleakage was scored as follows<sup>14</sup>:

- 0 point: no dye penetration (Fig. 2);
- 1 point: limited penetration (1 mm);
- 2 points: penetration into the dentin–adhesive interface surface at the depth of 2 mm;
- 3 points: penetration into the dentin–adhesive interface surface at the depth of 3 mm.

## Statistical analysis

The statistical analyses of the obtained data were performed using a two-way analysis of variance (ANOVA) and the Kruskal–Wallis test. A p-value <0.05 was considered significant.




Fig. 2. No dye penetration of the bonding surface

## Results

The mean microleakage results are shown in Table 1 and the dye penetration data is presented in Fig 3. The results of the two-way ANOVA and Kruskal–Wallis test revealed no statistically significant differences between the resin cement and surface treatment groups (p > 0.05). The highest microleakage mean score (0.80) at the dentin–adhesive interface surface was obtained in the group treated with CRC and the Er:YAG laser. The lowest mean microleakage score (0.28) at the dentin–adhesive interface surface was obtained in the group treated with the acid–NaOCl mixture and SARC. The results of the microscopic examination revealed no marked difference in dye penetration between the groups. These findings suggested that there was no statistically significant difference between the groups.

Table 1. The mean score of microleakage

Surface treatment	Resin cement	Microleakage score	
		mean	±SD
Group 1 (acid)	CRC	0.50	±0.53
	SARC	0.62	±0.52
Group 2 (NaOCl)	CRC	0.62	±0.52
	SARC	0.75	±0.46
Group 3 (acid–NaOCl)	CRC	0.62	±0.92
	SARC	0.28	±0.49
Group 4 (Er:YAG)	CRC	0.80	±0.42
	SARC	0.62	±0.52
Group 5 (Er:YAG+acid)	CRC	0.62	±0.92
	SARC	0.75	±0.89
Group 6 (Er:YAG+NaOCl)	CRC	0.29	±0.46
	SARC	0.62	±0.74
Group 7 (Er:YAG+acid–NaOCl)	CRC	0.75	±0.71
	SARC	0.75	±0.71

Er:YAG – erbium-doped yttrium aluminum garnet laser; CRC – conventional resin cement; SARC – self-adhesive resin cement; SD – standard deviation.




Fig. 3. Dye penetration of the bonding surface

## Discussion

The results of the present study indicated that microleakage following etching with NaOCl, the Er:YAG laser, the acid–NaOCl mixture, and the combinations of these modalities was similar to that obtained using conventional acid etching surface treatment methods.

In the case when collagen fibrils are not exposed, NaOCl is commonly applied after acid etching to protect the dentin bonding interface.<sup>9,11,15</sup> In the present study, the effect

of NaOCl was examined independently of acid etching, and microleakage scores were determined after both CRC and SARC acid etching. The acid–NaOCl mixture seems to modify the exposed collagen by removing the ‘collagen smear layer’, and this leads to the formation of a stable connection interface, thereby reducing microleakage.<sup>11</sup> The acidic nature of SARC may have contributed to increased stability of bonding. It can be explained by the minimal average microleakage obtained in this research in the case of the SARC samples treated with the acid–NaOCl mixture.

Previous studies reported discordant effects of laser applications on microleakage. Although Obeidi et al. reported that application of the neodymium-doped yttrium aluminum garnet (Nd:YAG) laser reduced the amount of microleakage, Navarro et al. and Aranha et al. both reported that laser application did not affect microleakage.<sup>16–18</sup> According to previous research, an output power of more than 2 W was appropriate for the dentin surface.<sup>19</sup> The Er:YAG laser used in the present study had an output power of 3.2 W, and the level of microleakage was similar to that obtained using conventional acid. Thus, based on the findings of the present study, the laser application did not influence the level of microleakage.

The results obtained in this study suggest that the acid–NaOCl mixture appears to be sufficient to reduce microleakage. Additional surface treatments had no effect on reducing leakage at the dentin–composite interface. Although the findings were not statistically significant, further modification studies of the acid–NaOCl combination may be considered. Future research could also evaluate the effect of different restorative materials treated with acids and agents of different chemical content on microleakage between dentin and restorative materials.

## Conclusions

Within the limitations of this study, microleakage at the dentin–resin cement interface can be reduced using the acid–NaOCl mixture and SARC. The level of microleakage observed using SARC was similar to that obtained using CRC. The levels of microleakage observed following the application of NaOCl, the Er:YAG laser, the acid–NaOCl mixture, and the combinations of these modalities were similar.

## References

1. Perdigao J, Swift EJ. Fundamental concept of enamel and dentin adhesion. In: Roberson T, Heymann HO, Swift EJ Jr., eds. *Sturdevant's Art and Science of Operative Dentistry*. St. Louis, MO: Mosby, Inc.; 2006:130.
2. Murray PE, Hafez AA, Smith AJ, Cox CF. Bacterial microleakage and pulp inflammation associated with various restorative materials. *Dent Mater*. 2002;18(6):470–478.
3. Türkün M, Türkün LS, Kalender A. Effect of cavity disinfectants on the sealing ability of nonrinsing dentin-bonding resins. *Quintessence Int*. 2004;35(6):469–476.



4. Brännström M. The cause of postrestorative sensitivity and its prevention. *J Endod.* 1986;12(10):475–481.
5. Akin H, Tugut F, Akin GE, Guney U, Mutaf B. Effect of Er:YAG laser application on the shear bond strength and microleakage between resin cements and Y-TZP ceramics. *Lasers Med Sci.* 2012;27(2):333–338.
6. Siso HS, Kustarci A, Göktolga EG. Microleakage in resin composite restorations after antimicrobial pre-treatments: Effect of KTP laser, chlorhexidine gluconate and Clearfil Protect Bond. *Oper Dent.* 2009;34(3):321–327.
7. Hibst R, Keller U. Experimental studies of the application of the Er:YAG laser on dental hard substances: I. Measurement of the ablation rate. *Lasers Surg Med.* 1989;9(4):338–344.
8. Brulat N, Leforestier E, Rocca JP, Darquet-Cerretti E, Bertrand MF. Shear bond strength of self-etching adhesive systems to Er:YAG laser-prepared dentine with and without pulpal pressure simulation. *Photomed Laser Surg.* 2008;26(6):579–583.
9. Sano H, Yoshikawa T, Pereira PN, et al. Long-term durability of dentin bonds made with a self-etching primer, in vivo. *J Dent Res.* 1999;78(4):906–911.
10. Baseggio W, Consolmagno EC, de Carvalho FL, et al. Effect of deproteinization and tubular occlusion on microtensile bond strength and marginal microleakage of resin composite restorations. *J Appl Oral Sci.* 2009;17(5):462–466.
11. Nassif MS, El-Korashy DI. Phosphoric acid/sodium hypochlorite mixture as dentin conditioner: A new approach. *J Adhes Dent.* 2009;11(6):455–460.
12. Radovic I, Monticelli F, Goracci C, Vulcic ZR, Ferrari M. Self-adhesive resin cements: A literature review. *J Adhes Dent.* 2008;10(4):251–258.
13. Gerth HU, Dammaschke T, Züchner H, Schäfer E. Chemical analysis and bonding reaction of RelyX Unicem and Bifix composites – a comparative study. *Dent Mater.* 2006;22(10):934–941.
14. Arhun N, Arman A, Cehreli SB, Arikan S, Karabulut E, Gülşahi K. Microleakage beneath ceramic and metal brackets bonded with a conventional and an antibacterial adhesive system. *Angle Orthod.* 2006;76(6):1028–1034.
15. Inoue S, Murata Y, Sano H, Kashiwada T. Effect of NaOCl treatment on bond strength between indirect resin core-buildup and dentin. *Dent Mater J.* 2002;21(4):343–354.
16. Obeidi A, Ghasemi A, Azima A, Ansari G. Effects of pulsed Nd:YAG laser on microleakage of composite restorations in class V cavities. *Photomed Laser Surg.* 2005;23(1):56–59.
17. Navarro RS, Gouw-Soares S, Cassoni A, Haypek P, Zezell DM, de Paula Eduardo C. The influence of erbium:yttrium-aluminum-garnet laser ablation with variable pulse width on morphology and microleakage of composite restorations. *Lasers Med Sci.* 2010;25(6):881–889.
18. Aranha AC, Turbino ML, Powell GL, Eduardo Cde P. Assessing microleakage of class V resin composite restorations after Er:YAG laser and bur preparation. *Lasers Surg Med.* 2005;37(2):172–177.
19. Capa N, Aykor A, Ozel E, Calikkocaoglu S, Soyman M. Effect of Er:YAG laser irradiations on shear bond strength of three self-adhesive resin cements to dentin. *Photomed Laser Surg.* 2010;28(6):809–821.



# Evaluation of the gray level of restorative materials using cone-beam computed tomography: A cross-sectional study

## Ocena poziomu szarości materiałów stomatologicznych w tomografii stożkowej – badanie przekrojowe

Pezhman Hadadi<sup>1,A</sup>, Farzane Ostovarrad<sup>2,B</sup>, Ava Nikbin<sup>2,D–F</sup>, Hadi Ranjzad<sup>3,B</sup>, Farzane Ghasemi<sup>4,B</sup>, Somayeh Nemati<sup>2,B</sup>

<sup>1</sup> Department of Oral and Maxillofacial Radiology, Faculty of Dentistry, Guilan University of Medical Sciences, Anzali, Iran

<sup>2</sup> Department of Oral and Maxillofacial Radiology, Faculty of Dentistry, Guilan University of Medical Sciences, Rasht, Iran

<sup>3</sup> Department of Prosthodontics, Faculty of Dentistry, Guilan University of Medical Sciences, Anzali, Iran

<sup>4</sup> Faculty of Dentistry, Guilan University of Medical Sciences, Rasht, Iran

A – research concept and design; B – collection and/or assembly of data; C – data analysis and interpretation; D – writing the article; E – critical revision of the article; F – final approval of the article

Dental and Medical Problems, ISSN 1644-387X (print), ISSN 2300-9020 (online)

*Dent Med Probl.* 2018;55(3):267–274

### Address for correspondence

Ava Nikbin

E-mail: nikbinava@yahoo.com

### Funding sources

None declared

### Conflict of interest

None declared

### Acknowledgements

We would like to thank the employees of Ayatollah Rouhani Hospital, Iran, especially Dr. Mahdi Rahmani, for their cooperation.

Received on April 4, 2018

Reviewed on July 3, 2018

Accepted on July 18, 2018

### DOI

10.17219/dmp/93569

### Copyright

© 2018 by Wrocław Medical University  
and Polish Dental Society

This is an article distributed under the terms of the  
Creative Commons Attribution Non-Commercial License  
(<http://creativecommons.org/licenses/by-nc-nd/4.0/>)

## Abstract

**Background.** Densitometry plays an important role in the diagnosis of different types of dental materials and treatment planning. Due to diversity in density, equal amounts of different materials absorb various amounts of X-rays and yield different radiographic views.

**Objectives.** The aim of this study was to evaluate the gray scales of 5 commercially available restorative materials, including amalgam, composite resin, flowable composite resin, glass-ionomer, and Dycal.

**Material and methods.** Samples of the 5 test materials from various manufacturers were prepared, each 5-millimeter-thick. There were 7 glass-ionomer samples and 10 of each of the other materials, making a total of 47 samples in the study. The test materials were scanned using a Kodak cone-beam computed tomography (CBCT) unit. Subsequently, the gray scales were determined and evaluated by a radiologist using OnDemand3D™ Dental software and analyzed with SPSS v. 22 software.

**Results.** Amalgam had a higher gray scale than the other groups of restorative materials. In some cases, it was the same as that of composite resin; however, it was significantly different from gray scales of flowable composite resin, glass-ionomer and Dycal. It was concluded that composite resin and amalgam were high in gray scale, while flowable composite resin, glass-ionomer and Dycal exhibited low gray scales.

**Conclusions.** Amalgam and composite resin had high gray scales, and glass-ionomer and Dycal exhibited the lowest gray scale values. The findings show that CBCT can be helpful in differentiating amalgam and composite resin from other materials.

**Key words:** cone-beam computed tomography, dental materials, densitometry

**Słowa kluczowe:** stożkowa tomografia komputerowa, materiały dentystyczne, densytometria

## Introduction

One of the main issues playing an important role in the assessment of different dental materials and in treatment planning is densitometry. For example, distinguishing the density of bone undeniably affects the success of dental implants.<sup>1</sup> In addition, in the case of maxillofacial trauma or a foreign body suspected in the surrounding soft tissue, densitometry can be used to determine the kind of the foreign body, which might be a restorative material. Densitometry is also useful while distinguishing restorative materials used in older treatment plans from each other and from the recent ones, which can be of great importance in dental treatment planning.<sup>2,3</sup> Equal amounts of different materials, due to differences in their atomic number and density, result in differences in the attenuation of X-rays. As a result, they have different radiographic projections even on plain films. Therefore, given the density of any material, its nature can be determined through radiography.<sup>4</sup> Denser materials have less space in their crystal networks and their molecules are highly compressed. These substances absorb much more X-ray radiation when they are exposed to X-rays, since they have more atoms and more electrons.<sup>5,6</sup>

X-rays are used to produce images from opaque materials based on the relationship between the density and X-ray absorption of different materials.<sup>7</sup> Different techniques, such as computed tomography (CT) and cone-beam computed tomography (CBCT) can be used.

In the CT technique, one number is assigned to each pixel displaying the images and this shows the rate of attenuation of rays by each tissue. Computed tomography numbers are known as Hounsfield units (HU). In 1978, this technique was introduced in bone densitometry. Various studies have recognized CT as the gold standard for tissue densitometry.<sup>8</sup>

The CBCT technique is of great importance in head and neck traumas. In recent years, CBCT has also been used as a critical diagnostic tool in dentistry<sup>9-13</sup> and it is an innovative technique in scanning and data reconstruction. Cone-beam computed tomography is widely used for 3-dimensional and multiplanar images. Compared to CT, this method can provide detailed images – up to sub-millimeter resolution – in a shorter time and at a lower dosage; in addition, it is more affordable for patients. However, CBCT has shortcomings as well. The quality of reconstructed CBCT images is affected by noise, beam hardening, the cone-beam effect and photon starvation. These effects result in the formation of different types of artifacts, such as bright streaks of radiation, dark areas adjacent to metal objects or even a complete loss of gray shadows between adjacent metal objects. Beam hardening results from the preferential absorption of lower-energy photons in a heterogeneous X-ray beam. As opposed to rectangular objects, in spherical and cylindrical objects, like the skull and implants, the distance through

the center is longer than a path closer to the surface, the central area can appear as a dark area with a decreased CT number (HU) in the middle of axial cuts.<sup>14</sup> Nevertheless, recent research shows that by analyzing gray scales, CBCT can determine HU of tissues and, as a result, the densities of different bones.<sup>14,15</sup> There are limited studies on the use of CBCT to determine the density of restorative materials.<sup>15</sup>

The aim of this study was to evaluate the gray levels of materials in restorative dentistry, using CBCT in standard exposure, which could help to assess the materials, and thus improve treatment planning.

## Material and methods

This pilot study is one of the first studies on evaluating the gray levels of dental restorative materials with the use of the CBCT technique. Each group of substances consisted of 10 different products from various manufacturers, except for the glass-ionomer group, which included 7 samples, making a total of 47 samples of restorative materials evaluated in 5 groups.

The technical specifications of the 5 substances, commonly used in restorative dentistry, evaluated in this study are as follows:

- amalgam: A – ANA 2000® (Nordiska Dental, Ängelholm, Sweden); B – GS-80® (SDI, Itasca, USA); C – Cinalux® (Shahid Faghihi, Tehran, Iran); D – GK® (AT&M Biomaterials, Beijing, China); E – GK-110® (AT&M Biomaterials); F – Wykalloy® (Prestige Dental Products, Anaheim, USA); G – Aristaloy 21® (Lavadent, London, UK); H – World Work Powder Alloy® (World Work, Montebello Vicentino, Italy); I – Contour® (Kerr, Orange, USA); J – 110-Plus® (Anas Dental Supplies, Damascus, Syria);
- composite resin: A – SDI Luna® (SDI, Itasca, USA); B – Coltene-Synergy® (Coltene Whaledent Inc., Cuyahoga Falls, USA); C – Filtek Z250-XT® (3M, Seefeld, Germany); D – Opallis® (FGM, Joinville, Brazil); E – Bisco-Aelite Aesthetic Enamel® (Bisco, Schaumburg, USA); F – Estelite Sigma Quick® (Tokuyama, Tokyo, Japan); G – Shofu-Beautiful II® (Shofu, Kyoto, Japan); H – Denfil® (Vericom, Anyang, South Korea); I – Diafil® (Diadent, Cheongju, South Korea); J – Charmfil Plus® (Dentkist, Seoul, South Korea);
- flowable composite resin: A – Denfil Flow® (Vericom); B – Diafil Flow® (Diadent); C – Denu Flow Resin® (HDI-Denu, Seoul, South Korea); D – Permaflo Pink® (Ultra Dent, South Jordan, USA); E – Clearfil AP-X Flow® (Kuraray, Chicago, USA); F – Opallis Flow® (FGM); G – Heliomolar Flow® (Ivoclar Vivadent, Mississauga, Canada); H – Tetric N-flow® (Ivoclar Vivadent, Mumbai, India); I – Wave® (SDI, Itasca, USA); J – Filtek Z350-XT® (3M);
- glass-ionomer: A – Riva Luting® (SDI, Bayswater, Australia); B – GC Fuji I® (GC, Tokyo, Japan); C – Tokuso Ion-omer® (Tokuyama); D – Chemfil Superior® (Dentsply,

Tulsa, USA); E – Ionoseal® (VOCO, Cuxhaven, Germany); F – Iono Cid-LC® (FSDS, Greenock, Canada); G – Glass Liner® (WP Dental, Barmstedt, Germany); – Dycal: A – ACTIVA Bioactive-base/liner® (Pulpdent Corporation, Watertown, USA); B – Dycal Ivory® (Dentsply); C – ANA Liner® (Nordiska Dental, Ängelholm, Sweden); D – Biner-LC® (Meta Biomed, Cheongju, South Korea); E – Hidrox-Cal® (Maquira, Maringá, Brazil); F – Theracal LC® (Bisco); G – Ionosit-Baseliner® (DMG Chemisch-Pharmazeutische, Hamburg, Germany); H – Master Dent Cavity Liner® (Master Dent, Garden Grove, USA); I – Ultra Blend Plus® (Ultra Dent, South Jordan, USA); J – Charmfil Flow® (Dentkist).

To prepare the test set, a cardboard grid measuring  $135 \times 60 \times 1$  mm was selected and a collection of cubes with the same size ( $5 \times 5 \times 5$  mm) was made of it (Fig. 1). The rows show the material types used and the columns show the manufacturers. Each material was placed in one of the cubes and the samples were prepared for final setting according to the same clinical procedure. The preparation procedures were as follows: amalgam samples were packed using a condenser, and composite resin samples were light-cured layer by layer; to light-cure flowable composite resin, glass-ionomer and Dycal, a light-curing unit was used (Fig. 2).

After the final setting, the restorative materials were separated from the cardboard grid and each group of materials was laid on a separate sheet. The composite resin, flowable composite resin, glass-ionomer, and Dycal samples were placed on 4 separate cardboards with a distance of 1.5 cm between them (Fig. 3). For the amalgam samples, a little more space was left between them (about 2 cm) due to artifacts made by amalgam during image acquisition (Fig. 4). It should be pointed out that there was a limitation to the cardboard sheet size, since a larger size would have been out of the field of view of the CBCT system. In addition, since the space between the amalgam samples was more than that between other materials, each sample had to be scanned separately.



Fig. 1. A cardboard grid fabricated for the placement of the restorative materials



Fig. 2. Squares of the cardboard grid filled with the restorative materials




Fig. 3. A – composite resin; B – flowable composite resin; C – glass-ionomer; D – Dycal cubes attached to the cardboard sheet with a distance of 1.5 cm between them




Fig. 4. Amalgam cubes attached to the cardboard sheet with a distance of 2 cm between them

Each cardboard sheet holding 1 of the restorative materials was exposed to a CBCT system (Kodak CBCT, Carestream Company, Rochester, USA) under standard exposure conditions (MA = 6.3, kVp = 73, voxel = 180). The acquired images were analyzed by an experienced radiologist in a horizontal view, using OnDemand3D™ Dental software (Cybermed, Seoul, South Korea) and the gray scale of each sample was recorded by determining the mean, min and max values at the center of the sample (Fig. 5,6).

The gray levels were determined at the center of the samples to minimize the artifact effect. It should be pointed out that cubic and homogeneous samples were used in the present study to eliminate the beam-hardening effect, which is a problem in spherical, cylindrical and non-homogeneous samples. The samples were completely identical and the artifact effect, if any, would affect them all similarly.

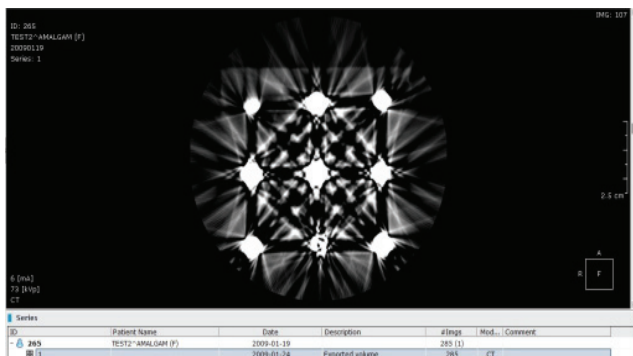


Fig. 5. The cone-beam computed tomography (CBCT) image of amalgam cubes scanned by a Kodak CBCT system

The data was recorded in checklists and analyzed with SPSS v. 22 software (IBM Corp., Armonk, USA). The gray scale was evaluated using means and standard deviations (SDs) at a 95% confidence interval (CI), separately for each dental material under standard exposure conditions. An analysis of variance (ANOVA) was used to compare the means of gray scales in the dental materials under exposure conditions and between different materials. Post-hoc Tukey's tests were used for two-by-two comparisons of the mean gray scale values of the dental materials. In the cases when the gray scale data was not normally distributed, corresponding non-parametric tests were used. Statistical significance was set at  $p < 0.05$ .

## Results

The data in Table 1 shows that the highest min gray scale value among the samples in the study was exhibited by amalgam ( $10,160.20 \pm 1,766.53$ ; 95% CI: 8,896.50–11,423.90). Dycal exhibited the lowest min gray scale value among the restorative materials in the study ( $4,861.00 \pm 1,159.35$ ; 95% CI: 4,031.65–5,690.35). Based on a one-way ANOVA, the 5 restorative materials in the study showed significant differences in the min gray scale values ( $p = 0.001$ ).

The data in Table 1 shows that the highest max gray scale value was exhibited by amalgam ( $14,554.1 \pm 2927.9$ ; 95% CI: 12,459.63–16,648.57). The lowest max gray scale value belonged to glass-ionomer ( $8,192.29 \pm 4,172.52$ ; 95% CI: 4,333.34–12,051.23), indicating a significant difference in the max gray scale values based on a one-way ANOVA ( $p = 0.001$ ).




Fig. 6. The cone-beam computed tomography (CBCT) images of: A – composite resin; B – flowable composite resin; C – glass-ionomer; D – Dycal cubes, scanned by a Kodak CBCT system

**Table 1.** Comparison of the min and max gray scale values in 5 restorative materials

Types of dental materials		n	Descriptives						p-value
			mean	SD	95% CI		min	max	
					lower bound	upper bound			
Min	amalgam	10	10,160.20	1,766.53	8,896.50	11,423.90	7,703.00	13,193.00	0.001
	composite	10	7,248.90	2,690.49	5,324.24	9,173.56	2,839.00	11,188.00	
	composite flow	10	6,491.40	3,279.22	4,145.59	8,837.21	1,723.00	10,544.00	
	glass-ionomer	7	6,248.14	3,582.88	2,934.53	9,561.75	232.00	9,639.00	
	Dycal	10	4,861.00	1,159.35	4,031.65	5,690.35	2,864.00	6,494.00	
Max	amalgam	10	14,554.10	2,927.87	12,459.63	16,648.57	10,474.00	19,335.00	0.001
	composite	10	9,306.00	3,017.59	7,147.35	11,464.65	4,263.00	14,888.00	
	composite flow	10	9,457.30	4,713.73	6,085.30	12,829.30	4,476.00	18,368.00	
	glass-ionomer	7	8,192.29	4,172.52	4,333.34	12,051.23	1,906.00	14,798.00	
	Dycal	10	8,269.60	2,081.21	6,780.80	9,758.40	5,816.00	12,905.00	
Mean	amalgam	10	11,253.70	1,706.37	10,033.03	12,474.37	8,433.00	13,765.00	0.009
	composite	10	8,217.50	2,768.59	6,236.97	10,198.03	3,644.00	12,503.00	
	composite flow	10	7,713.10	3,698.44	5,067.39	10,358.81	2,660.00	12,286.00	
	glass-ionomer	7	7,252.57	3,835.23	3,705.57	10,799.57	1,276.00	12,583.00	
	Dycal	10	6,692.80	1,837.25	5,378.51	8,007.09	4,145.00	10,927.00	

SD – standard deviation; CI – confidence interval.

The analysis of the mean gray scale values of the restorative materials (Table 1) shows that the highest value was displayed by amalgam (11,253.7 ±1706.37; 95% CI: 10,033.03–12,474.37). The lowest mean gray scale value was found in Dycal (6,692.80 ±1,837.25; 95% CI: 5,378.51–8,007.09), indicating a statistically significant difference in the mean gray scale values among the 5 restorative materials in this study based on a one-way ANOVA ( $p = 0.009$ ).

Post-hoc Tukey's tests were used to compare the min, max and mean gray scale values. Using pair-wise analyses of the restorative materials, it was concluded that the min value of amalgam was significantly different from all

the other materials except for composite resin. It is worth noting that flowable composite resin exhibited a borderline significant difference from amalgam in the min gray scale value.

Regarding the gray scale max value, in pair-wise comparisons of the restorative materials, amalgam exhibited the following statistically significant differences from the other materials: composite resin ( $p = 0.013$ ), flowable composite resin ( $p = 0.016$ ), glass-ionomer ( $p = 0.005$ ), and Dycal ( $p = 0.002$ ). Amalgam had the highest max gray scale value of all the materials. Other materials, however, did not show a statistically significant difference in the above test ( $p > 0.05$ ).

**Table 2.** The min, max and mean gray scale values in different brands of 5 restorative materials

Brands*	Type of dental material														
	amalgam			composite			flowable composite			glass-ionomer			Dycal		
	min	max	mean	min	max	mean	min	max	mean	min	max	mean	min	max	mean
A	11,435	16,427	12,521	2,839	4,263	3,644	3,809	5,418	4,907	4,031	5,440	4,785	6,494	8,883	7,368
B	11,264	19,335	12,703	7,491	9,497	8,498	9,052	10,567	9,552	5,690	6,924	6,243	5,401	7,148	6,144
C	11,838	19,011	13,207	6,342	7,897	7,091	6,891	7,961	7,359	9,602	14,798	12,583	4,888	6,832	5,931
D	9,220	12,069	10,150	10,313	11,613	10,972	10,434	13,687	11,563	232	1,906	1,276	4,804	12,905	10,927
E	9,591	12,326	10,425	6,731	9,479	7,975	7,851	18,368	12,286	9,639	10,670	10,034	5,297	9,802	5,940
F	9,849	13,837	10,801	4,397	6,298	5,237	8,318	12,103	10,061	9,591	10,422	9,970	5,008	7,689	6,381
G	7,771	13,955	9,842	6,416	8,484	7,386	2,601	4,510	3,325	4,952	7,186	5,877	2,864	5,816	4,145
H	9,738	13,115	10,690	10,415	12,082	11,456	10,544	12,318	11,293	–	–	–	6,050	7,618	6,663
I	13,193	14,992	13,765	6,357	8,559	7,413	3,691	4,476	4,125	–	–	–	4,819	6,498	5,308
J	7,703	10,474	8,433	11,188	14,888	12,503	1,723	5,165	2,660	–	–	–	2,985	9,505	8,121

\* The letters A–J represent different brands according to the description in section "Material and methods".

The results of pair-wise analyses of the mean gray scale values showed that amalgam was significantly different from glass-ionomer ( $p = 0.048$ ) and Dycal ( $p = 0.007$ ). The difference between amalgam and flowable composite resin was borderline significant ( $p = 0.057$ ), while the difference between amalgam and composite resin was not significant ( $p = 0.136$ ). Based on Tukey's honest significant difference (HSD) tests, the other restorative materials did not exhibit significant differences in the mean values in pair-wise comparisons.

Amalgam had higher min, max and mean gray scale values than the other restorative materials. It exhibited the same gray scale value as composite resin in some cases, but was significantly different from glass-ionomer, Dycal and flowable composite resin. It can be concluded that composite resin and amalgam were high in gray scale, and flowable composite, glass-ionomer and Dycal exhibited low gray scale.

Table 2 presents the min, max and mean gray scale values of the restorative materials in terms of their brands. The results show that among the amalgam samples, Kerr had the highest min and mean values, and SDI had the highest max gray scale value compared to the other brands.

Among the composite brands, Dentkist exhibited the highest min, max and mean gray scale values, and the lowest values belonged to SDI.

Among the flowable composite resins, the highest max and mean gray scale values belonged to Kuraray, and the highest min gray scale level was found in Ivoclar Vivadent, India. The lowest min and mean gray scale values belonged to 3M, and the lowest max gray level belonged to SDI.

Out of the 7 glass-ionomer brands, the highest max and mean gray scale values belonged to Tokuyama, and the lowest values were found in Dentsply.

In Dycal, the highest min gray scale value belonged to Pulpdent Corporation, and the lowest max, min and mean values belonged to DMG Chemisch-Pharmazeutische.

The min, max and mean gray scale values of different restorative materials in terms of their brands are presented in Fig 7–9.

The min gray scale value was higher in amalgams than in the other restorative materials. Glass-ionomer and Dycal had a lower value than the other restorative materials. Composite resin and flowable composite resin were in the middle of the range.

Among the amalgam samples, the max gray value belonged to SDI and the min value belonged to Anas Dental Supplies. Among the composite resins, the max was found in Dentkist and the min was noted in SDI. Flowable composite resins showed their max and min values in Kuraray and 3M, respectively. Glass-ionomer exhibited the max and min values in Tokuyama and Dentsply, respectively. Finally, in Dycal, the max and min gray scale values belonged to Meta Biomed and DMG Chemisch-Pharmazeutische, respectively.

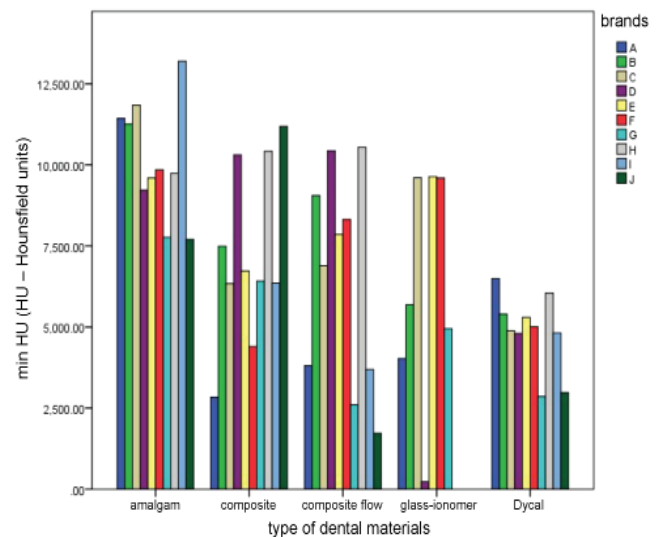


Fig. 7. Minimum gray scale values of restorative materials in relation to their brands

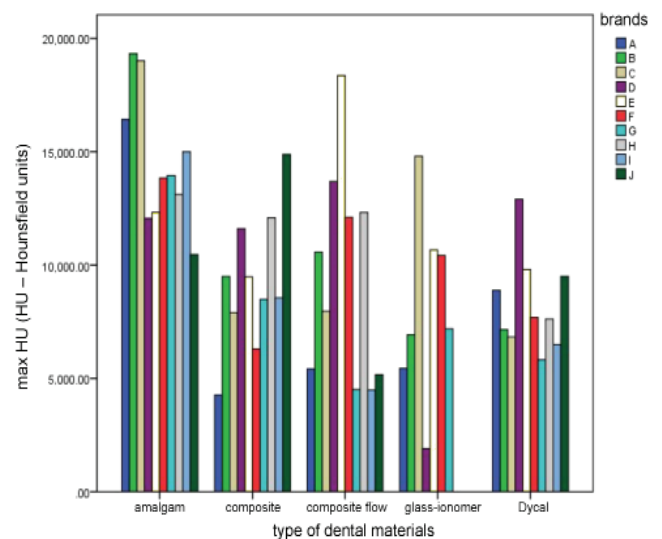


Fig. 8. Maximum gray scale values of restorative materials in relation to their brands

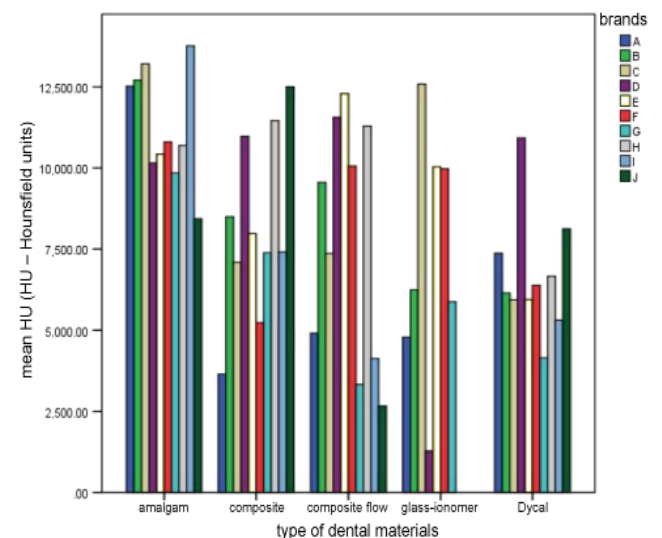


Fig. 9. Mean gray scale values of restorative materials in relation to their brands



## Discussion

Cone-beam computed tomography has been used as an important diagnostic tool in recent years.<sup>9–13</sup> It is an innovative method in scanning and image reconstruction. In this technique, materials with different densities, such as bone and soft tissue, can be differentiated based on their densitometry. Several studies have been conducted in this regard, but only a few have evaluated the density of restorative materials commonly used in dentistry.

Among these studies, Lachowski et al. analyzed the radiopacity of various dental materials (bases and liners).<sup>16</sup> They used digital intraoral radiography (Kodak; radiovisiography (RVG): 5000, 70 kVp, 7 mA, 0.32 s, 30-centimeter distance). As in the present study, Tetric N-flow was among the flowable composite resins. With a thickness of 3 mm, this material exhibited the highest gray scale. It had the second highest gray scale value in the present study, consistent with the results of the study by Lachowski et al. It must be pointed out that the gray scale value of a material is directly related to its density. Considering this and the results of the present study, in the category of flowable composite resins, the lowest gray scale value belonged to the most flowable one. The same cannot be said with certainty regarding glass-ionomers, because they are supplied as 2-part powder and liquid systems that require mixing, depending on their different therapeutic applications. Glass-ionomers are sometimes used in a creamy consistency to line dental caries, but in class V restorations on the root surface, they are used in a thicker consistency.

By scanning samples of different sizes, Lachowski et al. concluded that the thickness of the samples had a direct effect on the final radiography. Thicker samples had a greater amount of substance, and thus more X-ray attenuation was observed<sup>16</sup>. In the present study, all the samples for scanning were prepared in the same dimensions and their thickness was fixed at 5 mm. In addition, the sub-categories of each group of restorative materials were compared to each other in terms of the min and max gray scale values, with a direct relation between density and gray scale values resulting from the CBCT images.

Although intraoral digital imaging is less costly than CBCT, since it does not provide a value level as the output of the radiopacity analysis, the materials in the study by Lachowski et al. were measured with a single opaque item. In that study, the opacity of the materials in aluminum sheets of different thicknesses were evaluated. The ingredients of aluminum sheets vary and this affects their opacity. Furthermore, the opacity of the study samples, compared to the opaque aluminum sheet, was evaluated with the use of relative measurements.<sup>16</sup> However, in the present study, the CBCT technique was used to capture images, which had the advantage of higher resolution and accuracy compared to other imaging systems.

In another study, Devito et al. compared the radiopacity of 3 types of calcium hydroxide (Dycal, Hydro-C, Life) using digital radiography. They concluded that the radiopacity of the cement and enamel was equal to 2 mm of aluminum, but the radiopacity of the dentin was equal to 1 mm of aluminum. In that study, the lowest opacity belonged to Life.<sup>17</sup> In the present study, among the 10 different types of Dycal, the least opacity was noted for Ionosit-Baselinier and the highest for Biner-LC. Hidrox-Cal, which was assessed both in this study and in the study by Devito et al., was in the middle of the spectrum.

Pires de Souza et al. investigated the optical densities of calcium hydroxide and glass-ionomer, concluding that in order to assess the radiopacity of different materials, the min thickness of the samples must be approx. 1.5–2 mm.<sup>18</sup> In the present study, the thickness of each sample was 5 mm. It is consistent with the above-mentioned authors, who used intraoral radiography to examine the opacity of the materials.

In research conducted by Imperiano et al., intraoral radiography and materials of equal thickness ( $2 \times 10$  mm) were used to measure the density of different composite resin types. In that study, Natural Flow and Protect Liner F composite resins did not exhibit any specific opacity that would allow them to be differentiated from dental caries.<sup>19</sup> However, in the present study, none of the composite resins exhibited a significant difference from amalgam and all had the necessary opacity for differentiation from the tooth structure. This discrepancy between the results of studies might be attributed to differences in research methods. In addition, none of the brands evaluated in the present study was used in the study by Imperiano et al.

Factors affecting the results obtained from CBCT include the scanning conditions and the type of device.<sup>4,8,20,21</sup> Therefore, to determine the gray scale of different restorative dental materials, a single CBCT device was used.

As discussed above, in the CT technique one number is assigned to each pixel, which indicates the amount of radiation attenuated by the studied tissue.<sup>8</sup> This is one of the differences between CT and CBCT, and the lack of real HU (as in CT) is a disadvantage of CBCT. Mah et al. examined the different structures of 11 dental CBCT units and 2 medical CT systems. The results showed that there was a high correlation between HU in CT and the gray scale in CBCT.<sup>21</sup> In the present study, CBCT was used instead of CT due to its greater advantages, such as low-dose radiation, high precision in supplying images at shorter scan times, higher resolution and clarity, and lower cost compared to medical CT.

In a study by Razi et al., the soft tissue of a sheep's head was used.<sup>4</sup> Mah et al. placed specimens in a bowl of water in order to simulate soft tissue to some extent for X-ray attenuation.<sup>21</sup> However, Parsa et al. used a dry mandible.<sup>20</sup> In the present study, an attempt was made to obtain a number for the gray scale value of the restorative materials by eliminating confounding factors, such as facial soft tissue, tongue and saliva in order to provide a background for future studies.

In another study, Emadi et al. compared different samples of restorative materials and reported that amalgam and AH-26 had the highest gray scale value. Zinc phosphate, gutta-percha and zinc oxide eugenol had the second place, followed by MTA and polycarboxylate.<sup>8</sup> In the present study, amalgam, composite resin, flowable composite resin, glass-ionomer, and Dycal were studied, and the highest gray scale value was noted for amalgam; this was consistent with the results reported by Emadi et al. In the present study, Dycal exhibited the lowest gray scale.

## Conclusions

The results of the present study show that CBCT can be efficient in differentiating amalgam and composite resin from other materials, such as flowable composite resin, glass-ionomer and Dycal. This is a pilot study; therefore, in further studies we will compare this value in different CBCT and multi-row-detector computed tomography (MDCT) systems.

## References

1. Arisan V, Karabuda ZC, Avsever H, Özdemir T. Conventional multi-slice computed tomography (CT) and cone beam CT (CBCT) for computer assisted implant placement. Part I: Relationship radiographic gray density and implant stability. *Clin Impl Dent Rel Res*. 2013;15(6):893–906.
2. Aras MH, Miloglu O, Barutçugil C, Kantarici M, Ozcan E, Harorli A. Comparison of the sensitivity for detecting foreign bodies among conventional plain radiography, computed tomography and ultrasonography. *Dentomaxillofac Radiol*. 2010;39(2):72–78.
3. White SC, Pharoah MJ. *Oral Radiology: Principles and Interpretation*. 5<sup>th</sup> ed. St. Louis, MO: Mosby; 2009:207–211.
4. Razi T, Niknami M, Alavi Ghazani F. Relationship between Hounsfield unit in CT scan and gray scale in CBCT. *J Dent Res Dent Clin Dent Prospects*. 2014;8(2):107–110.
5. Katsumata A, Hirukawa A, Okumura S, et al. Relationship between density variability and imaging volume size in cone-beam computerized tomographic scanning of the maxillofacial region: An in vitro study. *Oral Surg Oral Med Oral Pathol Oral Radiol Endod*. 2009;107(3):420–425.
6. Lagravère MO, Carey J, Ben-Zvi M, Packota GV, Major PW. Effect of object location on the density measurement and Hounsfield conversion in a NewTom 3G cone beam computed tomography unit. *Dentomaxillofac Radiol*. 2008;37(6):305–308.
7. Oliveria ML, Freitas DQ, Ambrosano GM, Haite-Neto F. Influence of exposure factors on the variability of CBCT voxel values: A phantom study. *Dentomaxillofac Radiol*. 2014;43(6):20140128.
8. Emadi N, Safi Y, Akbarzadeh Bagheban A, Asgary S. Comparison of CT-number and gray scale value of different dental materials and hard tissues in CT and CBCT. *Iran Endod J*. 2014;9(4):283–286.
9. Esmaili F, Johari M, Haddadi P, Vatankhah M. Beam hardening artifacts: Comparison between two cone-beam computed tomography scanners. *Dent Res Dent Clin Dent Prospects*. 2012;6(2):2–7.
10. Chindasombatjareon J, Kakimoto N, Murakami S, Maeda Y, Furukawa S. Quantitative analysis of metallic artifacts caused by dental metals: Comparison of cone-beam and multi-detector row CT scanners. *Oral Radiol*. 2011;27:114–120.
11. Ludlow JB, Ivanovic M. Comparative dosimetry of dental CBCT devices and 64-slice CT for oral and maxillofacial radiology. *Oral Surg Oral Med Oral Pathol Oral Radiol Endod*. 2008;106(1):930–938.
12. Ludlow JB, Davis-Ludlow LE, Brooks SL, Howerton WB. Dosimetry of 3 CBCT devices for oral and maxillofacial radiology: CB Mercuray, NewTom 3G and i-Cat. *Dentomaxillofac Radiol*. 2006;35(4):219–226.
13. Schulze RK, Berndt D, d'Hoedt B. On cone-beam computed tomography artifacts induced by titanium implants. *Clin Oral Implant Res*. 2010;21(1):100–107.
14. Zöller JE, Neugebauer J. *Cone-beam Volumetric Imaging in Dental, Oral and Maxillofacial Medicine: Fundamentals, Diagnostics and Treatment Planning*. London, UK: Quintessence Publishing; 2008:27–35.
15. Haristoy RA, Valiyaparambil JV, Mallya SM. Correlation of CBCT gray scale values with bone densities. *Oral Surg Oral Med Oral Pathol Oral Radiol Endod*. 2009;107(4):28–35.
16. Lachowski KM, Botta SB, Lascala CA, Matos AB, Sobral MA. Study of the radio-opacity of base and liner dental materials using a digital radiography system. *Dentomaxillofac Radiol*. 2013;42(2):20120153.
17. Devito KL, Ortega AI, Haite Neto F. Radiopacity of calcium hydroxide cement compared with human tooth structure. *J Appl Oral Sci*. 2004;12(4):290–293.
18. Pires de Souza FC, Pardini LC, Cruvinel DR, Hamida HM, Garcia LFR. In vitro comparison of the radiopacity of cavity lining materials with human dental structures. *J Conserv Dent*. 2010;13(2):65–70.
19. Imperiano MT, Jamil Khoury H, Anjos Pontual ML, Japiassú Resende Montes MA, Fonseca Silveira MM. Comparative radiopacity of four low viscosity composites. *Braz J Oral Sci*. 2007;6(20):20–26.
20. Parsa A, Ibrahim N, Hassan B, Motroni A, van der Stelt P, Wismeijer D. Influence of cone beam CT scanning parameters on grey value measurements at an implant site. *Dentomaxillofac Radiol*. 2013;42(3):79884780.
21. Mah P, Reeves TE, McDavid WD. Deriving Hounsfield units using grey levels in cone beam computed tomography. *Dentomaxillofac Radiol*. 2010;39(6):323–335.

# The effect of fiber post location on fracture resistance of endodontically treated maxillary premolars

## Wpływ umiejscowienia wkładu z włókna szklanego na odporność na złamanie zębów przedtrzonowych szczęki, leczonych endodontycznie

Eshamsul Sulaiman<sup>1,A,E,F</sup>, Nada Alarami<sup>1,A–D,F</sup>, Yuh Ing Wong<sup>2,A–D</sup>, Wen Hui Lee<sup>2,A–D</sup>, Afaf Al-Haddad<sup>3,C,E,F</sup>

<sup>1</sup> Department of Restorative Dentistry, Faculty of Dentistry, University of Malaya, Kuala Lumpur, Malaysia

<sup>2</sup> Taiping Health Clinic, Malaysia

<sup>3</sup> Department of Dental Materials and Equipment, Faculty of Dentistry, Mahsa University, Selangor, Malaysia

A – research concept and design; B – collection and/or assembly of data; C – data analysis and interpretation;

D – writing the article; E – critical revision of the article; F – final approval of the article

Dental and Medical Problems, ISSN 1644-387X (print), ISSN 2300-9020 (online)

*Dent Med Probl.* 2018;55(3):275–279

### Address for correspondence

Nada Alarami

E-mail: nada\_alarami@yahoo.com

### Funding sources

Research grant No. ER002- 2011A, University of Malaya, Kuala Lumpur, Malaysia.

### Conflict of interest

None declared

Received on July 2, 2018

Reviewed on August 13, 2018

Accepted on August 27, 2018

### DOI

10.17219/dmp/94656

### Copyright

© 2018 by Wrocław Medical University and Polish Dental Society

This is an article distributed under the terms of the Creative Commons Attribution Non-Commercial License (<http://creativecommons.org/licenses/by-nc-nd/4.0/>)

## Abstract

**Background.** There is no sufficient literature on the effect of post location on endodontically treated premolar teeth with 2 roots.

**Objectives.** The aim of the study was to evaluate the effect of fiber post location on fracture resistance and failure mode of endodontically treated premolars with 2 roots.

**Material and methods.** Fifty extracted maxillary first premolars with 2 roots were divided randomly into 5 groups. Group 1 was comprised of sound teeth, which received only metal crowns (control). Teeth from groups 2, 3, 4, and 5 were decoronated 2 mm above the cemento-enamel junction (CEJ) and were endodontically treated. No post was placed in group 2 teeth. Teeth from groups 3, 4 and 5 were given a fiber post placed in the buccal canal, palatal canal, and both buccal and palatal canals, respectively. All teeth in groups 2, 3, 4, and 5 were built up with composite and full coverage metal crowns. A compressive static load was applied at an angle of 25° to the crowns with a crosshead speed of 0.5 mm/min, until fracture.

**Results.** One-way analysis of variance (ANOVA) showed significant differences among the groups ( $p = 0.002$ ). A post hoc test showed significantly lower fracture resistance of group 4 compared to group 5 ( $p = 0.011$ ). Furthermore, group 2 had significantly less fracture resistance compared to group 1 ( $p = 0.021$ ) and group 5 ( $p = 0.002$ ). According to Fisher's exact test, different post locations are non-significantly associated with fracture mode ( $p = 0.256$ ).

**Conclusions.** Fiber post location has a significant effect on fracture resistance of severely damaged, endodontically treated maxillary premolars with 2 roots. However, post placement in the palatal root is preferred, as it maintains the restorability of the tooth.

**Key words:** fracture mode, fracture resistance, fiber post, maxillary premolars with 2 roots, post location

**Słowa kluczowe:** rodzaj złamania, odporność na złamanie, wkład z włókna szklanego, zęby przedtrzonowe szczęki z 2 korzeniami, umiejscowienie wkładu

## Introduction

Endodontically treated teeth are generally weaker and more prone to fracture compared to teeth that have not been root-filled, mainly due to loss of tooth structure from caries, trauma, or previous restorations, and access to the root canal itself.<sup>1</sup> Loss of tooth structure due to access preparation results in increased cuspal deflection during mastication, which subsequently increases the possibility of cusp fracture and microleakage at the margin of the restorations.<sup>2</sup> It has been suggested that fracture resistance of endodontically treated teeth is directly related to the remaining tooth structure, especially in the buccolingual dimension.<sup>3</sup>

Endodontically treated teeth can have a good prognosis and be restored to full function, even serving as an abutment for a fixed and removable prosthesis, when adequate root filling quality is ensured and sufficient tooth structure remains to support the final restoration.<sup>4,5</sup> A post is recommended when the remaining coronal tooth structure is insufficient to retain a core build-up to support the final restoration.<sup>6–8</sup> Different prefabricated post systems have been introduced and successfully used in clinical situations, which decreases chairside time and reduces the cost on the side of the patient.<sup>9</sup> The glass fiber post is a well-accepted treatment modality for the restoration of endodontically treated teeth due to its superior mechanical properties, such as uniform stress distribution, higher fracture resistance, superior optical properties, and a modulus of elasticity similar to that of dentine.<sup>10,11</sup>

Posts are able to protect teeth from fracture by dissipating or distributing forces along the tooth.<sup>12</sup> Posts are also indicated to increase the retention of the amalgam and composite core. However, not all endodontically treated teeth require a post,<sup>2</sup> and since posts do not reinforce such teeth,<sup>13</sup> their use should be limited to those with inadequate tooth structure. In addition, preparing space for the post is associated with some risk.<sup>2</sup> Although rare, the risk includes perforation in the apical portion of the root or into the lateral fluted areas of the mid-root, called “strip perforation”.<sup>14</sup> The most common types of fractures in post-retained restorations are root fracture, loosening of the post and fracture of the post.<sup>15</sup> Root fractures are most often unrestorable, which subsequently results in the extraction of the tooth.<sup>15</sup>

According to Gutmann, maxillary premolars often have marked tapering and thin roots, which increase the risk of root perforation and fracture.<sup>16</sup> Additionally, furcation grooves or developmental depressions on the palatal side of the buccal root also increase the risk of endodontic and prosthodontic treatment fractures, because the average dentine layer at the deepest part of invagination was found to be too thin, equal to 0.81 mm.<sup>17</sup> In a retrospective study of 468 teeth that had fractured *in vivo*, 78% were premolars, with 62% of these being maxillary premolars.<sup>18</sup>

Since maxillary first premolars normally have 2 roots, dentists may face a dilemma while choosing the canal to place the post in (buccal or palatal, or both buccal and palatal). If possible, both canals of teeth with 2 roots should be utilized for post placement, since roots of premolars require bulk and length for the successful use of the post and core.<sup>19</sup> To our knowledge, there has been no study on the effect of post location on endodontically treated premolar teeth with 2 separate roots. Thus, this study was conducted to compare the effect of fiber post location on fracture resistance and failure mode of endodontically treated maxillary first premolars with 2 roots.

## Material and methods

Fifty non-carious, maxillary first premolars with 2 roots, extracted for periodontal reasons, were collected. All the teeth were disinfected in 0.5% chloramine-T solution for 1 week according to ISO/TS 11405 (2003). The selected premolars were examined under a stereomicroscope at  $\times 10$  magnification (SZX7; Olympus Corporation, Tokyo, Japan) to ensure fracture-free roots. All external debris was removed from the roots with an ultrasonic scaler (Peizon® Master 400; Electro Medical Systems, Nyon, Switzerland). Tooth dimensions were measured using a digital caliper (Mitutoyo, Tokyo, Japan); teeth with a length of  $21.5 \pm 1$  mm, root length of  $14 \pm 1$  mm, buccolingual width of  $8 \pm 1$  mm, and mesiodistal width of  $6 \pm 1$  mm were selected. The teeth were randomly and equally divided into 5 groups to be restored as follows:

- group 1 – no post/core, only metal crown restorations (control);
- group 2 – root canal treatment, composite core, metal crown (control);
- group 3 – fiber post placed in the buccal canal, followed by composite resin core and metal crown;
- group 4 – fiber post placed in the palatal canal, followed by composite resin core and metal crown;
- group 5 – fiber post placed in both the buccal and palatal canals, followed by composite resin core and metal crown.

All teeth except for group 1 were decoronated 17 mm from the apical end of the root toward the crown by means of a horizontal cut, perpendicular to the long axis of the root. Teeth in groups 2, 3, 4, and 5 were endodontically treated. An access cavity was established in a conventional manner by using an endodontic access bur (Dentsply Maillefer, Ballaigues, Switzerland). Specimens were prepared using the step-back technique with K-files (Dentsply Maillefer). The working length was 1 mm shorter than the file length (16 mm). The master apical file used was size 30. The canals were repeatedly irrigated after each filing with 3.0 mL of 1% sodium hypochlorite solution (NaOCl) (Clorox (Malaysia) Industries Sdn. Bhd., Kuala Lumpur, Malaysia). The teeth were obturated with gutta-percha cones (Dentsply Maillefer), using the lateral condensation technique and AH Plus® root canal sealer (Dentsply Maillefer).

After the sealer had set, gutta-percha in groups 3, 4 and 5 was first removed by a heated endodontic plugger until canal orifices were seen. FRC Postec Plus<sup>®</sup> fiber posts (Ivoclar Vivadent, Schaan, Liechtenstein) size 0 with a diameter of 0.6 mm were used. The post space was prepared with a low-speed matching drill, which corresponded to the FRC Postec Plus fiber post size. Finally, 4 mm of gutta-percha was left at the apex of the canals, where the post was indicated.

A thin layer of light-body, silicone-based impression material (Aquasil Ultra<sup>®</sup> XLV; Dentsply Maillefer) was first applied around the root surface to simulate the periodontal ligament. Each tooth was then embedded in cold-cure epoxy resin (Mirapox<sup>®</sup> – 230 A and B; Miracon Sdn. Bhd., Kuala Lumpur, Malaysia), using a silicone mold 2 mm below the cemento-enamel junction (CEJ), 4 mm from the coronal surface, to simulate the bone level.

The post length was standardized at 15 mm. After trial insertion, the post was rinsed with normal saline, and then dried. First, adhesive (AdheSE<sup>®</sup> DC; Ivoclar Vivadent) was applied in the prepared canal and the coronal part of the tooth. Then, the post was cemented with Multi-Core<sup>®</sup> Flow dual-curing composite (Ivoclar Vivadent) according to the manufacturer's instructions. A matrix band was placed around the tooth to ease the core build-up procedure. The composite resin was flooded into the matrix to form the core until the desired height of 6 mm from the CEJ level was reached, covering the coronal end of the post. The occlusal surface was light-cured for 40 s. The matrix band was then removed and an additional 40 s of polymerization was subsequently performed on the surfaces around the core to ensure complete setting of the core material.

Each specimen was prepared to receive a metal crown (Wiron<sup>®</sup> 99; Bego, Bremen, Germany). In order to standardize the preparation convergence angle, a diamond bur (998FG021 round-ended, tapered with a guide pin; NTI-Kahla GmbH, Kahla, Germany) was attached to a high-speed rotary handpiece, which was fixed to a paralleling device (custom-made at the Department of Mechanical Engineering, Faculty of Engineering, University of Malaya). A guide pin at the tip of the bur produced a standardized depth of the chamfer margin of 1 mm. The core height of 6 mm from CEJ was marked by using a digital caliper (Mitutoyo). Occlusal reduction was done using a high-speed diamond bur (S811-314-037-7-ML; Swisstec 3D Akus AG, Uster, Switzerland) up to the marking line. A one-step impression technique was used to take the impression of the preparation specimens, using Impregum Soft Polyether Impression Material (Impregum<sup>®</sup> Penta Soft ESPE; 3M, Maplewood, USA). The crowns were fabricated using a non-precious alloy. The axial and occlusal thicknesses of the crowns were standardized to 1 mm and 2 mm, respectively, using a crown caliper and tungsten carbide burs. A small indentation, measuring 3 mm in diameter and 1 mm in depth, was made on the buccal cusp,




Fig. 1. The position of a specimen in a customized metal holder in a universal testing machine for static loading at 25°

2 mm from the central fossa of each crown. The crowns were cemented using self-adhesive resin cement (Multilink Speed<sup>®</sup>; Ivoclar Vivadent).

Each specimen in the resin block was fixed in a customized metal holder in a universal testing machine (Auto-graph; Shimadzu, Kyoto, Japan), 25° to the crown (Fig. 1). A compressive load was applied using a stainless steel, round-ended loading rod, 3 mm in diameter, at a cross-head speed of 0.5 mm/min. The load was applied on the palatal cusp, 2 mm from the central fossa. The compressive load was applied until fracture occurred. The data was analyzed using SPSS software, v. 12 (IBM Corp., Armonk, USA). One-way analysis of variance (ANOVA) was employed to compare the mean fracture loads. The significance value was set at  $p = 0.05$ . The multiple comparisons post hoc Bonferroni test was used to detect significant differences among the groups. The fracture pattern of each specimen was recorded. The fracture mode was classified into either restorable or unrestorable. Fractures occurring as complete or partial post and core debonding, or a post-core-tooth complex fracture above the epoxy resin level were considered restorable. The unrestorable fracture modes were represented by those specimens that displayed a post/core/root fracture below the epoxy resin level, vertical root fractures, or cracks below the epoxy resin level.

## Results

The means of the fracture load and frequencies of fracture modes for all groups are presented in Table 1. The Shapiro-Wilk test indicated that the dependent variable was normally distributed ( $p > 0.05$ ). One-way ANOVA showed that statistically significant differences between the groups ( $p = 0.002$ ). The post hoc test showed no significant differences between group 3 and group 4. However, teeth with a post in the palatal canal (group 4) showed

**Table 1.** Comparison of fracture loads and failure modes among the groups

Groups	Fracture load [N] mean $\pm$ SD	F-statistic* (df)	p-value	Failure mode	
				restorable n (%)	unrestorable n (%)
Control (sound teeth) <sup>c</sup>	1215.9 $\pm$ 320.7			3 (30.0)	7 (70.0)
Control (no post) <sup>b,c</sup>	745.46 $\pm$ 265.6			8 (80.0)	2 (20.0)
Fiber post in buccal canal	1224.1 $\pm$ 507.4	4 (5.13)	0.002	4 (40.0)	6 (60.0)
Fiber post in palatal canal <sup>a</sup>	937.2 $\pm$ 128.3			6 (60.0)	4 (40.0)
Fiber post in both buccal and palatal canals <sup>a,b</sup>	1259.5 $\pm$ 220.1			3 (30.0)	7 (70.0)

Data is presented as mean  $\pm$  standard deviation (SD) or number (percentage). df – degrees of freedom; \* one-way analysis of variance (ANOVA);

<sup>a</sup> group 4 vs group 5 ( $p = 0.011$ ); <sup>b</sup> group 2 vs group 5 ( $p = 0.002$ ); <sup>c</sup> group 2 vs group 1 ( $p = 0.021$ ).

lower fracture resistance compared to those restored with posts in both the buccal and palatal canals (group 5) ( $p = 0.011$ ). In addition, group 2 (teeth without a post) had significantly less fracture resistance compared to group 1 (sound teeth) ( $p = 0.021$ ) and group 5 ( $p = 0.002$ ).

As regards failure mode, 40–60% of the endodontically treated maxillary premolars restored with a fiber post failed catastrophically. According to the results of a series of Fisher's exact tests, different post placement is non-significantly associated with fracture mode ( $p = 0.256$ ).

## Discussion

The main disadvantage of using human teeth in studies conducted *in vitro* is the difficulty of specimen standardization due to different physical and mechanical properties of teeth, the morphological variation of the pulp, the aging of the tooth, and the presence of micro-cracks in the dentine.<sup>20</sup> Therefore, teeth with similar mesiodistal and buccolingual dimensions at CEJ were chosen rather than teeth with a similar crown height. However, standardizing the root morphology and anatomy was an enormous challenge, which might have affected the results of the study. In the tested groups, teeth were decoronated approx. 2 mm above CEJ to simulate the worst-case scenario with substantial loss of tooth structure, whereby the post must be indicated to retain the core. This was also to provide a 2-millimeter ferrule height, as recommended by other studies.<sup>21,22</sup> In the present study, teeth were loaded on the palatal cusp, 25° to the long axis of the tooth, to simulate the presence of non-working side interference.<sup>23</sup>

Many studies have shown that a high percentage of dentists believe that posts do strengthen endodontically treated teeth.<sup>24–26</sup> The present study demonstrated that teeth restored with fiber posts, resin cement, composite core, and a crown were more resistant to fracture than those without a post. This showed that fiber posts might strengthen severely compromised, endodontically treated premolars. The results of the present study were also in agreement with previous studies, which found that the absence of a post decreased fracture resistance of endodontically treated teeth.<sup>27,28</sup>

However, when a fiber post was placed in the palatal root canals, fracture resistance was not significantly higher compared to the roots without a post. This implied that a post placed in the palatal root canal of maxillary premolars might not provide resistance to fracture when the force was directed on the same cusp (non-working side interference). The current study also demonstrated that a ferrule alone, without a post, could not resist the fracture when the load was applied on the palatal cusp. However, Zicari et al. demonstrated that there was no difference in fracture resistance between the premolars restored with and without fiber posts when a 2-millimeter ferrule was present. This disagreement might be referred to the use of only single-rooted premolars in that study.<sup>29</sup>

In the current study, teeth with a post in the palatal canal showed lower fracture resistance compared to those restored with posts in both the buccal and palatal canals. This can be attributed to the morphology of the buccal root. It was stated that placing the post in the buccal root of bifurcated maxillary premolars must be avoided, as root canal preparation and post preparation resulted in lesser residual dentin thickness.<sup>30</sup> Since the eccentric force was applied in this study, most of the stress was on the buccal root and with no post placed to support the buccal root, and the residual tooth structure was inadequate to resist the fracture load. However, placing the posts in both the buccal and palatal root canals supports the lesser dentin thickness in the buccal root and enhances fracture resistance.

Even 40–60% of the endodontically treated maxillary premolars restored with a fiber post in this study failed catastrophically, and the group with a fiber post placed in the palatal canal showed a higher percentage of restorable failure (60%). This could be attributed to the direction of the force exerted on the palatal cusp, which means that the palatal post is closer to the fracture fulcrum, and thus receives less stress compared to the post placed in the buccal canal. However, normal intraoral masticatory forces are estimated to range between 500 and 600 N.<sup>31</sup> Therefore, the results of this study suggest that prefabricated fiber posts can safely be used in maxillary premolars with 2 roots, as fracture resistance proved to be well above 600 N.

The design of the present study attempted to simulate true clinical situations; however, it is difficult to interpret the results directly for clinical practice. This is due to some limitations, including the fact that it was an in vitro investigation, which could not fully replicate the dynamics of oral conditions. Furthermore, a static load which was applied on 1 point in a monostatic pattern did not represent intraoral conditions. This study evaluated only maxillary first premolars, and thus the results may only be applied to that group of teeth.

## Conclusions

Within the limitations of this study, fiber post location has a significant effect on fracture resistance of severely damaged, endodontically treated maxillary premolars with 2 roots. However, post placement in the palatal root is preferred, as it maintains the restorability of the tooth.

## References

- Steele A, Johnson BR. In vitro fracture strength of endodontically treated premolars. *J Endod.* 1999;25(1):6–8.
- Schwartz RS, Robbins JW. Post placement and restoration of endodontically treated teeth: A literature review. *J Endod.* 2004;30(5):289–301.
- Tjan AH, Whang SB. Resistance to root fracture of dowel channels with various thicknesses of buccal dentin walls. *J Prosthet Dent.* 1985;53(4):496–500.
- Mohammadi N, Kahnemoui MA, Yeganeh PK, Navimipour EJ. Effect of fiber post and cusp coverage on fracture resistance of endodontically treated maxillary premolars directly restored with composite resin. *J Endod.* 2009;35(1):1428–1432.
- Morgano SM, Rodrigues AHC, Sabrosa CE. Restoration of endodontically treated teeth. *Dent Clin North Am.* 2004;48(2):397–416.
- Schwartz RS, Fransman R. Adhesive dentistry and endodontics: Materials, clinical strategies, and procedures for restoration of access cavities: A review. *J Endod.* 2005;31:151–165.
- Cheung W. A review of the management of endodontically treated teeth. Post, core, and the final restoration. *J Am Dent Assoc.* 2005;136(5):611–619.
- Peroz I, Blankenstein F, Lange KP, Naumann M. Restoring endodontically treated teeth with posts and cores: A review. *Quintessence Int.* 2005;36(9):737–746.
- Hochman N, Feinzaig I, Zalkind M. Effect of design of pre-fabricated posts and post heads on the retention of various cements and core materials. *J Oral Rehabil.* 2003;30(7):702–707.
- Plotino G, Grande NM, Bedini R, Pameijer CH, Somma F. Flexural properties of endodontic posts and human root dentin. *Dent Mater.* 2007;23(9):1129–1135.
- Seefeld F, Wenz HJ, Ludwig K, Kern M. Resistance to fracture and structural characteristics of different fiber reinforced post systems. *Dent Mater.* 2007;23(3):265–271.
- Makade CS, Meshram GK, Warhadpande M, Patil PG. A comparative evaluation of fracture resistance of endodontically treated teeth restored with different post core systems: An in-vitro study. *J Adv Prosthodont.* 2011;3(2):90–95.
- Morgano SM. Restoration of pulpless teeth: Application of traditional principles in present and future contexts. *J Prosthet Dent.* 1996;75(4):375–380.
- Mahmoud T, Walton RE. *Endodontics: Principles and Practice.* 4<sup>th</sup> ed. St. Louis, MO: Saunders; 2009:322–339.
- Peutzfeldt A, Sahafi A, Asmussen E. A survey of failed post-retained restorations. *Clin Oral Invest.* 2008;12(1):37–44.
- Gutmann JL. The dentine-rot complex: Anatomical and biologic considerations in restoring endodontically treated teeth. *J Prosthet Dent.* 1992;67(4):458–467.
- Hargreaves KM, Cohen S. *Cohen's Pathways of the Pulp.* 10<sup>th</sup> ed. St. Louis, MO: Mosby Elsevier; 2011:148–233.
- Rud J, Omnell K-A. Root fractures due to corrosion diagnostic aspects. *Scand J Dent Res.* 1970;78(5):397–403.
- Shillingburg HT, Hobo S, Whitsett LD, Jacobi R, Brackett SE. *Fundamental of Fixed Prosthodontics.* 3<sup>rd</sup> ed. Chicago, IL: Quintessence Publishing Co., Inc.; 1997:85–103.
- Fokkinga WA, Kreulen CM, Le Bell-Rönnlöf AM, Lassila LV, Vallittu PK, Creugers NH. In vitro fracture behavior of maxillary premolars with metal crowns and several post-and-core systems. *Eur J Oral Sci.* 2006;114(3):250–256.
- Watanabe MU, Anchieta RB, Rocha EP, et al. Influence of crown ferrule heights and dowel material selection on the mechanical behavior of root-filled teeth: A finite element analysis. *J Prosthodont.* 2012;21(4):304–311.
- Tan PLB, Aquilino SA, Gratton DG, et al. In vitro fracture resistance of endodontically treated central incisors with varying ferrule heights and configurations. *J Prosthet Dent.* 2005;93(4):331–336.
- Dietschi D, Duc O, Krejci I, Sadan A. Biomechanical considerations for the restoration of endodontically treated teeth: A systematic review of the literature – Part 1. Comparison and micro- and macrostructure alterations. *Quintessence Int.* 2007;38(9):733–743.
- Morgano SM, Hashem AF, Fotoohi K, Rose L. A nationwide survey of contemporary philosophies and techniques of restoring endodontically treated teeth. *J Prosthet Dent.* 1994;72(3):259–267.
- Eckerbom M, Magnusson T. Restoring endodontically treated teeth: A survey of current opinions among board-certified prosthodontists and general dental practitioners in Sweden. *Int J Prosthodont.* 2001;14(3):245–249.
- Naumann, M, Kiessling S, Seemann, R. Treatment concepts for restoration of endodontically treated teeth: A nationwide survey of dentists in Germany. *J Prosthet Dent.* 2006;96(5):332–338.
- Salameh Z, Sorrentino R, Papacchini F, et al. Fracture resistance and failure patterns of endodontically treated mandibular molars restored using resin composite with or without translucent glass fiber posts. *J Endod.* 2006;32(8):752–755.
- Santana FR, Castro CG, Simamoto-Júnior PC, et al. Influence of post system and remaining coronal tooth tissue on biomechanical behavior of root filled molar teeth. *Int Endod J.* 2011;44(5):386–394.
- Zicari F, Van Meerbeek B, Scotti R, Naert I. Effect of ferrule and post placement on fracture resistance of endodontically treated teeth after fatigue loading. *J Dent.* 2013;41(3):207–215.
- Pilo R, Shapenco E, Lewinstein I. Residual dentin thickness in bifurcated maxillary first premolars after root canal and post space preparation with parallel-sided drills. *J Prosthet Dent.* 2008;99(4):267–273.
- Rosentritt M, Furer C, Behr M, Lang R, Handel G. Comparison of in vitro fracture strength of metallic and tooth-colored posts and cores. *J Oral Rehabil.* 2000;27(7):595–601.





# The repeatability and reproducibility of gingival thickness measurement with an ultrasonic device

## Powtarzalność i odtwarzalność pomiaru grubości dziąsła biometrem ultrasonograficznym

Aneta Furtak<sup>1,A–F</sup>, Elżbieta Leszczyńska<sup>1,B,C</sup>, Aleksandra Sender-Janeczek<sup>2,E,F</sup>, Wojciech Bednarz<sup>1,2,A–F</sup>

<sup>1</sup> Specialist Outpatient Medical Clinic MEDIDENT in Gorlice, Poland

<sup>2</sup> Department of Periodontology, Faculty of Dentistry, Wrocław Medical University, Poland

A – research concept and design; B – collection and/or assembly of data; C – data analysis and interpretation; D – writing the article; E – critical revision of the article; F – final approval of the article

Dental and Medical Problems, ISSN 1644-387X (print), ISSN 2300-9020 (online)

*Dent Med Probl.* 2018;55(3):281–288

### Address for correspondence

Wojciech Bednarz

E-mail: wojcie\_ch@poczta.onet.pl

### Funding sources

None declared

### Conflict of interest

None declared

Received on July 15, 2018

Reviewed on August 15, 2018

Accepted on September 13, 2018

### Abstract

**Background.** Successful periodontal and implant surgery as well as orthodontic treatment often depends on gingival and mucosal thickness. So far there has been no generally accepted protocol of measuring the thickness of gingiva by non-invasive methods.

**Objectives.** The aim of the study was to evaluate the repeatability and reproducibility (%R&R) of the 20 MHz A-Scan ultrasonic device in measuring gingival thickness (GT) in the mucogingival complex.

**Material and methods.** A 2-stage study utilizing non-invasive ultrasonic methods was conducted. In the 1st stage, 3 operators got calibrated by measuring previously established GT in porcine cadaver jaws. In the 2nd stage, 1 periodontally healthy subject was recruited in the study. Three operators performed the measurements of GT in maxillary left central and lateral incisors and canines, using the 20 MHz A-Scan ultrasonic device with a probe of 1.7 mm in diameter. The thickness was measured in 4 standardized points located in the free gingiva (FGT), supracrestal gingiva (SGT), crestal gingiva (CGT) and the mucosa (MGT).

**Results.** The analysis of variance (ANOVA) method was used to quantify %R&R. The repeatability and reproducibility of the measurements was 8.4%. Interobserver reproducibility varied from 0.8% to 13.4%. The average intraobserver coefficient of variation (CV) was 6.6% (1.9–13.6%). The median of the reproducibility of all measurements was 8.1%. Nevertheless, the median of CV was variable to the observer, i.e. 5.4%, 6.5%, 6.4%.

**Conclusions.** The obtained results in %R&R prove the good recognition of methodology as well as the usefulness of the device. Non-invasive ultrasonic biometer GT measurements are crucial in periodontology as well as in other fields of dentistry.

**Key words:** gingiva, periodontium, anatomy and histology, ultrasonography, reproducibility of results

**Słowa kluczowe:** dziąsło, przyzębie, anatomia i histologia, ultrasonografia, odtwarzalność wyników

### DOI

10.17219/dmp/95111

### Copyright

© 2018 by Wrocław Medical University  
and Polish Dental Society

This is an article distributed under the terms of the  
Creative Commons Attribution Non-Commercial License  
(<http://creativecommons.org/licenses/by-nc-nd/4.0/>)

## Introduction

The first report on the utility of ultrasound in dental diagnostic process appeared in 1963.<sup>1</sup> The authors used a 15 MHz converter to visualize intradental structures. However, the results were not satisfying. Since that time, several research studies on using ultrasound in imaging hard and soft tissues of the oral cavity have been published.<sup>2</sup> Researchers have worked on fractures and cracked teeth,<sup>3</sup> caries detection,<sup>4</sup> periapical lesions,<sup>5</sup> alveolar ridge and maxillofacial bones structures,<sup>6</sup> temporomandibular joints,<sup>7</sup> and on the measurements of soft tissue of the oral cavity, in particular of the gingiva and the masseter muscle.<sup>8–12</sup> Furthermore, it is possible to use ultrasounds to examine pathological structures, such as neoplastic lesions of the mucosa,<sup>13</sup> but also to detect the implant-abutment connection or to assess the margin of the alveolar ridge and the clinical attachment level, which can be used to evaluate the probing depth of the gingival sulcus and biologic width.<sup>14</sup>

Nowadays, there is an increasing interest in evaluating the quality of the gingival margin. This is widely used in orthodontics, periodontology, implantology, and prosthodontics.<sup>15–18</sup> Knowing the amount of the keratinized attached gingiva, the orthodontist can assess the risk of gingival recession and future problems in the treatment process, especially during proclination and labial bodily movements.<sup>16</sup> Thus, the orthodontic treatment is safer and gingival recession can be avoided. In the field of periodontology, especially periodontal surgery, the assessment of the quality of the gingiva is helpful in planning the technique and making a prognosis of the surgery.<sup>15–17</sup> In implantology, the thickness of tissue plays a key role in the long-term stability of the dental implant.<sup>18</sup> Accumulating evidence indicates that the atrophy of the buccal bone is lower when the attached gingiva is thicker.<sup>19–21</sup> Gingival thickness determines the method of preparation of the prosthetic crowns. Dental esthetics is one of the most common reasons for improving dental procedures. Nowadays, dental restoration or filling as well as teeth whitening no longer satisfy the needs and expectations of the patients and dentists. Pink-white esthetics has become a challenging task and the balance between restorations and the gingiva seems to become a standard of the optimal dental treatment, consistent with the patient's expectations.

The quality of soft tissue around the teeth and dental implants plays an important role in the diagnostic process as well as in the treatment of gingival problems.<sup>22</sup> The quantity of the gingiva can be measured with 2 parameters: the width of keratinized tissue and the thickness of soft tissue at different levels of the dentogingival unit.<sup>23</sup> The 1<sup>st</sup> one is relatively easy to assess by periodontal probing, but the 2<sup>nd</sup> parameter can be particularly difficult to measure for inexperienced clinicians.<sup>8,10,17</sup>

Measurements of soft dental tissue can be done with invasive methods, e.g., with an injection needle or an endodontic file with a silicone stop (bone sounding method)

or computed tomography (CT). Until now, the gold standard procedure have been the invasive methods.<sup>10</sup> However, using an ultrasonic biometer is a non-invasive method that has been reported to be the most efficient procedure.<sup>10,17,24–26</sup> The procedure is based on the pressure-free application of the head of an ultrasonic probe to the surface of tissue at a right angle. The signal bounces off the tooth or the alveolar bone and comes back to the head of the probe. The time it takes for the signal to return to the device is taken into account to determine the distance, which then can be used to calculate the actual gingival thickness (GT). The main advantage of the presented method is its safety for the patient and the doctor.<sup>26</sup> It reduces the concerns many patients have about excess radiation exposure and the need for local anesthetics. Measurements are very precise (the accuracy to the 2<sup>nd</sup> decimal place) and immediately available. Moreover, the cost of a single examination is relatively low. Nevertheless, correct measurements require an experienced examiner.

An ophthalmic ultrasonic biometer has been used for the examinations of GT, but the diameter of the periodontal probe was too wide for dental purposes, since the size of the transducer probe head was larger than the examined area.<sup>10</sup> The other challenges of using the discussed method include the curved surface of bone and roots. The shape causes a nonparallel reflection of the signal, which is not received by the transducer.<sup>17</sup> Müller et al. reported the difficulty in interpreting the results as well as high measurement inaccuracy.<sup>9</sup> The repeatability of the measurements of 1 clinician and between all the examiners is a critical parameter.

The present study was focused on the ultrasonic biometry of soft tissue around the tooth, and was aimed at validating whether the method is precise and repeatable to be used in a dental office by 1 examiner, and whether the measurements can be reproduced among 3 operators. The ultrasonic device used to obtain all the measurements was PIROP® (Echo-Son S.A. Puławy, Poland) (Fig. 1) and has been described in previous articles.<sup>10,27</sup>

## Material and methods

### Project plan

The study was designed to validate the ultrasonic method of GT measurements in dentistry. The 1<sup>st</sup> stage of the project was to perform the preclinical training and calibration of the researchers. In the 2<sup>nd</sup> stage of the project, a periodontally healthy volunteer was examined in the clinical environment. The results were taken for statistical analysis. The study was conducted in accordance with the Declaration of Helsinki of 1975 as revised in 2000, and the study protocol was approved by the ethical committee of Wrocław Medical University (No. KB-126/2018). The authors declare the lack of the conflict of interests and the manufacturer Echo-Son S.A. declares the lack of third-party involvement in our research.



Fig. 1. PIROP® (Echo-Son S.A., Puławy, Poland)  
Specifications: probe frequency – 20 MHz; velocity range – 1400–3000 m/s; measurement range – 0.25–6 mm; axial resolution – 0.01 mm (10  $\mu$ m); 4 predefined maps of periodontal areas.

## Determining the variability of the measurement process

A diagnostic tool, which guides us in making any clinical decisions, should reflect the real conditions as accurately as possible. Hence, the trial was conducted according to Measurement System Analysis (MSA), which is the first critical step in qualifying the measurement method by quantifying its precision, repeatability, reproducibility, and accuracy.<sup>27</sup> Measurement System Analysis is an experimental, mathematical method of determining the variability of the measurement process. To verify usefulness of the measurement process, the Repeatability and Reproducibility (R&R) test is carried out. Repeatability means obtaining identical measurement results by 1 examiner using the same device. Reproducibility means obtaining identical measurement results by a few operators using the same device. The R&R result is expressed as a percentage (%R&R) assuming a 90% confidence interval (CI) with lower and upper borders. In the R&R test, 10 measurements of 3 trials are carried out by 3 examiners. The MSA standards of acceptance of a measurement system are shown in Table 1.

Table 1. Measurement System Analysis (MSA) standards

Combined R&R value [%]	Level of acceptance of the system
$R\&R \leq 10$	acceptable
$30 \leq R\&R < 10$	conditionally acceptable
$R\&R > 30$	not acceptable

R&R – repeatability and reproducibility.

## Calibration and training

The study was conducted at the Department of Periodontology in Specialist Outpatient Clinic in Gorlice, Poland. To reduce the potential bias related to the human factor (caused by an examiner's performance), the preclinical calibration and training of the 3 examiners were provided. For both the training and clinical trial, PIROP was used. A fresh porcine jaw was prepared for practicing purpose. In the preclinical calibration, the porcine jaw was placed on the laboratory scale, which was subsequently reset to zero to enable the pressure control. One point was marked on keratinized tissue on the palatal side of the porcine jaw. The probe was applied to the point with minimum pressure, lower than 25 g, which was controlled by sight in the scale screen as shown in Fig. 2. The perpendicular position of the probe enabled the return of the echo. The result was calculated on the basis of the time it took for the transducer to receive the signal and the velocity of the pulse, which was then displayed digitally on the screen of the PIROP biometer. To move to the next phase of the calibration, it was necessary to repeat the measurement 10 times with the appropriate pressure maintained. Each examiner performed 10 measurements consisting of 10 signals each. The researcher was blind to the values of

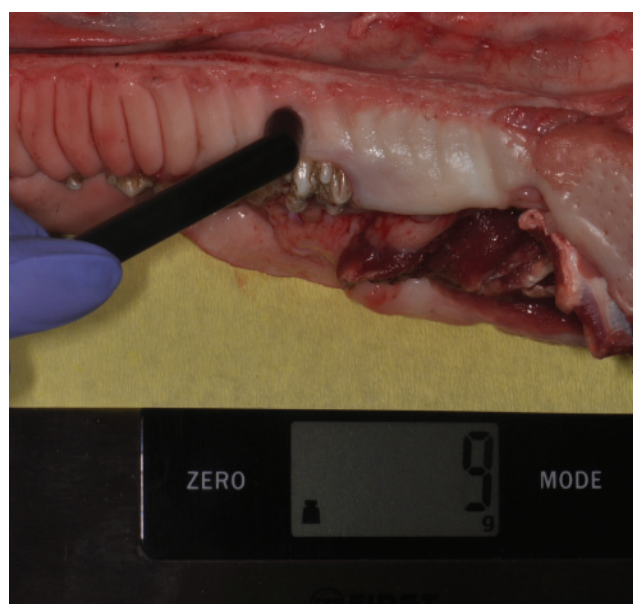

Fig. 2. Placement of the probe with the pressure of 9 g

the pressure exerted by the ultrasound probe on tissues, presented on the screen of the scale; they were controlled by other person. Calibration was finished after obtaining 10 measurements of GT at the pressure <25 g. One researcher applied the bone sounding method in the designated point with an endodontic file, which is considered to be a gold standard for measuring the thickness of soft tissue (Fig. 3,4). The direct measurement with a calliper (calibrated to the 2<sup>nd</sup> decimal place) was a control reference. All 3 examiners positively completed the training.

## Clinical examination

One periodontally healthy volunteer was recruited. Three teeth in the left upper jaw were selected for the examination: a central incisor, a lateral incisor and a canine tooth. First, the probing depth, the clinical attachment level and the width of keratinized gingiva were estimated in each dentogingival unit. According to the previous study, showing a statistically significant difference between the thickness in the supracrestal and crestal gingiva,<sup>28</sup> 3 points were marked on the labial surface of the gingiva and 1 point on the alveolar movable mucosa (Fig. 5). The 1<sup>st</sup> point – free gingival thick-

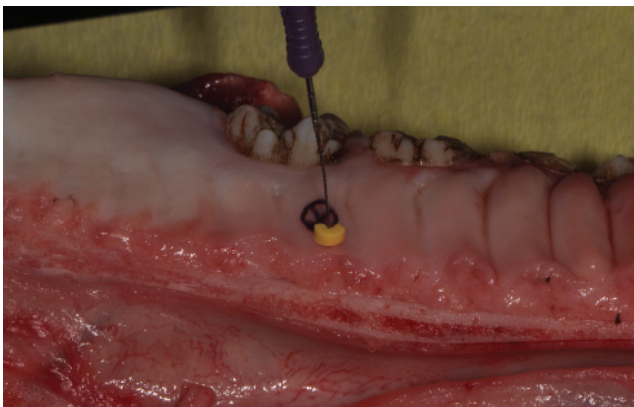


Fig. 3. Bone sounding method with an endodontic file




Fig. 4. Measuring the distance with a digital calliper

ness (FGT) – was localized on the free margin of the gingiva. The head of the probe was positioned with its lower border at the clinical attachment level, more coronally (Fig. 6). The 2<sup>nd</sup> point – supracrestal gingival thickness (SGT) – allowed us to measure the thickness of the supracrestal gingiva attached to the tooth surface. The upper border of the probe was placed at the clinical attachment level, more apically (Fig. 7). The 3<sup>rd</sup> point – crestal gingival thickness (CGT) – was localized more apically on the keratinized gingiva and represented the thickness of the gingiva attached to the alveolar ridge. The head of the probe was placed with its upper border at the mucogingival junction, more coronally (Fig. 8). The 4<sup>th</sup> point called mucosa thickness (MGT) was placed on the lining mucosa. The head of the probe was positioned with its lower border more apically of the mucogingival junction (Fig. 9). At the FGT point, the head of the probe was in partial contact with the free gingiva, but as signals are produced by the whole surface of the probe, the examination enabled thickness measurement of the free gingiva. All trials were carried out without local anesthesia. The clinical examination was entirely performed in 12 points (4 points for each tooth), with 5 attempts each (automatic 10-fold measurement of every attempt, 50 values in total), by 3 examiners (Fig. 6). The chlorhexidine 0.2% bioadhesive gel (Elugel® – 40 mL gel tube; Pierre Fabre Oral Care, Boulogne-Billancourt, Paris, France) was used to allow conduction of the ultrasonic impulses.

## Statistical analysis

Data analysis was performed using statistical software STATISTICA v. 10.0 (StatSoft Polska Sp. z o.o., Kraków, Poland). The statistical units in the analysis were: patient, dentogingival units, single points, and operators. The analysis of variance (ANOVA) method was used to quantify the repeatability and reproducibility percentage (%R&R). The mean, median, standard deviation (SD), and coefficient of variation (CV) were calculated. A p-value  $\leq 0.05$  was considered statistically significant.

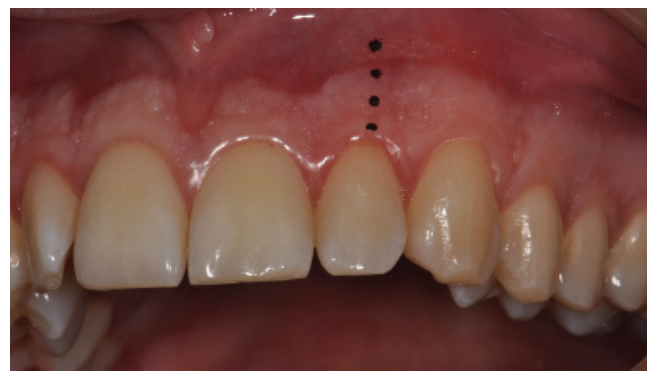

Fig. 5. Four new points marked on the surface of soft tissue of the lateral incisor

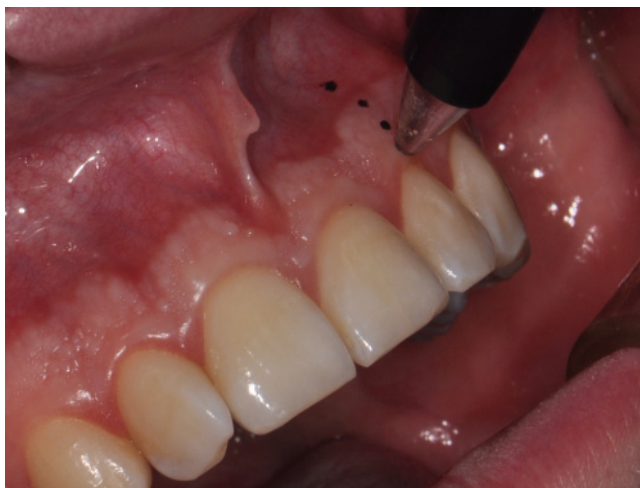

Fig. 6. Examination of the free gingival thickness (FGT point) with the ultrasonic probe

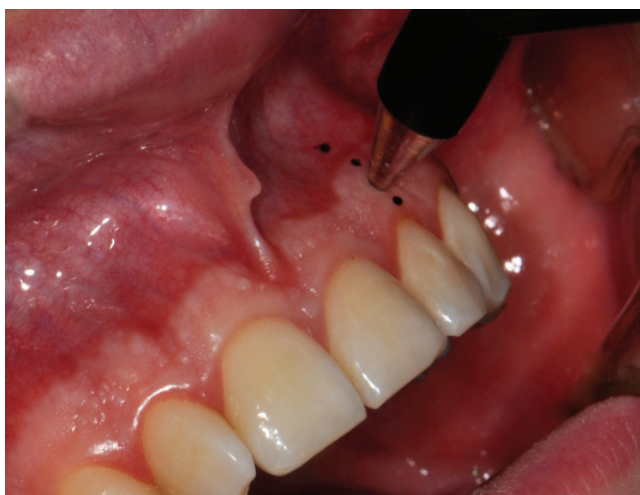

Fig. 7. Examination of the supracrestal gingival thickness (SGT point) with the ultrasonic probe

was variable to the observer, i.e., 5.4%, 6.5% and 6.4%. Interobserver reproducibility varied from 0.8% to 13.4%. The median of the reproducibility of all measurements was 8.1%.

Considering the results related to the dentogingival units, the combined R&R for tooth 21 was 7.43%, for tooth 22 – 12.48% and for tooth 23 – 4.67%. All the results were acceptable or conditionally acceptable, but still very close to 10%. The combined R&R ratio for all measurements carried out by 3 researchers was 8.4% (CV) (Table 4). Following the results obtained with PIROP in this trial, this device can be placed in the first group of acceptance according to the MSA standards.

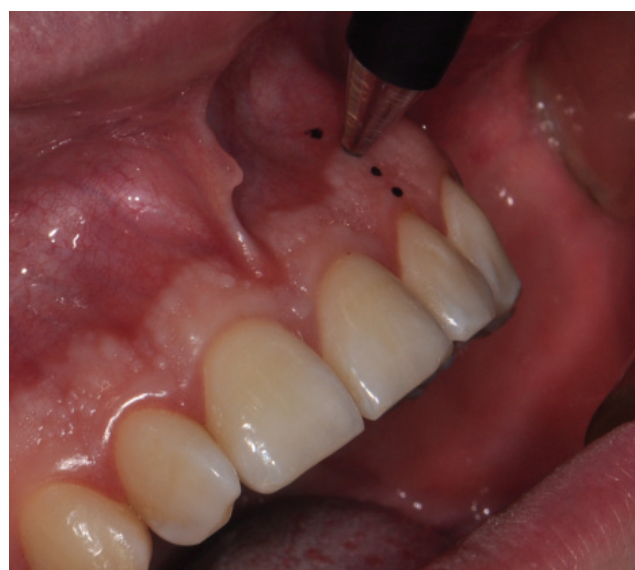

Fig. 8. Examination of the crestal gingival thickness (CGT point) with the ultrasonic probe

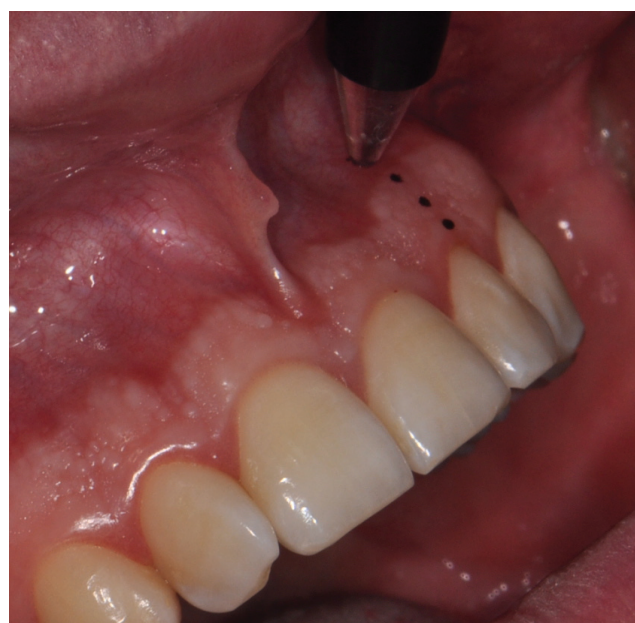

Fig. 9. Examination of the mucosa thickness (MGT point) with the ultrasonic probe

## Results

In the 1<sup>st</sup> stage, the master sample was chosen and the preclinical part was conducted. There was no statistical difference ( $p = 0.732$ ) between ultrasonic measurements made by 3 operators with the PIROP device, bone sounding technique and the real value as a control, which is presented in Table 2.

The 2<sup>nd</sup> stage was a clinical trial performed on 1 generally and periodontally healthy volunteer. Three teeth were used in the examination. Four measurement points were marked on soft tissue for every chosen tooth. Three examiners took measurements 5 times at 1 point. The data corresponding to the different points and operators is presented in Table 3.

The average intraobserver CV was 6.6% (from 1.9% at the SGT point in researcher 1 to 13.6% at the SGT point in researcher 2). Nevertheless, the median of CV

**Table 2.** Average values of preclinical gingival thickness (GT) measurements carried out by 3 operators

GT value [mm]	USG 1	USG 2	USG 3	BS	RV	p-value
mean	3.39	3.36	3.38			
SD	0.14	0.13	0.14	3.44	3.40	0.732

USG 1 – operator 1; USG 2 – operator 2; USG 3 – operator 3; BS – bone sounding; RV – real value (measured directly by the caliper); SD – standard deviation.

**Table 3.** Intraoperator coefficient of variance (CV) repeatability and interoperator reproducibility for individual gingival thickness (GT) measurements

Tooth No.	GT measurement point	Researcher 1			Researcher 2			Researcher 3			Reproducibility [%]
		mean of GT [mm]	SD	CV [%]	mean of GT [mm]	SD	CV [%]	mean of GT [mm]	SD	CV [%]	
21	FGT	0.86	0.08	9.4	0.88	0.10	10.9	0.88	0.06	7.4	1.4
	SGT	1.59	0.17	10.5	1.75	0.24	13.6	1.68	0.20	11.8	8.0
	CGT	0.69	0.04	5.1	0.89	0.08	9.6	0.79	0.04	5.3	10.1
	MGT	0.82	0.03	3.1	0.79	0.04	4.7	0.81	0.05	6.7	1.5
22	FGT	0.61	0.03	5.3	0.79	0.04	5.5	0.84	0.05	6.0	11.9
	SGT	1.37	0.03	1.9	1.13	0.04	3.5	1.39	0.03	2.1	13.4
	CGT	0.88	0.05	5.5	0.84	0.06	7.6	0.87	0.06	7.4	1.8
	MGT	0.57	0.06	9.8	0.54	0.03	5.6	0.70	0.07	9.2	8.4
23	FGT	0.76	0.02	2.8	0.71	0.05	6.5	0.74	0.04	6.0	2.3
	SGT	1.70	0.07	4.2	1.62	0.11	6.6	1.52	0.13	8.4	9.3
	CGT	0.61	0.05	7.6	0.77	0.05	6.9	0.75	0.04	5.6	8.3
	MGT	0.99	0.06	6.1	1.01	0.06	5.8	1.00	0.03	3.5	0.8
Median	–	–	–	5.4	–	–	6.5	–	–	6.4	8.1

FGT – free gingival thickness; SGT – supracrestal gingival thickness; CGT – crestal gingival thickness; MGT – mucosa thickness; SD – standard deviation; CV – coefficient of variation; 21 – central incisor; 22 – lateral incisor; 23 – canine.

**Table 4.** The combined repeatability and reproducibility (R&R) of the ultrasonic measurement at the central incisor (21), lateral incisor (22) and canine (23)

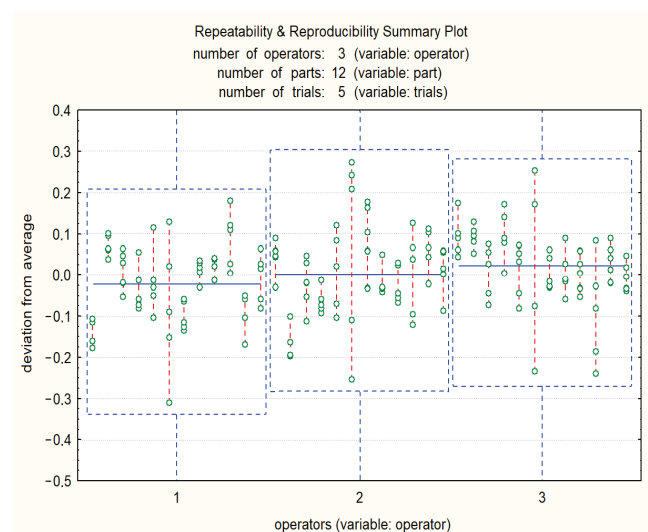
Tooth No.	Estimated	90% lower CI	90% upper CI	Combined R&R [%]
21	0.120	0.115	0.221	7.43
22	0.110	0.097	0.298	12.48
23	0.092	0.085	0.103	4.67
Total	0.107	0.105	0.141	8.39

CI – confidence interval.

The summary plot in Fig. 10 shows 3 boxes successively for each researcher. In each box, there are 12 columns corresponding to the points of measurement (from the left: 1 – FGT tooth 21; 2 – SGT tooth 21; 3 – CGT tooth 21; 4 – MGT tooth 21; 5 – FGT tooth 22; 6 – SGT tooth 22; 7 – CGT tooth 22; 8 – MGT tooth 22; 9 – FGT tooth 23; 10 – SGT tooth 23; 11 – CGT tooth 23; 12 – MGT tooth 23). In each column, 5 values of the deviation from average are marked with green points. Considering the results in relation to the single points, the deviation from the average value of the measurement at the SGT point in the lateral incisor is visibly higher than in the other points. The shape of the root of the upper lateral incisor is biconcave and narrow, which may cause a nonparallel reflection of the signal at the surface. This may indicate that the method used requires experienced examiners, who are able to assess the value provided by the device.

## Discussion

Gingival thickness measurement with an ultrasound has been recognized as a reliable, reproducible and non-invasive method.<sup>8,9,17,26</sup> The authors compared results obtained by ultrasonic, invasive<sup>8–10</sup> and CT methods.<sup>17</sup> Slak et al. used a phantom made from materials with similar



**Fig. 10.** Deviations from average for 3 operators, 5 times at each measurement point  
Staring from the left: 1 – operator 1; 2 – operator 2; 3 – operator 3.

properties of ultrasound wave transmission to bone and gingival tissue.<sup>26</sup> Ten places were marked on a polyurethane surface resembling the gingiva; on each of these points, the thickness was measured with an ultrasound method and an invasive method using an endodontic K-file, with individual measurements taken directly. An optical microscope was used to calculate the thickness of the polyurethane based on the direct method. In experimental conditions using an ultrasound and transgingival probing method, 10 measurements of the GT of the swine maxilla were taken at each of 4 GT1 points (midway through the keratinized gingiva) and 4 GT2 points (2 mm apically from the mucogingival junction). Measurements of the thickness of polyurethane by means of 3 methods produced results that were very similar to one another. However, the greatest inaccuracies when compared to direct measurements occurred with the invasive method. Most of the GT values measured on the swine mandible using the invasive method were higher than the values recorded with ultrasonography. The greatest inaccuracies recorded with the ultrasound method concerned measurements of the mobile mucosa in one of the GT2 points, and amounted to 10.3%. The data obtained in clinical conditions are confirmed by the occurrence of smaller measuring deviations noted with ultrasound biometrics compared with the invasive method.

Eghbali et al. measured the palatal masticatory mucosa of 4 human cadavers using an ultrasonic device with a measurement frequency of 5 MHz, with a transducer probe of 4 mm in diameter.<sup>17</sup> To assess the validity of the ultrasonic device, one of the researchers performed GT measurements of 100 sites marked on the mucosa surface with copper wires. The other researcher performed CT and compared the results obtained by ultrasonic and imaging methods. A strong correlation between both methods used were observed; however, the ultrasonically measured GT was significantly lower than GT measured with micro-CT. To evaluate the reproducibility of 1 researcher, the ultrasonic GT measurement of the 50 sites was performed twice. There was no statistically significant difference between the former and the latter GT results. Moreover, a strong positive correlation was observed between the 2 sets of results.

Müller et al. assessed the degree of repeatability of the ultrasonic method of measuring GT using a 5 MHz device in 33 volunteers at all dentogingival units on the tooth/occasion and subject/patient level.<sup>29</sup> Patients with gingivitis were examined 3 times in 2 weeks with respect to each tooth on the clinical attachment level. The highest repeatability level (95%) was obtained in the anterior teeth and premolars.

In the studies conducted by Bednarz et al., 30 patients with healthy periodontal tissue were tested.<sup>10</sup> Measurements of periodontal soft tissue were taken in each patient at 2 measuring points GT1 and GT2, around each of 10 teeth in the maxilla and 10 teeth in the mandible, covering pre-

molars, canines and incisors. The average GT achieved with the invasive method was significantly greater than the values recorded with an ultrasound, amounting to 0.828 mm and 0.784 mm, respectively. Similarly, the average GT values noted at points GT1 and GT2 were higher with the invasive method. The biggest differences in measurements at these points between the invasive and ultrasound methods were observed in the lowest values <0.5 mm.

Müller et al. obtained higher values of ultrasonic GT measurements than those achieved with the invasive method,<sup>29</sup> whereas Eghbali et al. obtained values lower than in the case of micro-CT.<sup>17</sup> In our research, verification of the stability, repeatability and reproducibility of GT measurement using an ultrasonic device was carried out in accordance with the guidelines of MSA.<sup>27</sup> Appropriate conditions for carrying out the R&R test should be provided. The measurement process should be precisely described and intelligible, investigators should be well-trained and the device should be calibrated. The frequency of measurements has to be determined. The environmental conditions must be comparable for all the trials. Our study meets all the mentioned criteria. According to the authors, the most important element of the study is the calibration by the researchers of the pressure with which the head of the probe is applied; it should not exceed 25 g. Firstly, self-control training on the porcine jaw placed on the laboratory scale was performed. Ten results that met the above-mentioned criterion allowed the researcher to proceed to the next phase of the study, in which the pressure was controlled by other researcher. Ten correct measurements (with a pressure lower than 25 g) in a row were considered as a positive completion of the calibration.

The median of the reproducibility of all measurements was 8.1%. Nevertheless, the median of CV was variable to the observer, i.e., 5.4%, 6.5% and 6.4%. The overall combined R&R parameter for all the values indicates that ultrasonic measurements of GT are repeatable within 1 examiner and reproducible between 3 of the examiners.

Müller and Könönen underlined that the GT measurement is assessed mostly with the variables on the tooth level, not the patient level.<sup>30</sup> In the previous experiments, the diameter of the probe used was about 4 mm.<sup>17,29</sup> This size did not allow the researcher to place the probe exactly where planned. The present experiment visualized the differences between the values for the supracrestal and crestal tissue. It can be achieved using a probe with the head diameter of 1.7 mm, which makes it possible to measure GT in a few points with greater accuracy. Differences within R&R for individual dentogingival units may occur because of the curvature of the roots. It is particularly visible in FGT and SGT of the lateral incisor, whose root is very thin and in a biconcave shape. This may cause problems with placing the probe perpendicularly to the root surface as the signal goes back straight to the probe. The first 2 parameters of free gingiva and supracrestal gingiva,

in which the signal is bouncing from the root surface, show the highest R&R value. This proves that knowledge of anatomy and experience of the examiner are the key factors in the proper conduct of the examination, which is consistent with the conclusions of others.<sup>10,17,28–30</sup> To avoid the mentioned bias in the future, flat plastic may be placed into the sulcus to create a flat reflection surface and ensure a perfect measurement of the FGT point.

Non-invasive ultrasonic biometer GT measurements are crucial in periodontology as well as in other fields of dentistry. Knowing the value of GT is necessary to predict the functional and esthetical outcomes as well as to minimize possible complications.

It is widely known that the quality and quantity of soft tissue around the teeth and implants matters. In the era of body worship and increasing esthetic expectations, it is not enough to restore the function of the stomatognathic unit. To improve the functional as well as the esthetic results of the treatment, a precise diagnostic tool to assess soft tissue is needed. Moreover, knowledge of the anatomy of each dentogingival unit can make the treatment safer for a patient and more predictable for a clinician. This trial showed that the ultrasonic method of measuring GT can be used as a basis for a diagnosis and clinical decisions.

## Conclusions

The obtained results in repeatability and reproducibility prove the good recognition of methodology as well as the usefulness of the device. Within the limits of the study, the 20 MHz A-Scan ultrasonic device may be used to measure GT in the oral cavity. The study is an important basis for a large clinical study with more participants.

## References

- Baum G, Greenwood I, Slawski S, Smirnow R. Observation of internal structures of teeth by ultrasonography. *Science*. 1963;139(3554):495–496.
- Ślak B, Ambroziak A, Strumban E, Maev RG. Enamel thickness measurement with a high frequency ultrasonic transducer-based hand-held probe for potential application in the dental veneer placing procedure. *Acta Bioeng Biomech*. 2011;13(1):65–70.
- Culjat MO, Singh RS, Brown ER, Neurgaonkar RR, Yoon DC, White SN. Ultrasound crack detection in a simulated human tooth. *Dentomaxillofac Radiol*. 2005;34(2):80–85.
- Matalon S, Feuerstein O, Calderon S, Mittleman A, Kaffe I. Detection of cavitated carious lesions in approximal tooth surfaces by ultrasonic caries detector. *Oral Surg Oral Med Oral Pathol Oral Radiol Endod*. 2007;103(1):109–113.
- Maity I, Kumari A, Shukla AK, Usha HL, Naveen DN. Monitoring of healing by ultrasound with color power doppler after root canal treatment of maxillary anterior teeth with periapical lesions. *J Conserv Dent*. 2011;14(3):252–257.
- Adeyemo WL, Akadiri OA. A systematic review of the diagnostic role of ultrasonography in maxillofacial fractures. *Int J Oral Maxillofac Surg*. 2011;40(7):655–661.
- Cakir-Ozkan N, Sarikaya B, Erkorkmaz U, Aktürk Y. Ultrasonographic evaluation of disc displacement of the temporomandibular joint compared with magnetic resonance imaging. *J Oral Maxillofac Surg*. 2010;68(5):1075–1080.
- Eger T, Müller HP, Heinecke A. Ultrasonic determination of gingival thickness. Subject variation and influence of tooth type and clinical features. *J Clin Periodontol*. 1996;23(9):839–845.
- Müller HP, Schaller N, Eger T, Heinecke A. Thickness of masticatory mucosa. *J Clin Periodontol*. 2000;27(9):431–436.
- Bednarz W, Zielińska A. Ultrasonic biometer and its usage in an assessment of periodontal soft tissue thickness and comparison of its measurement accuracy with a bone sounding method. *Dent Med Probl*. 2011;48(4):481–489.
- Marotti J, Heger S, Tinschert J, et al. Recent advances of ultrasound imaging in dentistry – a review of the literature. *Oral Surg Oral Med Oral Pathol Oral Radiol*. 2013;115(6):815–832.
- Puzio M, Błaszczyszyn A, Hadzik J, Dominiak M. Ultrasound assessment of soft tissue augmentation around implants in the aesthetic zone using a connective tissue graft and xenogeneic collagen matrix – 1-year randomised follow-up. *Ann Anat*. 2018;217:129–141.
- Lodder WL, Teertstra HJ, Tan IB, et al. Tumour thickness in oral cancer using an intra-oral ultrasound probe. *Eur Radiol*. 2011;21(1):98–106.
- Salmon B, Le Denmat D. Intraoral ultrasonography: Development of a specific high-frequency probe and clinical pilot study. *Clin Oral Investig*. 2011;16(2):643–649.
- Hwang D, Wang HL. Flap thickness as a predictor of root coverage: A systematic review. *J Periodontol*. 2006;77(10):1625–1634.
- Yared KF, Zenobio EG, Pacheco W. Periodontal status of mandibular central incisors after orthodontic proclination in adults. *Am J Orthod Dentofacial Orthop*. 2006;130(1):6.e1–8.
- Eghbali A, De Bruyn H, Cosyn J, Kerckaert I, Van Hoof T. Ultrasonic assessment of mucosal thickness around implants: Validity, reproducibility, and stability of connective tissue grafts at the buccal aspect. *Clin Implant Dent Relat Res*. 2014;18(1):51–61.
- Matys J, Świder K, Flieger R. Laser instant implant impression method: A case presentation. *Dent Med Probl*. 2017;54(1):101–106.
- Akcali A, Trullenque-Eriksson A, Sun C, Petrie A, Nibali L, Donos N. What is the effect of soft tissue thickness on crestal bone loss around dental implants? A systematic review. *Clin Oral Implants Res*. 2016;28(9):1046–1053.
- Suárez-López Del Amo F, Lin GH, Monje A, Galindo-Moreno P, Wang HL. Influence of soft tissue thickness on peri-implant marginal bone loss: A systematic review and meta-analysis. *J Periodontol*. 2016;87(6):690–699.
- Vervaeke S, Dierens M, Besseler J, De Bruyn H. The influence of initial soft tissue thickness on peri-implant bone remodeling. *Clin Implant Dent Relat Res*. 2016;16(2):238–247.
- Ronay V, Sahrman P, Bindl A, Attin T, Schmidlin PR. Current status and perspectives of mucogingival soft tissue measurement methods. *J Esthet Restor Dent*. 2011;23(3):146–157.
- Egreja AM, Kahn S, Barceleiro M, Bittencourt S. Relationship between the width of the zone of keratinized tissue and thickness of gingival tissue in the anterior maxilla. *Int J Periodontics Restorative Dent*. 2012;32(5):573–579.
- Barriviera M, Duarte WR, Januário AL, Faber J, Bezerra AC. A new method to assess and measure palatal masticatory mucosa by cone-beam computerized tomography. *J Clin Periodontol*. 2009;36(7):564–568.
- Ueno D, Sato J, Igarashi C, et al. Accuracy of oral mucosal thickness measurements using spiral computed tomography. *J Periodontol*. 2011;82(6):829–836.
- Ślak B, Daabous A, Bednarz W, Strumban E, Maev RG. Assessment of gingival thickness using an ultrasonic dental system prototype: A comparison to traditional methods. *Ann Anat*. 2015;199:98–103.
- Larsen GA. Measurement system analysis in a production environment with multiple test parameters. *Qual Eng*. 2003;16(2):297–306.
- Bednarz W. New possibilities of periodontal tissue diagnostics by using ultrasound biometry. *e-Dentico*. 2016;1(59):48–63.
- Müller HP, Barrieshi-Nusair KM, Könönen E. Repeatability of ultrasonic determination of gingival thickness. *Clin Oral Investig*. 2007;11(4):439–442.
- Müller HP, Könönen E. Variance components of gingival thickness. *J Periodontol Res*. 2005;40(3):239–244.



# Early postoperative healing following guided tissue regeneration in aggressive periodontitis patients

## Wczesne gojenie pozabiegowe po sterowanej regeneracji tkanek u pacjentów z agresywnym zapaleniem przyzębia

Bartłomiej Górski<sup>A–D</sup>, Tomasz Kaczyński<sup>B,C</sup>, Andrzej Miskiewicz<sup>B,C</sup>, Renata Górka<sup>E,F</sup>

Department of Periodontology and Oral Diseases, Medical University of Warsaw, Poland

A – research concept and design; B – collection and/or assembly of data; C – data analysis and interpretation; D – writing the article; E – critical revision of the article; F – final approval of the article

Dental and Medical Problems, ISSN 1644-387X (print), ISSN 2300-9020 (online)

*Dent Med Probl.* 2018;55(3):289–297

### Address for correspondence

Bartłomiej Górski  
E-mail: bartek\_g3@tlen.pl

### Funding sources

None declared

### Conflict of interest

None declared

Received on April 23, 2018  
Reviewed on July 20, 2018  
Accepted on August 10, 2018

### Abstract

**Background.** In order to regenerate periodontal tissues, necessary conditions for this process must be created during surgery, primarily by allowing uninfected adhesion of the clot to the root surface, and then its stable position in the defect.

**Objectives.** The aim of this secondary analysis was to evaluate early postoperative healing of papillary incisions and its correlations with patient-, site- and technique-related factors following guided tissue regeneration (GTR) in treatment of intrabony defects in patients with aggressive periodontitis (AgP).

**Material and methods.** The analysis included the data from 25 patients and 59 treatment sites. Surgical treatment consisted of using grafts together with collagen membranes. Post-operative healing was assessed 1 week and 2 weeks after GTR using the Early Wound-Healing Index (EHI).

**Results.** Early Wound-Healing Index values ranged from 1 (complete flap closure and primary healing) to 4 (incomplete flap closure, partial tissue necrosis, secondary healing). After 1 week, primary healing (EHI ≤ 3) was observed in 55 sites, and secondary healing (EHI = 4) in 4 sites. After 2 weeks, the values were 45 and 14, respectively. No correlations between EHI and patient-related factors were found. However, 1-rooted teeth, sites with thin phenotype and the presence of gingival recessions were associated with impaired healing (higher EHI recordings and secondary healing), as was analyzed in a multiple regression model.

**Conclusions.** Site-related factors may impinge on the early postoperative healing of papillary incisions succeeding GTR in AgP patients.

**Key words:** wound healing, aggressive periodontitis, guided tissue regeneration, papilla preservation flap

**Słowa kluczowe:** gojenie się ran, agresywne zapalenie przyzębia, sterowana regeneracja tkanek, płat oszczędzający brodawkę

DOI  
10.17219/dmp/94204

### Copyright

© 2018 by Wrocław Medical University  
and Polish Dental Society  
This is an article distributed under the terms of the  
Creative Commons Attribution Non-Commercial License  
(<http://creativecommons.org/licenses/by-nc-nd/4.0/>)

## Introduction

The main features of aggressive periodontitis (AgP) are rapid loss of connective tissue attachment and alveolar bone, the presence of dental plaque disproportionate to the severity of the disease, occurrence in individuals without coexisting general diseases, and familial aggregation of the disease.<sup>1</sup> There is genetic susceptibility depending on many genes, and only its interaction with environmental factors (periopathogens and other acquired risk factors) determines the occurrence of symptoms of periodontitis and/or the pace of its clinical course. Aggressive periodontitis, as any complex disease, is characterized by the interaction of multiple gene loci with various alleles, and only the whole complex interacts with environmental factors.<sup>2</sup> Its prevalence in the population is estimated at 0.5–2.5%.<sup>3</sup> Treatment of AgP depends on non-surgical treatment; however, vertical intrabony defects in patients with AgP are indications for the implementation of a chosen regenerative strategy.

At the core of tissue regeneration are complex processes and interactions at the molecular and cellular level. Appropriate preprocedural management, a proper surgical technique and follow-up care are prerequisites that can promote proper healing. For the periodontal regeneration to take place, necessary conditions must be created during the surgery, primarily by allowing uninfected adhesion of the clot to the root surface, and then its stable position in the defect.<sup>4</sup> Dehiscence of the wound within the first weeks after surgical treatment may disturb the cascade of reactions guiding the course of regenerative processes. In addition, in the case of the use of biomaterials and barrier membranes, impaired healing may lead to partial or total loss of the implant material and even to infection of the barrier membrane. In this context, the role of non-disturbed primary healing is well-known, especially in the first few weeks of guided tissue regeneration (GTR).<sup>5,6</sup>

The most frequently highlighted factors, directly correlated with the level of obtained results, are the selection of surgical technique for individual clinical situation and performing the procedure in accordance with the principles of minimally invasive surgery.<sup>7</sup> Conducting a regenerative procedure requires attention at every stage, starting with the appropriate design of incisions and flap preparation range, and ending with the right stitching technique. In recent years, there has been a significant change in understanding of the influence of surgical techniques on tissue healing, and some flap properties, such as its thickness and vascular sources, achieved recognition.<sup>8</sup> Current treatment techniques are based on tissue healing biology, which excludes formation of extensive surgical wounds that can worsen the conditions for natural regeneration of tissues.<sup>9</sup> The principles of minimally invasive periodontal surgery have been modified by Cortellini et al., who proposed novel techniques for performing incisions that save interdental papilla to further improve and

maintain flap closure during wound healing.<sup>10,11</sup> If the interproximal space is wider than 2 mm, a horizontal incision should be performed at the base of the papilla, which was described as modified papilla preservation technique (MPPT).<sup>10</sup> The interproximal space with a width up to 2 mm obliges to make oblique incision maximally close to the tip of the papilla, but not through its peak; this technique is called simplified papilla preservation flap (SPPF).<sup>11</sup> Blood flow tests showed that tissue vascularization after SPPF is faster than after incisions typical for Modified Widman Flap (MWF), i.e., through papilla peaks. The technical aspect of minimally invasive surgical methods that promote tissue healing has evident effect on the clinical effects of treatment.

Many scientific papers have described the importance and role of various factors affecting early healing after regenerative procedures on bone defects in patients with periodontitis.<sup>12,13</sup> Variables were assessed at the level of the patient or the tooth (the treated site). However, none of the papers assessed factors related to the occurrence of complications, such as wound dehiscence after GTR in patients with AgP.

This study aimed at evaluating the early postoperative healing of the papillary incisions, as described by the Early Wound-Healing Index (EHI), and its correlations with patient-, site- and technique-related factors following GTR in the treatment of intrabony defects in patients with AgP.<sup>14</sup>

## Material and methods

The study is a secondary analysis of data extracted from 3 randomized clinical trials conducted at the Department of Periodontology and Oral Diseases of Medical University of Warsaw, Poland, which assessed different regenerative strategies in patients with AgP. The study received the approval by the institutional review board (KB/135/2014; KB/37/2016; KB/209/2017). All clinical procedures were carried out in accordance with the Helsinki Declaration of 1975, as revised in Tokyo in 2004. Every patient signed a written informed consent form.

## Patient and defect eligibility

The inclusion criteria were as follows: 1. diagnosis of AgP in line with definition of American Academy of Periodontology<sup>1</sup>; 2. no systemic diseases; 3. taking no medications affecting periodontal status; 4. no pregnancy or lactation; 5. no cigarette smoking; 6. history of periodontitis in parents or siblings; 7. presence of at least 1 tooth with probing pocket depth (PPD)  $\geq 6$  mm, clinical attachment level (CAL)  $\geq 5$  mm and intrabony defect  $\geq 3$  mm as detected in periapical radiographs; 8. full-mouth plaque index (FMPI)  $\leq 20\%$ ; 9. bleeding on probing index (BoP)  $\leq 20\%$ ; 10. tooth had to be vi-

tal or properly treated; 11. no furcation involvement; 12. the width of keratinized tissue on the labial/buccal site of the tooth  $\geq 2$  mm.

## Presurgery procedures

For each patient, a full-mouth disinfection (FMD) protocol was implemented, which involved simultaneous non-surgical treatment of all the pockets during 1 visit (scaling and root debridement) using hand and ultrasonic tools. Mechanical debridement treatments were combined with the use of antiseptics in the form of rinses containing 0.2% chlorhexidine or a gel with 1% chlorhexidine. In addition, all patients received antibiotics (amoxicillin 500 mg + metronidazole 250 mg 3 times per day for 1 week). Individual instructions were also given on maintaining optimal oral hygiene.

## Clinical and radiographic recordings

After 6–9 weeks from scaling and root debridement, clinical parameters were carefully evaluated and they included the following: 1. dichotomous (yes/no) FMPI according to O’Leary et al. on 4 tooth surfaces (i.e., distal, buccal, mesial, and lingual).<sup>15</sup> The index was determined by dividing the number of surfaces with plaque by the number of all studied surfaces; 2. dichotomous (yes/no) BoP index according to Ainamo and Bay.<sup>16</sup> Bleeding was assessed at 6 points for each tooth (i.e., distobuccal, buccal, mesiobuccal, distolingual, lingual, and mesiolingual). The index was determined by dividing the number of bleeding points by the number of all assessed points; 3. PPD in 6 points of each tooth as a distance from the gingival margin to the bottom of the pocket; 4. CAL in 6 points of each tooth as a distance from the cemento-enamel junction (CEJ) to the bottom of the pocket; 5. gingival recession (GR) in buccal point of each tooth as a distance from CEJ to the gingival margin; 6. width of keratinized tissue (WKT) was evaluated as a distance from the gingival margin to the mucogingival junction evaluated mid-buccally. Mucogingival junction was demarcated by staining the mucogingival complex with iodine solution; 7. gingival phenotype was categorized as thin if gingival thickness was  $\leq 1$  mm, and as thick if gingival thickness was  $> 1$  mm. Gingival thickness was measured 2 mm apically to the gingival margin by perpendicularly inserting a 10-millimeter endodontic spreader with a silicone stopper until the alveolar bone or root surface was reached. An electronic caliper (YATO® YT-7201; Toya, Wrocław, Poland) was used to assess gingival thickness indicated on the endodontic instrument with a rubber stop; 8. interdental contact point was recorded as present or absent. All the abovementioned clinical measurements were registered by 1 calibrated examiner using a graded periodontal probe (UNC probe 15 mm; Hu-Friedy, Chicago, USA).

Standardized intraoral radiographs were taken for each site with film holders and paralleling cone technique using an X-ray unit operating at 70 kV, 4 mA and 0.1-second exposure time. The radiographs were evaluated using Planmeca Romexis® Viewer software (Planmeca, Helsinki, Finland). Some anatomical landmarks, such as CEJ, alveolar crest (AC) and base of the defect (BD) were selected and 2 auxiliary lines were drawn, 1<sup>st</sup> in the tooth axis (AUX1) and 2<sup>nd</sup> (AUX2) from AC, perpendicularly to AUX1. The following measurements were obtained: 1. radiographic defect depth (DD) as a distance from the spot where AUX2 crossed the CEJ–BD line to the base of the defect; 2. radiographic defect angle (RVG angle) between the intersection of CEJ–BD line of the tooth and the delimitation of the wall of the defect; 3. distance from CEJ to AC (alveolar crest position – ACP). Subjects who fulfilled all of the inclusion criteria were enrolled into surgical treatment.

## Surgical treatment and intrasurgery evaluation

All defects were treated in line with guidelines of minimally invasive surgery. The procedure was started with incisions in the interdental spaces. The choice of incision was dependent on the width of the interdental space. In the case of narrow spaces, an SPPF incision was used, and in the case of wide spaces, MPPT. In the spaces between molars and teeth with difficult access, SPPF incisions were made regardless of the width of the space. These cuts went further into intrasulcular incisions. The extent of the incision depended on the extent of the defect. If necessary, vertical cuts were prepared. The full-thickness buccal flaps were then reflected. Subsequently, the interdental papilla were separated from the bone base using a scalpel and the palatal flap was prepared. The next step was to remove the granulation from cavities and to perform scaling and root planing (SRP) using hand and ultrasonic instruments.

After surgical debridement, the following evaluation was made: 1. depth of the defect as the distance from the alveolar crest to the deepest point in the defect; 2. width of the defect as the distance from the alveolar crest to the root surface; 3. the number of remaining walls of the defects. Defects were categorized as 1-, 2- or 3-wall.

Intrabony defects were filled with biomaterials (Bio-Oss®; Geistlich Biomaterials, Princeton, USA / Gen-Os®; TecnoSS, Turin, Italy / allogenic bone grafts; Department of Transplantology and Cell Tissue Bank, Medical University of Warsaw, Poland) and covered with collagen membrane (Bio-Gide®; Geistlich Biomaterials). In order to advance the flap coronally without tension, a periosteal incision was performed at its base. The interdental spaces were closed with vertical modified mattress sutures (5/0 polypropylene monofilament suture, Prolene® 5/0 16 mm 3/8; Ethicon, Somerville, USA), and vertical incisions with simple sutures. Primary flap closure was obtained in all sites.

## Postsurgery procedures and assessments

After the procedure, patients were administered 600 mg of ibuprofen; the next the same dose was taken by patients after 8 h. Patients were then given postoperative recommendations that included: 1. rinsing the mouth with 0.2% chlorhexidine solution (Curasept® ADS 220; Curaden Polska Sp. z o.o., Wrocław, Poland) 3 times daily for 1 min; 2. no brushing of the treatment area; 3. a soft, mild diet; 4. limiting physical effort; 5. control visit after 7 and 14 days. During the follow-up visits, wound healing in the interdental spaces was evaluated and the supragingival plaque was removed from the entire dentition using prophylaxis brushes and gel containing 1% chlorhexidine (Curasept ADS 100; Curaden Polska Sp. z o.o.). The sutures were removed after 2 weeks.

Healing assessment was based on EHI, as categorized in the following grades: 1. EHI = 1 – complete flap closure, no fibrin line in the interproximal area; 2. EHI = 2 – complete flap closure, thin fibrin line in the interproximal area; 3. EHI = 3 – complete flap closure, fibrin clot in the interproximal area; 4. EHI = 4 – incomplete flap closure, partial necrosis of the interproximal tissue; 5. EHI = 5 – incomplete flap closure, complete necrosis of the interproximal tissue (Fig. 1).<sup>14</sup> EHI ≤ 3 was regarded as primary healing, while EHI ≥ 4 as secondary healing.

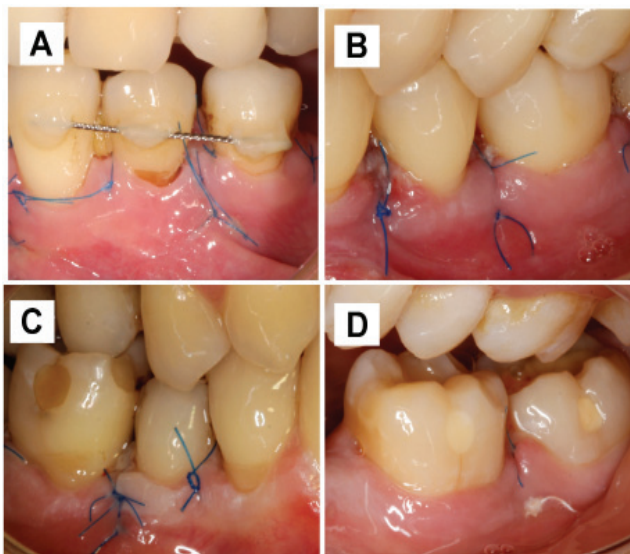


Fig. 1. Early Wound-Healing Index (EHI). A – EHI = 1 of the papilla between teeth 35 and 34: complete flap closure and no fibrin line in the interproximal area; B – EHI = 2 of the papilla between teeth 36 and 35: complete flap closure and thin fibrin line in the interproximal area; C – EHI = 3 of papilla between teeth 46 and 45: complete flap closure and fibrin clot in the interproximal area; D – EHI = 4 of papilla between teeth 37 and 36: incomplete flap closure and partial necrosis of the interproximal tissue

## Statistical analysis

For the statistical analysis, measurements at the site with the greatest presurgical CAL value were used. Data was expressed as mean ± standard deviation (SD).

Descriptive analyses on early postoperative healing were based on the entire defect population ( $n = 59$ ). The EHI was the primary outcome variable. The patient-related (age, gender, FMPI, and BoP) and site-related parameters (tooth type, tooth position, PPD, CAL, GR, presence of interdental contact point, width of interdental space, WKT, phenotype, DD, RVG angle, ACP, defect configuration, defect depth and width), together with technical aspects (presence of vertical incision, papilla preservation technique) were considered to be independent variables. Patients were divided according to papilla preservation technique (MPPT or SPPF) to evaluate which parameters were associated with wound healing after 1 and 2 weeks. Analyses were carried out for sites being categorized using the EHI. The EHI was treated as a binomial variable. Analyses were carried out for sites that were divided as EHI ≤ 2 or EHI ≥ 3, as well as by comparing sites with primary healing (EHI ≤ 3) with sites that presented secondary healing (EHI ≥ 4).

Relationships between the abovementioned variables and EHI depending on papilla preservation technique were evaluated using Pearson's correlation coefficient. Attributes of patients (such as age and sex) were assigned to teeth, but patients were not treated as experimental units. All analyses were conducted at site level, not at patient level. For some patients, only 1 site was assessed, but the general assumption was that analyses are at site level. Subsequently, statistically significant factors were entered into a logistic regression model and odds ratios (ORs) were calculated. The valuation of predictive power of independent variables in logistic regression was based only on ORs and p-values.

Statistical analysis was performed using STATISTICA v. 13 (StatSoft Inc., Tulsa, USA). Any p-values of less than 0.05 were considered statistically significant. The strength of correlations was determined by R value; if it was >0.70, the correlation was considered strong; if it was 0.40–0.70, the correlation was considered moderate; and if it was <0.40, the correlation was considered weak.

## Results

The data and information on 25 patients (18 females, mean age  $35.1 \pm 11.07$  years, and 7 males, mean age  $39.8 \pm 4.5$ ) extracted from 3 previous studies were included in this secondary analysis. Patients presented with 59 intraosseous defects and 45 surgical procedures were carried out. Four patients presented with 1 defect, 14 patients presented with 2 defects, 4 patients presented with 3 defects, and 3 patients presented with 5 defects. Defect characteristics are shown in Table 1.

After 1 week, the EHI was  $2.18 \pm 0.97$ , while after 2 weeks the EHI was  $1.92 \pm 1.39$  and ranged from 1.0 to 4.0. Fifty-five sites demonstrated primary healing (EHI: 1–3) after 1 week and 45 sites exhibited primary healing after

2 weeks. Four sites after 1 week and 14 sites after 2 weeks showed secondary healing (EHI = 4). None of the defects demonstrated EHI = 5.

**Table 1.** Baseline clinical features for the study group

Variables	Sites (n = 59)
Tooth type (n)	
molars	34
premolars	14
upper incisors, canines	11
Tooth position (n)	
maxillary teeth	18
mandibular teeth	41
Clinical measurements	
FMPI (%)	9.30 (7.31–11.30) ±6.87
BoP (%)	13.17 (11.45–14.90) ±5.94
PPD [mm]	7.31 (6.98–7.63) ±1.24
CAL [mm]	8.46 (8.07–8.85) ±1.50
GR [mm]	1.27 (1.03–1.52) ±0.94
Radiographic measurements	
DD [mm]	5.08 (4.68–5.49) ±1.56
ACP [mm]	3.99 (3.55–4.42) ±1.67
RVG angle [°]	27.96 (25.62–30.31) ±8.99
Sites-specific characteristics	
interdental contact point (present/absent)	50/9
interdental space width [mm]	2.66 (2.47–2.86) ±0.75
WKT [mm]	2.78 (2.55–3.01) ±0.89
phenotype (thin/thick)	13/46
Technical aspects	
vertical incision (yes/no)	23/36
papilla preparation	
MPPT (n)	24
SPPF (n)	35
Intrabony defect characteristics	
depth [mm]	4.92 (4.40–5.43) ±1.77
width [mm]	3.01 (2.68–3.34) ±1.13
Defect configuration (n)	
1-wall	12
2-wall	19
3-wall	28
Healing after 1 week	
primary/secondary (n)	55/4
EHI	
1 (n)	22
2 (n)	17
3 (n)	16
4 (n)	4
5 (n)	0
Healing after 2 weeks	
primary/secondary (n)	45/14
EHI	
1 (n)	43
2 (n)	2
3 (n)	0
4 (n)	14
5 (n)	0

The means with 95% CI (in brackets) and ±SD of probing values and radiographic measurements of the defects before surgery.

FMPI – full-mouth plaque index; BoP – bleeding on probing index; PPD – probing pocket depth; CAL – clinical attachment level; GR – gingival recession; DD – radiographic defect depth; ACP – alveolar crest position; RVG angle – radiographic defect angle; WKT – width of keratinized tissue; MPPT – modified papilla preservation technique; SPPF – simplified papilla preservation flap; EHI – Early Wound-Healing Index; n – number of defects; SD – standard deviation; CI – confidence interval.

Correlations between patient-, site- and technique-related factors and postoperative healing depending on papilla preservation technique (SPPF/MPPT/both) are summarized in Tables 2–4, which present correlation coefficients. No associations between age, gender, BoP, PPD, CAL, DD, ACP, defect depth, presence of vertical incision, interdental space width, and WKT were observed. Weak correlations ( $R < 0.40$ ) were found with tooth position, tooth type, FMPI, RVG angle, defect width, and phenotype. When analysis distinguished between SPPF sites and MPPT sites, weak correlations between postoperative healing and tooth position / GR at SPPF sites were detected, while moderate correlations ( $R = 0.40–0.70$ ) with tooth type / phenotype at SPPF sites, as well as moderate correlations with FMPI / presence of interdental space at MPPT sites were noted.

When site-related factors were put into a multiple regression analysis, the model was statistically significant ( $p < 0.05$ ) for tooth type and phenotype for all sites; tooth type, phenotype and gingival recessions in cases of SPPF sites; and presence of interdental contact point in cases of MPPT sites (Tables 5,6). Tooth type and GR were significantly correlated ( $p = 0.029$  and  $p = 0.032$ , respectively) with EHI after 1 week only in SPPF sites, whereas tooth type and phenotype determined healing 2 weeks postoperatively in all sites ( $p = 0.033$  and  $p = 0.004$ , respectively). At MPPT sites, the presence of the interdental contact point affected the healing after 2 weeks ( $p = 0.053$ ). Generally speaking, the likelihood of better healing was higher for molars than 1-rooted teeth (incisors / canines / premolars) ( $OR = 0.24$ ) and sites with a thick phenotype ( $OR = 0.13$ ). On the other hand, the presence of gingival recession or interdental contact points increased the probability of impaired healing (higher grades of the EHI;  $OR = 32.78$  and  $OR = 0.08$ , respectively).

## Discussion

In the present analysis, we evaluated the early healing phase after GTR treatment of intrabony defects in patients with AgP. To achieve this goal, the EHI was used. To the best of the authors' knowledge, the importance of the EHI has never been investigated in any study to express healing phase of periodontal wounds in patients with AgP. In all cases, 1 type of resorbable collagen membrane was used, whereas intraosseous defects were filled using various biomaterials. The use of barrier membranes was associated with the preparation of more extensive flaps and with periosteal incisions to obtain coronal flap mobilization without tension. In many cases, vertical cuts were also made. Recent research on blood clot formation during early wound healing revealed that even minimal tensile forces on the blood clot affect its morphology and nature.<sup>17</sup> Albeit primary tension-free flap closure was obtained at suturing in all treated defects, some sites presented

**Table 2.** Correlations between patient-, site- and technique-related parameters and healing p-values in brackets

Variables	1 week		2 weeks	
	EHI ≤ 2 or EHI ≥ 3	EHI ≤ 3 or EHI = 4	EHI ≤ 2 or EHI ≥ 3	EHI ≤ 3 or EHI = 4
Age [years]	0.20 (0.183)	0.05 (0.754)	-0.07 (0.636)	-0.11 (0.450)
Gender (females/males)	-0.12 (0.372)	-0.01 (0.952)	0.00 (0.993)	0.05 (0.700)
Tooth position (maxillary teeth / mandibular teeth)	-0.07 (0.614)	-0.26* (0.046)	-0.04 (0.790)	-0.12 (0.364)
Tooth type (incisor/canines/premolars/molars)	-0.29* (0.026)	-0.13 (0.310)	-0.29* (0.027)	-0.24 (0.065)
FMPI [%]	0.32* (0.028)	-0.13 (0.383)	0.14 (0.338)	0.12 (0.405)
BoP [%]	0.26 (0.076)	0.19 (0.187)	0.16 (0.270)	0.17 (0.243)
PPD [mm]	0.04 (0.763)	0.10 (0.460)	0.08 (0.545)	0.17 (0.192)
CAL [mm]	0.03 (0.815)	0.23 (0.074)	0.09 (0.497)	0.11 (0.415)
GR [mm]	-0.06 (0.632)	0.21 (0.110)	-0.04 (0.792)	-0.09 (0.517)
DD [mm]	-0.03 (0.806)	0.09 (0.499)	-0.14 (0.286)	-0.09 (0.479)
RVG angle [°]	-0.01 (0.921)	0.05 (0.724)	0.26* (0.046)	0.23 (0.082)
ACP [mm]	0.02 (0.855)	-0.06 (0.659)	0.00 (0.994)	-0.04 (0.751)
Vertical incision (present/absent)	0.16 (0.214)	0.22 (0.101)	-0.07 (0.578)	-0.01 (0.927)
Defect morphology (1-/2-/3-wall)	-0.08 (0.564)	0.08 (0.550)	0.08 (0.540)	0.15 (0.267)
Defect depth [mm]	0.07 (0.632)	0.06 (0.679)	-0.16 (0.264)	-0.13 (0.373)
Defect width [mm]	-0.32* (0.027)	-0.16 (0.290)	-0.03 (0.856)	-0.03 (0.858)
Papilla preservation technique (SPPF/MPPT)	0.16 (0.216)	-0.05 (0.700)	0.14 (0.283)	0.17 (0.207)
Interdental contact point (present/absent)	0.01 (0.954)	-0.07 (0.582)	-0.10 (0.456)	-0.08 (0.562)
Interdental space width [mm]	-0.16 (0.217)	-0.01 (0.922)	-0.17 (0.196)	-0.18 (0.176)
WKT [mm]	0.03 (0.850)	-0.09 (0.521)	-0.06 (0.662)	-0.03 (0.818)
Phenotype (thin/thick)	-0.17 (0.208)	-0.02 (0.885)	-0.39* (0.002)	-0.35* (0.007)

FMPI – full-mouth plaque index; BoP – bleeding on probing index; PPD – probing pocket depth; CAL – clinical attachment level; GR – gingival recession; DD – radiographic defect depth; ACP – alveolar crest position; RVG angle – radiographic defect angle; WKT – width of keratinized tissue; MPPT – modified papilla preservation technique; SPPF – simplified papilla preservation flap; EHI – Early Wound-Healing Index; \* statistically significant ( $p < 0.05$ ).

with secondary healing. The values of the EHI ranged from 1 to 4. After 7 days from the procedure, secondary healing was related to <7% of the examined sites, but after 2 weeks, this percentage increased to 23.73%. Most frequently, there was a loss of primary closure in places where the EHI values = 3. No correlations between the EHI and any patient-related factors were found. However, a multivariate analysis revealed that 1-rooted teeth (incisors, canines and premolars), as well as sites with thin phenotype and with the presence of gingival recessions were associated with impaired healing (higher EHI recordings and secondary healing).

Over the next 2–4 weeks, a complete epithelialization of exposed barrier membranes occurred in patients who were subject to secondary healing (data not shown). All patients were subject to a rigorous post-treatment protocol and used a mouth-rinsing solution containing 0.2% chlorhexidine. Due to the lack of mechanical plaque control in the treatment area, this seems to be a “golden standard”. However, Laugisch et al.<sup>13</sup> found that a postoperative protocol including 0.05% chlorhexidine herbal extract might have the potential to improve patient compliance during postoperative period, in comparison with 0.1% chlorhexidine solution, as tooth staining and discomfort associated with irritation or taste were more frequent in the former.

The present findings might be associated with the relatively small dimensions of 1-rooted teeth and the small distances between them when compared to molars, which might be further complicated by dental malposition and crowding. The gingival vessels on the buccal side run in the apical-coronal direction; therefore, incisions in the papilla may lead to disturbances of blood flow within the interdental papilla.<sup>18</sup> Vascularization of these gingival areas is mainly a network of vascular anastomoses and loops, so both the number of soft tissues in the interproximal spaces, and their structure may affect the regulation of blood flow after surgery.<sup>19</sup> Furthermore, animal studies proved that the mandibular vasculature was characterized by arterial vessels transversing somewhat obliquely in a general posterior to anterior direction.<sup>20</sup> In addition, the collateral vessels from the periodontal ligament contribute to the marginal blood supply. The morphology of gingiva remains in close relation to the process of eruption, as well as to shape and position of the teeth, and to the shape of the alveolar ridge. The characteristics of gingival morphology, bone and teeth are referred to as gingival phenotype. Thin and thick phenotypes are most often distinguished. In the case of the thin phenotype, wherein the gum is thin and delicate, the course of the gingival margin is strongly arched and there are often gingival recessions

**Table 3.** Correlations between patient-, site- and technique-related parameters and healing at SPPF sites (p-values in brackets)

Variables	1 week		2 weeks	
	EHI ≤ 2 or EHI ≥ 3	EHI ≤ 3 or EHI = 4	EHI ≤ 2 or EHI ≥ 3	EHI ≤ 3 or EHI = 4
Age [years]	0.04 (0.862)	0.04 (0.857)	-0.17 (0.393)	-0.26 (0.189)
Gender (females/males)	-0.05 (0.775)	0.14 (0.406)	0.19 (0.279)	0.26 (0.135)
Tooth position (maxillary teeth / mandibular teeth)	-0.29 (0.088)	-0.36* (0.032)	-0.07 (0.669)	-0.20 (0.239)
Tooth type (incisors/canines/premolars/molars)	-0.46* (0.006)	-0.19 (0.266)	-0.43* (0.010)	-0.36* (0.033)
FMPI [%]	0.17 (0.393)	-0.17 (0.409)	0.13 (0.517)	0.10 (0.618)
BoP [%]	0.32 (0.099)	0.13 (0.532)	-0.01 (0.957)	0.00 (0.989)
PPD [mm]	-0.06 (0.716)	0.03 (0.866)	0.06 (0.720)	0.20 (0.252)
CAL [mm]	0.00 (0.986)	0.23 (0.178)	0.14 (0.423)	0.18 (0.300)
GR [mm]	-0.07 (0.674)	0.36* (0.032)	-0.04 (0.820)	-0.12 (0.499)
DD [mm]	0.11 (0.522)	0.12 (0.499)	-0.14 (0.421)	-0.04 (0.803)
RVG angle [°]	0.07 (0.675)	-0.09 (0.615)	0.32 (0.060)	0.27 (0.116)
ACP [mm]	0.04 (0.812)	-0.13 (0.459)	0.15 (0.387)	0.09 (0.625)
Vertical incision (present/absent)	0.11 (0.526)	0.18 (0.307)	-0.27 (0.122)	-0.16 (0.361)
Defect morphology (1-/2-/3-wall)	-0.06 (0.747)	0.23 (0.191)	0.13 (0.470)	0.23 (0.191)
Defect depth [mm]	-0.10 (0.602)	0.10 (0.626)	-0.21 (0.303)	-0.15 (0.452)
Defect width [mm]	-0.05 (0.801)	-0.28 (0.151)	-0.08 (0.704)	-0.04 (0.845)
Interdental contact point (present/absent)	0.30 (0.077)	0.06 (0.729)	0.16 (0.348)	0.17 (0.339)
Interdental space width [mm]	-0.28 (0.097)	-0.13 (0.447)	-0.29 (0.096)	-0.26 (0.125)
WKT [mm]	-0.06 (0.745)	-0.24 (0.166)	-0.20 (0.243)	-0.17 (0.342)
Phenotype (thin/thick)	-0.23 (0.175)	0.09 (0.613)	-0.60* (<0.001)	-0.53* (0.001)

All the explanations as in Table 2.

**Table 4.** Correlations between patient-, site- and technique-related parameters and healing at MMPT sites (p-values in brackets)

Variables	1 week		2 weeks	
	EHI ≤ 2 or EHI ≥ 3	EHI ≤ 3 or EHI = 4	EHI ≤ 2 or EHI ≥ 3	EHI ≤ 3 or EHI = 4
Age [years]	0.38 (0.090)	0.07 (0.762)	0.04 (0.854)	0.04 (0.854)
Gender (females/males)	-0.21 (0.326)	-0.22 (0.309)	-0.32 (0.126)	-0.32 (0.126)
Tooth position (maxillary teeth / mandibular teeth)	0.29 (0.170)	-0.14 (0.520)	0.04 (0.849)	0.04 (0.849)
Tooth type (incisors/canines/premolars/molars)	-0.21 (0.329)	-0.05 (0.823)	-0.21 (0.313)	-0.21 (0.313)
FMPI [%]	0.52* (0.016)	-0.08 (0.740)	0.15 (0.508)	0.15 (0.508)
BoP [%]	0.36 (0.122)	0.00 (0.985)	0.01 (0.972)	0.01 (0.972)
PPD [mm]	0.21 (0.318)	0.21 (0.331)	0.10 (0.633)	0.10 (0.633)
CAL [mm]	0.17 (0.429)	0.22 (0.291)	0.11 (0.605)	0.11 (0.605)
GR [mm]	0.09 (0.669)	0.07 (0.729)	0.11 (0.607)	0.11 (0.607)
DD [mm]	-0.11 (0.596)	0.04 (0.853)	-0.07 (0.751)	-0.07 (0.751)
RVG angle [°]	-0.11 (0.605)	0.19 (0.368)	0.20 (0.344)	0.20 (0.344)
ACP [mm]	0.15 (0.491)	-0.03 (0.881)	-0.09 (0.685)	-0.09 (0.685)
Vertical incision (present/absent)	0.20 (0.344)	0.28 (0.189)	0.19 (0.382)	0.19 (0.382)
Defect morphology (1-/2-/3-wall)	-0.12 (0.578)	-0.10 (0.652)	0.00 (1.000)	0.00 (1.000)
Defect depth [mm]	0.28 (0.223)	0.01 (0.961)	-0.12 (0.591)	-0.12 (0.591)
Defect width [mm]	-0.41 (0.065)	-0.07 (0.768)	0.17 (0.470)	0.17 (0.470)
Interdental contact point (present/absent)	-0.32 (0.123)	-0.14 (0.520)	-0.45* (0.027)	-0.45* (0.027)
Interdental space width [mm]	0.18 (0.390)	0.05 (0.823)	0.16 (0.464)	0.16 (0.464)
WKT [mm]	0.08 (0.709)	0.26 (0.218)	0.19 (0.365)	0.19 (0.365)
Phenotype (thin/thick)	-0.24 (0.259)	-0.08 (0.718)	-0.35 (0.097)	-0.35 (0.097)

All the explanations as in Table 2.

**Table 5.** Odds ratios (ORs) calculated for site-specific factors associated with wound healing at 1 week

Factor	OR	95% CI	p
EHI ≤ 2 or EHI ≥ 3			
Tooth type (SPPF sites)	0.17	0.03–0.83	0.029
EHI ≤ 3 or EHI = 4			
GR (SPPF sites)	32.78	1.34–799.6	0.032

SPPF – simplified papilla preservation flap; GR – gingival recession.

**Table 6.** Odds ratios (ORs) calculated for site-specific factors associated with wound healing at 2 weeks

Factor	OR	95% CI	p
EHI ≤ 2 or EHI ≥ 3			
Tooth type (all sites)	0.24	0.06–0.089	0.033
Phenotype (all sites)	0.13	0.03–0.52	0.004
Tooth type (SPPF sites)	0.09	0.02–0.52	0.007
Phenotype (SPPF sites)	0.02	0.00–0.49	0.016
Presence of interdental contact point (MPPT)	0.08	0.01–1.03	0.053 <sup>†</sup>
EHI ≤ 3 or EHI = 4			
Phenotype (all sites)	0.13	0.03–0.52	0.004
Tooth type (SPPF sites)	0.17	0.03–0.83	0.028
Phenotype (SPPF sites)	0.03	0.00–0.71	0.029
Presence of interdental contact point (MPPT)	0.08	0.01–1.03	0.053 <sup>†</sup>

SPPF – simplified papilla preservation flap; MPPT – modified papilla preservation technique; EHI – Early Wound-Healing Index; <sup>†</sup> borderline statistical significance.

and a narrow band of keratinized tissue. The shape of the teeth is close to the triangle, and the contact points are close to the incisal edges. Characteristic features of the thin phenotype are instability of tissues and their high sensitivity to all kinds of injuries, including those related to surgical treatment. Tissue phenotype might be a significant factor influencing surgical treatment outcomes, as a flap thickness ranging from 0.8 to 1.2 mm was associated with a more predictable prognosis.<sup>21</sup> Consequently, flap thickness might be assumed to affect the vascularity of the pedicle.

When comparing the present results with those from other studies, it has to be underlined that different biomaterials and miscellaneous regenerative strategies were implemented. For instance, Wachtel et al.<sup>14</sup> described a high ratio (89–96%) of sites showing EHI ≤ 2 in MPPT sites 2 weeks postoperatively. It has to be kept in mind that in the abovementioned study the authors used the microsurgical access flap and enamel matrix derivatives (Emdogain®; Straumann, Basel, Switzerland) alone. Similarly, in the study by Farina et al.<sup>12</sup> following the buccal single flap approach (SFA), highly predictable (>80%) complete flap closure and optimal healing of about 50% of sites at 2 weeks were observed. Some site-specific characteristics, such as the narrow base of the interdental papilla, the presence of an interdental contact point

and interdental soft tissue crater were noted in the group with either EHI > 1 or EHI > 3 compared to the group with EHI = 1. However, 2-week soft tissue healing was not associated with 6-month clinical results. Moreover, sites treated with reconstructive devices (graft, graft + Emdogain, graft + membrane) exhibited suboptimal healing (EHI > 1). On the other hand, Rakmanee et al.<sup>22</sup> compared clinical outcomes between GTR and access flap (AF) in which SPPF were used in patients with AgP. While healing at the control sites seemed to be uneventful, in 13 out of 18 GTR-treated sites, the authors noted membrane exposure and secondary healing during the early postoperative phase. Moreover, CAL gain was found to be diminished at the sites with membrane exposure, compared to those with the non-exposed membrane. A meta-analysis that evaluated the effect of membrane exposure on the obtained clinical treatment results showed that the sites with an exposed membrane had a significantly reduced CAL gain (4.22 (0.15) mm) than the sites without membrane exposure (4.69 (0.13) mm) ( $p < 0.05$ ).<sup>23</sup> Aside from this, exposing the barrier membrane increases the probability of bacterial colonization, and exposure to the oral environment can accelerate resorption of absorbable membranes.<sup>24,25</sup>

All things considered, it may be speculated that the ancillary use of biomaterials may hinder obtaining favorable early healing of soft tissues. The use of a barrier membrane may be the reason for the temporary hindrance of mucoperiosteal flaps' revascularization.<sup>26</sup> Zanetta-Barbosa et al.<sup>27</sup> demonstrated the existence of a relationship between impaired blood flow in the flaps associated with the use of the barrier membrane and the incidence of wound dehiscences. Consequently, membranes might severely impinge on the microcirculation of flaps and jeopardize optimal physiological wound healing. Therefore, the selection of a regeneration strategy should be given careful consideration, especially in the case of extensive and non-supporting intrabony defects. In such cases, 2 options should be considered: GTR + biomaterial (this strategy was evaluated in our study) or Emdogain + biomaterial. The choice of technique depends on a detailed analysis of individual conditions and an assessment of likely outcomes of treatment after the application of a given technique in a specific clinical case. It should be emphasized that membrane-based surgical procedures are more demanding; therefore, technical errors can significantly worsen the effects of treatment. Thus, in a situation where the abovementioned techniques have the same indications to be performed, the choice of Emdogain + biomaterial seems to be a safer method.<sup>28</sup>

When interpreting the findings of this study, it is important to understand that only early healing within 2 weeks of GTR was assessed. Various biomaterials were used in the treatment of intraosseous defects, but only 1 type of resorbable collagen membrane was used. Therefore, the impact of the type of material used for



defect filling on soft tissue healing cannot be ruled out, but it seems unlikely. On the other hand, due to the time of observation, it is not known whether early healing would affect the clinical outcome of the treatment after 6 and 12 months, and in a longer perspective. Moreover, some limitations of a secondary analysis, such as higher risk of bias, must be emphasized. However, all data of interest was collected from all patients, so it was available for the analysis. The researchers who were analyzing the data were involved in the data collection process. Consequently, they were aware of study-specific nuances that might have been important for understanding of variables in the dataset. It would definitely be advisable to perform a similar analysis based on a larger group of patients and treatment sites, because the limited number of points in the study could be too small for a statistical analysis to show a significant impact of other factors, related not only to the treatment site but also to the patient, on early healing of soft tissues.

## Conclusions

Within the limitations of this secondary analysis, it can be said that GTR of intrabony defects in patients with AgP resulted in a complete wound closure in a great majority of sites, especially after 7 days. However, site-related factors may impinge on early postoperative healing, which should be taken into account when choosing a regenerative strategy. Thick gingival phenotype might be a prerequisite for optimal wound healing.

## References

- Lang NP, Bartold PM, Cullinan M, et al. Consensus report: Aggressive periodontitis. *Ann Periodontol*. 1999;4(1):53.
- Agari R, Yari K, Mansouri K, Bakhtiari M. Association analysis of FAS-670A/G and FASL-844C/T polymorphisms with risk of generalized aggressive periodontitis disease. *Biomed Rep*. 2018;8(4):391–395.
- Susin C, Haas AN, Albandar JM. Epidemiology and demographics of aggressive periodontitis. *Periodontol 2000*. 2014;65(1):27–45.
- Susin C, Wikesjö UM. Regenerative periodontal therapy: 30 years of lessons learned and unlearned. *Periodontol 2000*. 2013;62(1):232–242.
- Burkhardt R, Lang NP. Fundamental principles in periodontal plastic surgery and mucosal augmentation: A narrative review. *J Clin Periodontol*. 2014;41(Suppl 15):S98–S107.
- Polimeni G, Xiropaidis AV, Wikesjö UM. Biology and principles of periodontal wound healing/regeneration. *Periodontol 2000*. 2006;41:30–47.
- Cortellini P, Tonetti MS. Clinical concepts for regenerative therapy in intrabony defects. *Periodontol 2000*. 2015;68(1):282–307.
- Bosshardt DD, Sculean A. Does periodontal tissue regeneration really work? *Periodontol 2000*. 2009;51:208–219.
- Kleinhein J, Büchter A, Kruse-Lösler B, Weingart D, Joos U. Incision design in implant dentistry based on vascularization of the mucosa. *Clin Oral Implants Res*. 2005;16(5):518–523.
- Cortellini P, Prato GP, Tonetti MS. The modified papilla preservation technique: A new surgical approach for interproximal regenerative procedures. *J Periodontol*. 1995;66(4):261–266.
- Cortellini P, Prato GP, Tonetti MS. The simplified papilla preservation flap: A novel surgical approach for the management of soft tissues in regenerative procedures. *Int J Periodontics Rest Dent*. 1999;19(6):589–599.
- Farina R, Simonelli A, Rizzi A, Pramstraller M, Cucchi A, Trombelli L. Early postoperative healing following buccal single flap approach to access intraosseous periodontal defects. *Clin Oral Invest*. 2013;17(6):1573–1583.
- Laugisch O, Ramseier CA, Salvi GE, et al. Effects of two different post-surgical protocols including either 0.05% chlorhexidine herbal extract or 0.1% chlorhexidine on post-surgical plaque control, early wound healing and patient acceptance following standard periodontal surgery and implant placement. *Clin Oral Invest*. 2016;20(8):2175–2183.
- Wachtel H, Schenk G, Böhm S, Weng D, Zuhr O, Hürzeler MB. Microsurgical access flap and enamel matrix derivative for the treatment of periodontal intrabony defects: A controlled clinical study. *J Clin Periodontol*. 2003;30(6):496–504.
- O'Leary TJ, Drake RB, Naylor JE. The plaque control record. *J Periodontol*. 1972;43(1):38–46.
- Ainamo J, Bay I. Problems and proposal for recording gingivitis and plaque. *Int Dent J*. 1975;25(4):229–235.
- Baker DL, Stanley Pavlow SA, Wikesjö UM. Fibrin clot adhesion to dentin conditioned with protein constructs: An in vitro proof-of-principle study. *J Clin Periodontol*. 2005;32(6):561–566.
- Mörmann W, Meier C, Firestone A. Gingival blood circulation after experimental wounds in man. *J Clin Periodontol*. 1979;6(6):417–424.
- Kohl JT, Zander HA. Morphology of interdental gingival tissues. *Oral Surg Oral Med Oral Pathol*. 1961;14:287–295.
- Jeffcoat MK, Kaplan ML, Rumbaugh CL, Goldhaber P. Magnification angiography in beagles with periodontal disease. *J Periodontol Res*. 1982;17(3):294–299.
- Hwang D, Wang HL. Flap thickness as a predictor of root coverage: A systematic review. *J Periodontol*. 2006;77(10):1625–1634.
- Rakmanee T, Griffiths GS, Auplish G, et al. Treatment of intrabony defects with guided tissue regeneration in aggressive periodontitis: Clinical outcomes at 6 and 12 months. *Clin Oral Invest*. 2016;20(6):1217–1225.
- Machtei EE. The effect of membrane exposure on the outcome of regenerative procedures in humans: A meta-analysis. *J Periodontol*. 2001;72(4):512–516.
- Ling LJ, Hung SL, Lee CF, Chen YT, Wu KM. The influence of membrane exposure on the outcomes of guided tissue regeneration: Clinical and microbiological aspects. *J Periodontol Res*. 2003;38(1):57–63.
- Mengel R, Soffner M, Flores-de-Jacoby L. Bioabsorbable membrane and bioactive glass in the treatment of intrabony defects in patients with generalized aggressive periodontitis: Results of a 12-month clinical and radiological study. *J Periodontol*. 2013;74(6):899–908.
- Vergara JA, Quiñones CR, Nasjleti CE, Caffesse RG. Vascular response to guided tissue regeneration procedures using non-resorbable and bioresorbable membranes in dogs. *J Periodontol*. 1997;68(3):217–224.
- Zanetta-Barbosa D, Klinge B, Svennson H. Laser Doppler flowmetry of blood perfusion in mucoperiosteal flaps covering membrane sin bone augmentation and implant procedures: A pilot study in dogs. *Clin Oral Implants Res*. 1993;4:35–38.
- Esposito M, Grusovin MG, Papanikolaou N, Coulthard P, Worthington HV. Enamel matrix derivative (Emdogain) for periodontal tissue regeneration in intrabony defects: A Cochrane systematic review. *Eur J Oral Implantol*. 2009;2(4):247–266.



# Association between the morphology and thickness of bony components of the temporomandibular joint and gender, age and remaining teeth on cone-beam CT images

## Związek pomiędzy morfologią i grubością części kostnych stawu skroniowo-żuchwowego a płcią, wiekiem oraz liczbą zachowanych zębów na podstawie przekrojów tomografii stożkowej

Tahmineh Razi<sup>A,D-F</sup>, Sedigheh Razi<sup>A-D</sup>

Department of Oral and Maxillofacial Radiology, Faculty of Dentistry, Tabriz University of Medical Sciences, Iran

A – research concept and design; B – collection and/or assembly of data; C – data analysis and interpretation; D – writing the article; E – critical revision of the article; F – final approval of the article

Dental and Medical Problems, ISSN 1644-387X (print), ISSN 2300-9020 (online)

*Dent Med Probl.* 2018;55(3):299–304

### Address for correspondence

Sedigheh Razi  
E-mail: sed\_razi@yahoo.com

### Funding sources

None declared

### Conflict of interest

None declared

Received on April 28, 2018  
Reviewed on May 28, 2018  
Accepted on July 24, 2018

DOI  
10.17219/dmp/92317

### Copyright

© 2018 by Wrocław Medical University  
and Polish Dental Society  
This is an article distributed under the terms of the  
Creative Commons Attribution Non-Commercial License  
(<http://creativecommons.org/licenses/by-nc-nd/4.0/>)

### Abstract

**Background.** Various factors such as aging, sex hormones and the distribution pattern of occlusal forces affect the morphology and osseous components of the temporomandibular joint (TMJ). Recognition of the effects of these factors on the anatomy of the area results in the differentiation of normal variations from abnormal cases.

**Objectives.** The aim of the present study was to evaluate the relationship between the condyle and other hard components of TMJ, and age, gender and the number of remaining teeth.

**Material and methods.** In the present descriptive-analytical study, a total of 145 cone-beam computed tomography (CBCT) images were evaluated. The condyle morphology, the thickness of the glenoid fossa roof, and the height and slope of the eminence were evaluated.

**Results.** There were significant differences between the right and left sides only in terms of the height of the articular eminence ( $p = 0.008$  and  $p \leq 0.001$  on the right and left side, respectively). There were significant differences between both sides in the slope of articular eminence depending on the number of teeth ( $p = 0.01$  and  $p = 0.008$  on the right and left side, respectively). The height of the articular eminence on the left side differed significantly depending on age ( $p = 0.005$ ) and the number of remaining teeth ( $p = 0.02$ ). There were no significant differences in any other cases.

**Conclusions.** No significant relationship was found between the thickness of the glenoid fossa roof and the articular eminence, and the condyle morphology in all 3 cross-sections regarding gender, age and the number of remaining teeth.

**Key words:** cone-beam computed tomography, thickness of glenoid fossa, height of articular eminence, slope of articular eminence, condyle morphology

**Słowa kluczowe:** stożkowa tomografia komputerowa, grubość dołka stawowego, wysokość guzka stawowego, stok guzka stawowego, morfologia kłykcia

## Introduction

The temporomandibular joint (TMJ) is a center of growth and it is important for chewing since it bears the loads during mastication.<sup>1,2</sup> It is a bilateral joint and has a unique function and morphology.<sup>3</sup> The forces exerted on TMJ affect the osseous components of the joint, resulting in changes in the thickness and form of these components. These changes are considered beyond the scope of normal variations if excessive loads are exerted on the joint, necessitating the elimination of the etiologic agents.<sup>4-6</sup>

Cone-beam computed tomography (CBCT) provides the necessary information for the diagnosis of TMJ problems<sup>7,8</sup>; however, it is less reliable in relation to the soft tissue contrast and the calcification of soft tissues.<sup>9</sup> In one of the studies, 1/4 (25%) of initial diagnoses regarding temporomandibular disorders (TMD) made by oral and maxillofacial surgeons after examination and evaluation of panoramic radiographs were corrected after CBCT examination and evaluation of CBCT images, resulting in a change in the treatment plan in 12% of cases.<sup>10</sup>

Morphologic changes due to the effects of sex hormones and metabolic activity during adulthood result in differences between males and females.<sup>11</sup> In a study by Hedge et al., the prevalence of the convex shape of the condyle was higher in women.<sup>12</sup> However, the results of the present study showed no differences between males and females in this respect. A study by Ejima et al. showed a lower frequency of the angular

shape in the coronal view.<sup>13</sup> A higher frequency of the flat shape was reported in women, with higher loads on the bones and joints being tolerated in men due to higher osseous density and thicker cortex.<sup>14</sup>

A large number of researchers believe that a higher slope of the articular eminence has an important role in disk displacement.<sup>15-19</sup> One of the etiologic factors for degenerative changes in the joint is the internal derangement of the disk, which is more common in women. It is expected that, due to high prevalence of arthritic disturbances, the slope of the articular eminence is higher in females compared to males. There is controversy over the relationship between the articular slope and gender, and discrepancies have been reported in this context. The discrepancies between the results of different studies on TMJ might be attributed to differences in subject selection criteria, sample sizes and ethnicity.

The aim of the present study was to evaluate the morphology of the condyle and the thickness of other osseous components of TMJ on CBCT images in terms of age, gender and the number of remaining teeth.

## Material and methods

A total of 145 patients referred to the Department of Oral and Maxillofacial Radiology, Faculty of Dentistry at Tabriz University of Medical Sciences (Iran) were included in this descriptive-analytical study in the years 2014–2015. The subjects, aged 20–80 years,

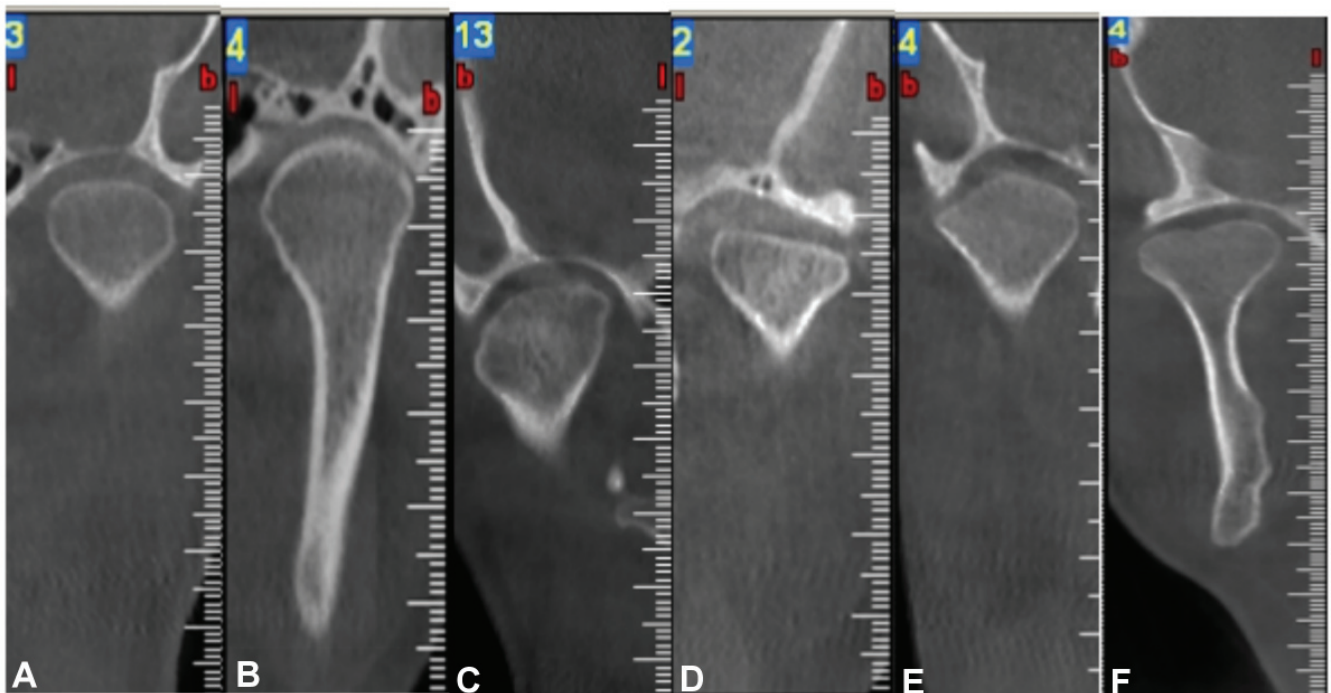


Fig. 1. Coronal morphology of the condyle (A – convex; B – round; C – flat without any effect on the glenoid fossa; D – flat with an effect on the glenoid fossa; E – angled; F – heart-shaped)

needed CBCT images for a variety of reasons. All radiographic examinations were carried out for other diagnostic purposes, such as implant placement. The inclusion criteria were as follows: no history of surgery, fracture or congenital defects of TMJ, no pathologic lesions in the jaws, and asymptomatic TMD. The exclusion criteria were as follows: faulty restorations with incorrect anatomical characteristics of occlusion, complete or partial prostheses, a history of systemic diseases, use of medications affecting the joints, a history of trauma, surgery or jaw lesions, or ill-fitting prostheses.

After obtaining informed consent, the age, gender and number of remaining teeth in the patients were recorded.

The CBCT images were taken with the use of a NewTom VGi® Cone-Beam CT unit (NewTom, Verona, Italy) in the Department of Oral and Maxillofacial Radiology. The CBCT unit used a conical X-ray beam, and was provided with a flat-panel detector, 1536 × 1920 pixels, 127 μm × 27 μm pixel size, 14-bit pixel depth, 360° rotation, 18-second scan time, and peak kilovoltage (kVp) = 110. The viewer software program v. 2.17 (NewTom) was used for initial and final reconstructions. The X-ray conditions of the CBCT unit were adjusted automatically. The CBCT images prepared using the axial cross-sections were 0.5 mm in thickness. The sagittal cross-sections were evaluated perpendicular to the long axis of the condyle at a thickness of 1 mm and

the coronal cross-sections were evaluated parallel to the long axis of the condyle at a thickness of 1 mm.

Articular eminence measurements were made in the cross-sections, using the points and lines described, and the height of the eminence was calculated by measuring the vertical distance between the uppermost and lowermost points of the articular eminence.<sup>20</sup>

The morphology of the condyle was classified into 6 categories in coronal views: convex, round, flat with an effect on the glenoid fossa, flat without any effect on the glenoid fossa, angular, and heart-shaped (Fig. 1). This view was prepared at the widest medio-lateral cross-section of the condyle on the axial cross-section.

The morphology of the condyle was classified into 4 categories in the sagittal dimension: round, intermediate (a form between round and flat), flat without any effect on the glenoid fossa, and flat with an effect on the glenoid fossa (Fig. 2).

The condyle morphology was classified into 3 categories in the axial dimension: oval, bean-shaped and conical (Fig. 3).

The thickness of the glenoid fossa roof was measured in the sagittal view at its thinnest site.

The data was analyzed with descriptive statistical techniques, in addition to the t-test,  $\chi^2$  test, correlation coefficient, univariate analysis of variance (ANOVA), and multivariate ANOVA, using SPSS v. 17 statistical software (IBM Corp., Armonk, USA). Statistical significance was set at  $p < 0.05$ .

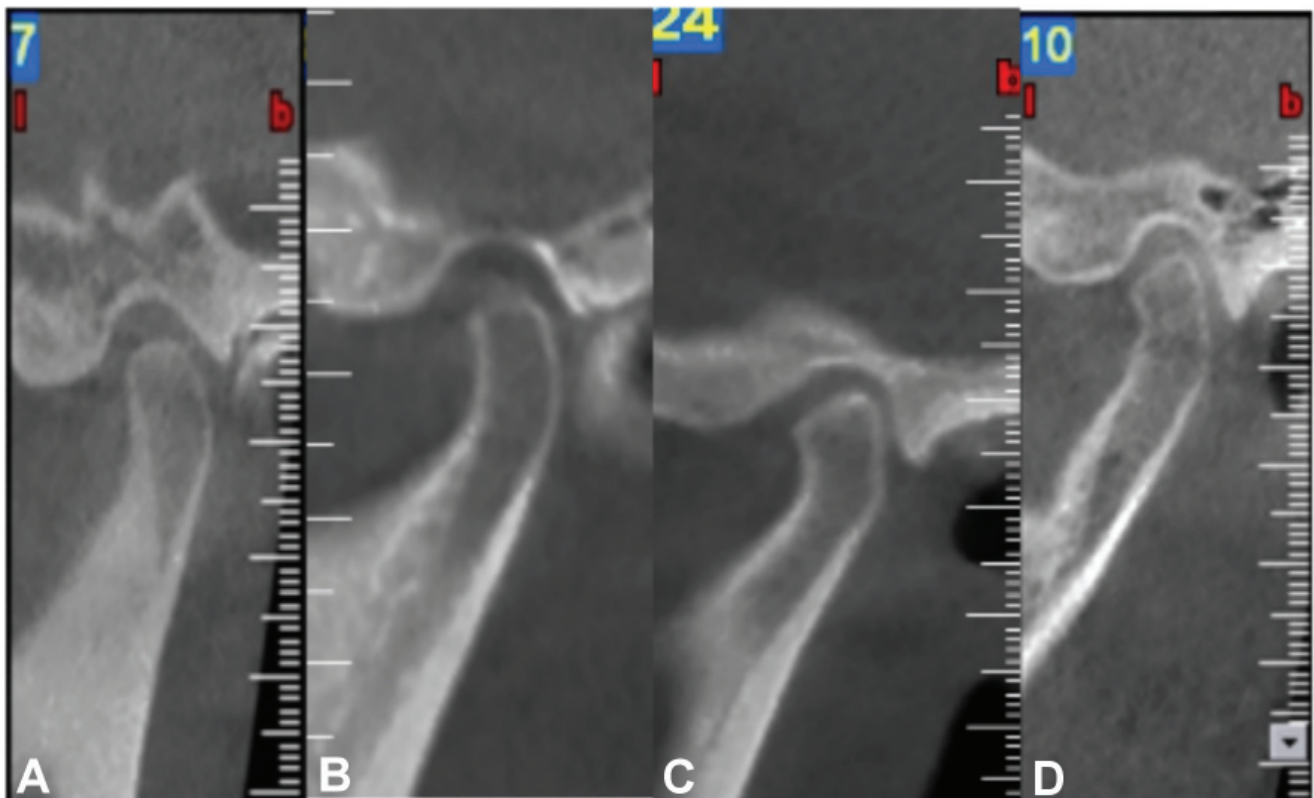


Fig. 2. Sagittal morphology of the condyle (A – round; B – intermediate; C – flat with an effect on the glenoid fossa; D – flat without any effect on the glenoid fossa)

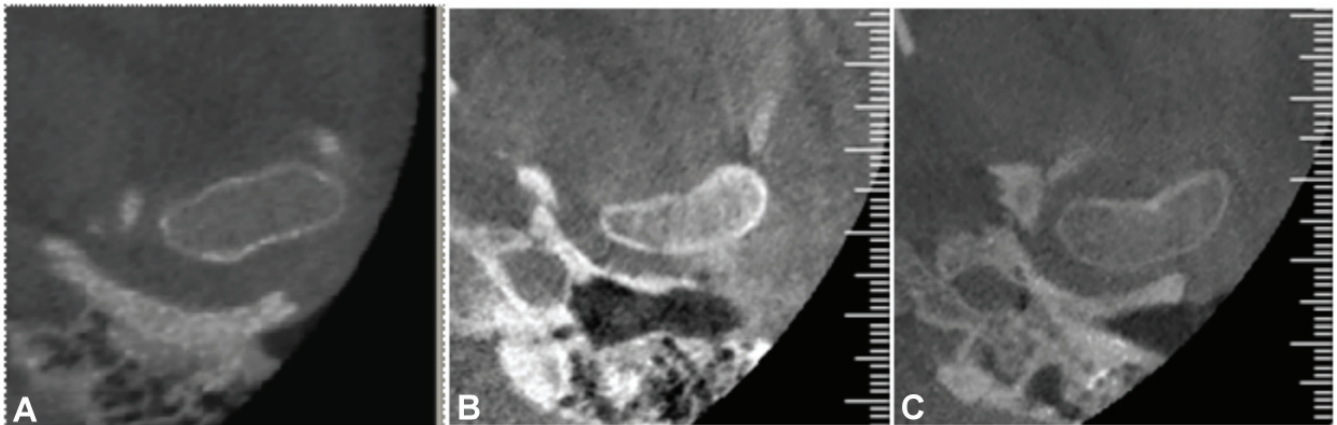


Fig. 3. Axial morphology of the condyle (A – oval; B – conical; C – bean-shaped)

## Results

In the present study, 145 subjects with a mean age of  $41.39 \pm 12.95$  years (age range: 20–80) were evaluated, with 73 males (50.30%) and 72 females (49.70%).

There was no significant relationship between the condyle morphology and gender in the sagittal view on the right ( $p = 0.61$ ) and left ( $p = 0.99$ ) sides, in the coronal view on the right ( $p = 0.84$ ) and left ( $p = 0.46$ ) sides, and in the axial view on the right ( $p = 0.27$ ) and left ( $p = 0.82$ ) sides. There was no significant relationship between the condyle morphology and age in the sagittal view on the right ( $p = 0.49$ ) side, in the coronal view on the right ( $p = 0.12$ ) and left ( $p = 0.32$ ) sides, and in the axial view on the right ( $p = 0.85$ ) and left ( $p = 0.40$ ) sides; however, there was a significant relationship between the condyle morphology and age in the sagittal view on the left side ( $p = 0.04$ ).

No significant relationships were shown between the condyle morphology and the number of remaining teeth in the sagittal view on the right ( $p = 0.17$ ) and left ( $p = 0.41$ ) sides, in the coronal view on the right ( $p = 0.47$ )

and left ( $p = 0.41$ ) sides, and in the axial view on the right side ( $p = 0.49$ ); however, such a relationship was significant in the axial view on the left side ( $p = 0.008$ ).

The differences in the height of the articular eminence in terms of gender were significant on the right ( $p = 0.008$ ) and left ( $p \leq 0.001$ ) sides. The difference in the slope of the articular eminence was significant on the right side ( $p = 0.01$ ), but it was not significant on the left side ( $p = 0.19$ ). The relationships between the slope and height of the articular eminence and age and the number of remaining teeth are detailed in Table 1.

There was no significant relationship between the thickness of the glenoid fossa roof and gender on the left and right sides ( $p = 0.12$ ). The relationship between the thickness of the glenoid fossa roof and age is detailed in Table 2. The relationship between the thickness of the glenoid fossa roof and the articular eminence on one hand and the condyle morphology on the other hand was not significant in terms of gender, age and the number of remaining teeth in any of the cross-sections evaluated in the present study.

Table 1. Correlation between the slope and height of the articular eminence and the thickness of the glenoid fossa roof on both sides, and age and the number of remaining teeth

Variable	Slope of the right articular eminence	Slope of the left articular eminence	Height of the right articular eminence	Height of the left articular eminence	Thickness of the right glenoid fossa	Thickness of the left glenoid fossa
Age	$p = 0.15$ $r = 0.11$ $n = 145$	$p = 0.13$ $r = 0.11$ $n = 145$	$p = 0.10$ $r = 0.13$ $n = 145$	$p = 0.005$ $r = 0.23$ $n = 145$	$p = 0.14$ $r = 0.12$ $n = 145$	$p = 0.01$ $r = 0.28$ $n = 145$
Number of remaining teeth	$p = 0.01$ $r = 0.20$ $n = 145$	$p = 0.008$ $r = 0.21$ $n = 145$	$p = 0.27$ $r = 0.09$ $n = 145$	$p = 0.02$ $r = 0.18$ $n = 145$	$p = 0.42$ $r = 0.06$ $n = 145$	$p = 0.07$ $r = 0.14$ $n = 145$

Table 2. Relationship between the thickness of the glenoid fossa roof and the articular eminence on one hand and condyle morphology on the other hand in terms of age

Variable	p-value (sagittal view)	p-value (coronal view)	p-value (axial view)
Thickness of the right glenoid fossa	0.37	0.78	0.94
Thickness of the left glenoid fossa	0.52	0.51	0.35
Height of the right articular eminence	0.48	0.15	0.88
Height of the left articular eminence	0.10	0.89	0.84

## Discussion

The condyle and articular eminence morphology affect one another and are affected by other factors.<sup>21</sup> A study by Zain-Alabdeen and Alsadhan showed the adaptation of the condyle to changes in the articular disk and articular eminence.<sup>22</sup> However, another study reported absence of any effect of the condyle morphology and the number of remaining teeth on the thickness of the glenoid fossa in asymptomatic European patients.<sup>13</sup> A systematic review showed that functional forces exerted on TMJ were different in males and females, and caused morphologic changes in both genders. The shape of the condyle and the glenoid fossa affect one another.<sup>12</sup> Sümbüllü et al. observed that despite the greater height and slope of the articular eminence in males compared to females, no significant differences were found between the 2 groups.<sup>20</sup> However, this study proved a significant difference in terms of age in the control group.<sup>20</sup> A study by İlgüy et al. showed no relationship between the thickness of the glenoid fossa roof and gender.<sup>23</sup>

In the present study, no significant relationship was detected between gender and the joint shape in the axial view, with the oval shape being the most frequent on both sides in the axial view. Two cases of bilateral bifid joints were found.

One of the factors affecting changes in the morphology of the condyle is age; such changes have been recorded in the elderly due to degenerative processes in the joint.<sup>12</sup> Morphologic evaluation of the condyle in terms of age in different cross-sections on both sides did not reveal any significant differences except for the left side in the sagittal cross-section. The significance of the results on the left side was attributed to the effect of higher prevalence of the intermediate shape at young ages on statistical analyses. In the present study, there was no relationship between the number of remaining teeth and the condyle morphology, which was consistent with the results of a study by Ejima et al.<sup>13</sup>

The height of the articular eminence was greater in males compared to females on both sides, in accordance with a large number of previous studies. Such greater height in men is rational given the higher bone mass and body height in men compared to women.

There are discrepancies in the results of studies regarding the relationship between age and the height of the articular eminence.<sup>20,23–26</sup> In the present study, a decrease was shown in the height of the articular eminence along with age on the left side and a direct relationship was found between the height of the articular eminence on the left and the number of remaining teeth, i.e., the height of the articular eminence decreased with aging and a decrease in the number of remaining teeth.

It is expected that, due to greater prevalence of degenerative joint disease (DJD) in females, the slope of the articular eminence must be higher in females,<sup>6</sup> but it is not

possible to confirm the hypothesis that a high slope of the articular eminence is a predisposing factor for irreversible disk displacement.<sup>26</sup> Some studies reported the opposite, as well as a higher slope in males. Such a discrepancy might be attributed to differences in the criteria used to select subjects.<sup>20,23</sup> In the present study, the slope of the articular eminence in males was generally greater than that in females and a significant difference was found on the right side. Another study did not show a difference in the slope of the articular eminence between asymptomatic subjects and those with TMJ disorders.<sup>27</sup>

In the present study, age had no effect on the slope of the articular eminence on both sides. Some other studies did not report any effect of age on the slope of the articular eminence.<sup>20,23,28</sup> In the present study, the slope of the articular eminence on both sides was under the influence of the remaining teeth, i.e., there was a direct relationship between them; the slope increased along with an increase in the number of remaining teeth.

In a study by Ejima et al., the thickness of the glenoid fossa roof was not influenced by age or the number of teeth lost.<sup>13</sup> It was reported that the shape of the condyle and the thickness of the glenoid fossa roof were not affected by malocclusion, even in individuals who had lost a large number of teeth. Kijima et al. evaluated the effect of age on the thickness of the glenoid fossa roof and reported similar results.<sup>29</sup> Despite a small sample size in those 2 studies, the results are consistent with those of the present study in respect to the relationship between age and the thickness of the glenoid fossa roof, except for the left side. The results of a study by İlgüy et al., similar to the present one, showed no relationship between the thickness of the glenoid fossa roof and gender.<sup>23</sup>

There is a significant relationship between the thickness of the glenoid fossa roof and the morphologic characteristics of the condyle in the sagittal view.<sup>13,30,31</sup> Honda et al. reported a relationship between the thickness of the glenoid fossa roof and the internal derangement of the joint and osteoarthritis.<sup>32</sup>

Similar to the present study, İlgüy et al. reported no relationship between the number of remaining teeth and the thickness of the glenoid fossa roof.<sup>23</sup>

Several studies evaluated the relationship between the thickness of the glenoid fossa and the morphology of the condyle. Kijima et al. and Ejima et al. did not find a significant relationship between the thickness of the glenoid fossa roof and the condyle morphology in the coronal cross-section in patients with TMJ disorders,<sup>13,29</sup> except that Ejima et al. evaluated asymptomatic subjects and pointed out that it was possible for joint disorder to have existed in their samples.<sup>13</sup> The same authors reported a significant relationship between the thickness of the glenoid fossa roof and the condyle morphology,<sup>13</sup> in accord with the results reported by Tsuruta et al.<sup>30</sup> The studies carried out in this subject did not evaluate the effects of age, gender and the remaining teeth.

## Conclusions

No significant relationship was found between the thickness of the glenoid fossa roof and the articular eminence on one hand and the condyle morphology on the other hand in all 3 cross-sections of the study in terms of age, gender and the number of remaining teeth.

## References

- Embree MC, Iwaoka GM, Kong D, et al. Soft tissue ossification and condylar cartilage degeneration following TMJ disc perforation in a rabbit pilot study. *Osteoarthritis Cartilage*. 2015;23(4):629–639.
- Cisewski SE, Zhang L, Kuo J, et al. The effects of oxygen level and glucose concentration on the metabolism of porcine TMJ disc cells. *Osteoarthritis Cartilage*. 2015;23(10):1790–1796.
- Shi C, Wright GJ, Ex-Lubeskie CL, Bradshaw AD, Yao H. Relationship between anisotropic diffusion properties and tissue morphology in porcine TMJ disc. *Osteoarthritis Cartilage*. 2013;21(4):625–633.
- Pandis N, Karpac J, Trevino R, Williams B. A radiographic study of condyle position at various depths of cut in dry skulls with axially corrected lateral tomograms. *Am J Orthod Dentofac Orthop*. 1991;100(2):116–122.
- Katsavrias EG. Changes in articular eminence inclination during the craniofacial growth period. *Angle Orthod*. 2002;72(3):258–264.
- White SC, Pharoah MJ. *Oral Radiology: Principles and Interpretation*. 7th ed. St Louis, MO: Mosby; 2014:501,509.
- Barghan S, Tetradis S, Mallya SM. Application of cone beam computed tomography for assessment of the temporomandibular joints. *Aust Dent Assoc*. 2012;57(Suppl 1):109–118.
- White SC, Pharoah MJ. *Oral Radiology: Principles and Interpretation*. 6th ed. St Louis, MO: Mosby; 2009:238.
- Al-Ekrish A. A retrospective study of the prevalence and reliability of the diagnosis of soft tissue calcification of the temporomandibular joint in cone beam computed tomography images. *King Saud Univ J Dent Sci*. 2013;4(2):81–85.
- de Boer EW, Dijkstra PU, Stegenga B, de Bont LG, Spijkervet FK. Value of cone-beam computed tomography in the process of diagnosis and management of disorders of the temporomandibular joint. *Br J Oral Maxillofac Surg*. 2014;52(3):241–246.
- Siriwat P, Jarabak J. Malocclusion and facial morphology: Is there a relationship? An epidemiologic study. *Angle Orthod*. 1985;55(2):127–138.
- Hegde S, Praveen BN, Ram Shetty S. Morphological and radiological variations of mandibular condyles in health and diseases: A systematic review. *Dentistry*. 2013;3(1):154.
- Ejima K, Schulze D, Stipping A, Mastsumoto K, Rottke D, Honda K. Relationship between the thickness of the roof of glenoid fossa, condyle morphology and remaining teeth in asymptomatic European patients based on cone beam CT data sets. *Dentomaxillofac Radiol*. 2013;42(3):90929410.
- Wood N, Goaz P. *Differential Diagnosis of Oral and Maxillofacial Lesions*. 5th ed. St. Louis, MO: Mosby; 1996:393–412.
- Atkinson WB, Bates RE. The effects of the angle of the articular eminence on anterior disk displacement. *J Prosthet Dent*. 1983;49(4):554–555.
- Panmekiate S, Petersson A, Akerman S. Angulation and prominence of the posterior slope of the eminence of the temporomandibular joint in relation to disc position. *Dentomaxillofac Radiol*. 1991;20(4):205–208.
- Isberg A, Westesson PL. Steepness of articular eminence and movement of the condyle and disk in asymptomatic temporomandibular joints. *Oral Surg Oral Med Oral Pathol Oral Radiol Endod*. 1998;86(2):152–157.
- Jasinevicius TR, Pyle MA, Nelson S, Lalumandier JA, Kohrs KJ, Sawyer DR. Relationship of degenerative changes of the temporomandibular joint (TMJ) with the angle of eminentia. *J Oral Rehabil*. 2006;33(9):638–645.
- Kerstens HC, Tuinzing DB, Golding RP, Van der Kwast WA. Inclination of the temporomandibular joint eminence and anterior disc displacement. *Int J Oral Maxillofac Surg*. 1989;18(4):228–232.
- Sümbüllü MA, Çağlayan F, Akgül HM, Yılmaz AB. Radiological examination of the articular eminence morphology using cone beam CT. *Dentomaxillofac Radiol*. 2012;41(3):234–240.
- Katsavrias HG. Morphology of the temporomandibular joint in subjects with class II division 2 malocclusions. *Am J Orthod Dentofac Orthop*. 2006;129(4):470–478.
- Zain-Alabdeen EH, Alsadhan RI. A comparative study of accuracy of detection of surface osseous changes in the temporomandibular joint using multidetector CT and cone beam CT. *Dentomaxillofac Radiol*. 2012;41(3):185–191.
- İlgüy D, İlgüy M, Fişekçioğlu E, Dölekoğlu S, Ersan N. Articular eminence inclination, height, and condyle morphology on cone beam computed tomography. *Sci World J*. 2014;2014: ID:761714.
- Sülün T, Cemgil T, Duc J-MP, Rammelsberg P, Jäger L, Gernet W. Morphology of the mandibular fossa and inclination of the articular eminence in patients with internal derangement and in symptom-free volunteers. *Oral Surg Oral Med Oral Pathol Oral Radiol Endod*. 2001;92(1):98–107.
- Kurita H, Ohtsuka A, Kobayashi H, Kurashina K. Flattening of the articular eminence correlates with progressive internal derangement of the temporomandibular joint. *Dentomaxillofac Radiol*. 2000;29(5):277–279.
- Gökalp H, Türkkahraman H, Bzeize N. Correlation between eminence steepness and condyle disc movement in temporomandibular joints with internal derangements on magnetic resonance imaging. *Eur J Orthod*. 2001;23(5):579–584.
- Galnate G, Paesani D, Tallents RH, Hatala MA, Katzberg RW, Murphy W. Angle of the articular eminence in patients with temporomandibular joint dysfunction and asymptomatic volunteers. *Oral Surg Oral Med Oral Pathol Oral Radiol Endod*. 1995;80(2):242–249.
- Jasinevicius TR, Pyle MA, Lalumandier JA, et al. Asymmetry of the articular eminence in dentate and partially edentulous populations. *Cranio*. 2006;24(2):85–94.
- Kijima N, Honda K, Kuroki Y, Sakabe J, Ejima K, Nakajima I. Relationship between patient characteristics, mandibular head morphology and thickness of the roof of the glenoid fossa in symptomatic temporomandibular joints. *Dentomaxillofac Radiol*. 2007;36(5):277–281.
- Tsuruta A, Yamada K, Hanada K, et al. Thickness of the roof of the glenoid fossa and condylar bone change: A CT study. *Dentomaxillofac Radiol*. 2003;32(4):217–221.
- Maeda Y, Mori T, Maeda N, Tsutsumi S, Nokubi T, Okuno Y. Biomechanical simulation of the morphology change in the temporomandibular joint. Part 1: Factors influencing stress distribution. *J Jap Soc Temporomand Joint*. 1991;3(1):1–9.
- Honda K, Larheim TA, Sano T, Hashimoto K, Shinoda K, Westesson PL. Thickening of the glenoid fossa in osteoarthritis of the temporomandibular joint: An autopsy study. *Dentomaxillofac Radiol*. 2001;30(1):10–13.



# Smile attractiveness perception regarding buccal corridor size among different facial types

## Percepcja atrakcyjności uśmiechu w zależności od wielkości korytarza policzkowego w różnych typach twarzy

Vahid Mollabashi<sup>1,A-F</sup>, Masoud Abolvardi<sup>1,A-F</sup>, Marzieh Akhlaghian<sup>2,B,D,F</sup>, Mohammad Ibrahim Ghaffari<sup>3,C</sup>

<sup>1</sup> Department of Orthodontics, School of Dentistry, Hamadan University of Medical Sciences, Iran

<sup>2</sup> Department of Prosthodontics, School of Dentistry, Shiraz University of Medical Sciences, Iran

<sup>3</sup> Department of Biostatistics, School of Public Health, Hamadan University of Medical Sciences, Iran

A – research concept and design; B – collection and/or assembly of data; C – data analysis and interpretation; D – writing the article; E – critical revision of the article; F – final approval of the article

Dental and Medical Problems, ISSN 1644-387X (print), ISSN 2300-9020 (online)

*Dent Med Probl.* 2018;55(3):305–312

### Address for correspondence

Masoud Abolvardi  
E-mail: [abolvardim@gmail.com](mailto:abolvardim@gmail.com)

### Funding sources

Hamadan University of Medical Sciences, Iran  
(grant No. 950304950).

### Conflict of interest

None declared

Received on May 19, 2018

Reviewed on June 9, 2018

Accepted on June 26, 2018

## Abstract

**Background.** The width of the buccal corridor (BC) is one of the factors affecting smile attractiveness.

**Objectives.** The aim of this study was to determine the effects of the BC size on the smile attractiveness of individuals with short, normal and long faces from the viewpoint of laypersons, general dentists and orthodontists.

**Material and methods.** Smiling photographs of male and female subjects who met the inclusion criteria were digitally altered to create 3 BC sizes (narrow: 2%; normal: 15%; wide: 28%) and 3 facial types defined by the facial index (FI) (short face:  $FI \leq 83.9$ ; normal face:  $84.0 \leq FI \leq 87.9$ ; long face:  $FI \geq 88.0$ ). Nine different combinations were made and the evaluators rated the overall attractiveness and acceptability of each smile on a 10-millimeter visual analog scale (VAS).

**Results.** A total of 53 raters (22 laypersons, 16 general dentists and 15 orthodontists) participated in this study. The orthodontists and general dentists had similar viewpoints and they preferred narrow and normal BCs over the wide ones in all facial types. Laypersons preferred normal BC for normal faces, while they did not distinguish different BCs in short faces.

**Conclusions.** Variations in the BC size affect smile attractiveness in different facial types and wide BCs are attributed to the least attractive smiles. Due to the different viewpoints of laypersons and professionals in this regard, there is no justification for expanding the maxillary arch to achieve more attractive smiles.

**Key words:** buccal corridor, smile attractiveness, facial type

**Słowa kluczowe:** korytarz policzkowy, atrakcyjność uśmiechu, kształt twarzy

### DOI

10.17219/dmp/92317

### Copyright

© 2018 by Wrocław Medical University  
and Polish Dental Society

This is an article distributed under the terms of the  
Creative Commons Attribution Non-Commercial License  
(<http://creativecommons.org/licenses/by-nc-nd/4.0/>)

## Introduction

The increasing impact of facial attractiveness on self-perception and the way we are viewed by society cannot be overlooked.<sup>1–3</sup> There are many different factors that constitute facial attractiveness.<sup>4–6</sup> Among them, smile attractiveness is one of the most important. It affects our acceptability in social relationships by increasing self-confidence and results in communicating with a more confident feeling.<sup>7–9</sup>

In an attractive smile, a series of factors, including consonant curvature of the upper dental arch with the lower lip, proper alignment of the teeth with no crowding and no spacing, the width of buccal corridors (BCs), the amount of dental and gingival display, the color of the teeth and gingiva, absence of cant in the occlusal plane, and the number of teeth displayed during the smile are involved.<sup>10–14</sup> On the other hand, the facial type (long face, short face or normal face) is another fundamental factor involved in determining smile attractiveness.<sup>15</sup>

Among the abovementioned factors, the BC width is the most challenging factor in smile attractiveness, as there is no consensus in the literature about its ideal size.<sup>9,16,17</sup> This can be related to different etiologic factors affecting the size of BC, like maxillary deficiency in either transverse or sagittal dimensions,<sup>9,18–22</sup> and extractions in the upper arch as a result of previous tooth loss or the orthodontic treatment plan.<sup>23</sup> Most of the studies investigating the impact of BC on smile attractiveness used only close-up images of smiles.<sup>24–26</sup> However, studies evaluating smile attractiveness should consider the facial type of the patient. The width of BCs in different facial types may seem different.<sup>17</sup> At the same time, the perception of smile beauty and attractiveness may vary among different persons and among different societies. Smile attractiveness perception of a layperson may differ from that of professionals.<sup>27,28</sup> Many articles have examined the effects of BC and the facial type on smile attractiveness,<sup>29–34</sup> but no one has simultaneously evaluated the effect of these 2 factors from the viewpoints of laypersons, general dentists and orthodontists.

The present study is designed to assess smile attractiveness with regard to a different width of BC in different facial types from the viewpoint of general dentists, orthodontists and orthodontic patients as laypersons.

## Material and methods

### Ethical approval and consent

Ethical approval for this cross-sectional study was obtained from the Hamadan University of Medical Sciences Ethics Committee (Code: IR.UMSHA.REC.1395.36) and informed written consent was obtained from each patient whose photograph was used.

### Image series construction

The frontal posed smile view of 2 subjects (1 male and 1 female) who met the inclusion criteria was chosen for this study. The inclusion criteria were as follows:

- complete incisors shown at smile (100%);
- coordination between the upper dental arch and the curvature of the lower lip during the smile (consonant smile arch);
- ideal anterior tooth alignment with no crowding and no spacing;
- medium BC size (15% of the distance between the right and left commissures)<sup>17,35,36</sup>;
- normal (mesoprosopic) facial type (facial index (FI) = 84.0–87.9%).<sup>34</sup>

The facial type of the subjects was determined using FI, which is the result of the division of the anterior face height (mm) by the bizygomatic width (mm). Anterior face height is the distance between the nasion soft tissue (Na) and the menton soft tissue (Men). The bizygomatic width of the face is the distance between the most prominent points on the zygomatic arches.

$$FI = [(Na - Men) / \text{bizygomatic width}] \times 100,$$

where:

FI – facial index;

Na – nasion soft tissue;

Men – menton soft tissue.

After filling out the informed consent form, each patient's frontal posed smile photograph was changed using Adobe Photoshop (CS5; Adobe Systems, San Jose, USA) to produce 2 types of independent variables:

- 3 different facial types according to the following standards: euryprosopic (short face):  $FI \leq 83.9$ ; mesoprosopic (normal face):  $84.0 \leq FI \leq 87.9$ ; and leptoprosopic (long face):  $FI \geq 88.0$ ;
- 3 different types of the BC size: narrow: 2% of the distance between the right and left lip commissures; normal: 15% of the distance between the right and left lip commissures; and wide: 28% of the distance between the right and left lip commissures.

Combining the 2 variables, 9 different posed smile photographs of each subject were obtained (Fig. 1,2). Then, the photographs were numbered in a randomized order, determined by the website [www.randomizer.org](http://www.randomizer.org), and these randomized sequences were given to each rater.

### Raters

Three groups of raters were involved in this study:

- laypersons – orthodontic patients who had not started their orthodontic treatment yet (to avoid any impact of the expertise of orthodontists on their point of view);



Fig. 1. Female subject sequence of smiles (different BC sizes and different facial types)  
BC – buccal corridor.

- general dentists – general dentists who had not participated in orthodontic courses;
- orthodontists – orthodontists with clinical experience of at least 1 year.

The generated randomized sequences were shown to each evaluator; they were asked to rate the smile attractiveness of each picture by selecting a point along a visual analog scale (VAS), 10 cm (100 mm) in length. The VAS consisted of a bar labeled “Zero: the least attractive smile” on the left and “Ten: the most attractive one” on the right. The rate of smile attractiveness was reported as a value from 0 to 10. Smile attractiveness evaluations were done twice, with an interval of 4 weeks. In order to determine the reliability of the evaluations, 18 raters were selected randomly in such a way that each rater group included 6 samples.

### Statistical analysis

Establishing a statistical power of 95% and  $\alpha$  level of 0.05, the calculated sample size for each group of raters was 14 individuals. The data was analyzed by SPSS v. 17.0 software (IBM Corp., Armonk, USA). The repeated measures analysis of variance (ANOVA) was utilized for comparing differences between the groups. The least significant differ-




Fig. 2. Male subject sequence of smiles (different BC sizes and different facial types)  
BC – buccal corridor.

ence (LSD) test was used for all pairwise comparisons. The intraclass correlation coefficient (ICC) was used to find the correlation between the 1<sup>st</sup> and the 2<sup>nd</sup> VAS score.

### Results

A total of 53 raters – 29 males (54.7%) and 24 females (45.3%) – participated in this study (22 laypersons, 16 general dentists and 15 orthodontists). The average age of the raters was  $25.63 \pm 7.87$  years for laypersons,  $29.93 \pm 5.84$  years for general dentists and  $34.73 \pm 7.54$  years for orthodontists (Table 1). The average period of clinical experience was  $5.56 \pm 1.39$  years and  $5.86 \pm 1.39$  years for general dentists and orthodontists, respectively.

Table 1. Descriptive characteristics of the raters

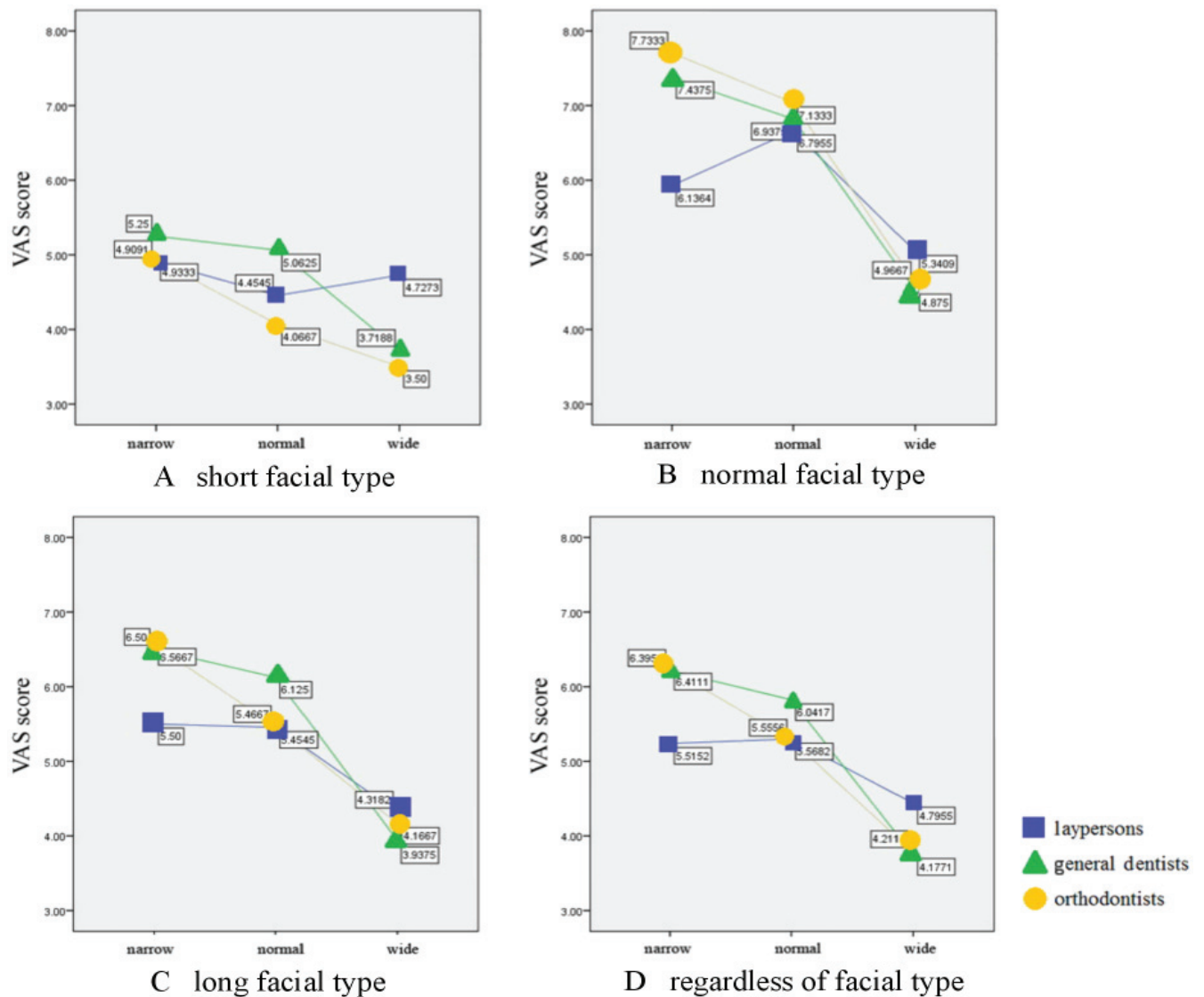
Raters	Number (%)	Age [years] mean $\pm$ SD	Clinical experience [years] mean $\pm$ SD
Laypersons	22 (41.5)	25.63 $\pm$ 7.87	–
General dentists	16 (30.2)	29.93 $\pm$ 5.84	5.56 $\pm$ 1.39
Orthodontists	15 (28.3)	34.73 $\pm$ 7.54	5.86 $\pm$ 1.39
Total	53 (100)	29.50 $\pm$ 8.03	–

SD – standard deviation.

**Table 2.** Smile attractiveness scores (VAS score), expressed as mean ± standard deviation (SD), among different groups of BCs in different facial types compared using repeated measures analysis of variance (ANOVA)

Facial type	Raters	Narrow BC	Normal BC	Wide BC	p-value
Short face	layperson	4.91 ±0.41	4.45 ±0.32	4.73 ±0.38	0.496
	general dentist	5.25 ±0.41	5.06 ±0.36	3.72 ±0.38	0.002
	orthodontist	4.93 ±0.41	4.07 ±0.30	3.50 ±0.44	<0.001
Normal face	layperson	6.14 ±0.37	6.80 ±0.31	5.34 ±0.30	0.003
	general dentist	7.44 ±0.39	6.94 ±0.32	4.87 ±0.39	<0.001
	orthodontist	7.73 ±0.38	7.13 ±0.36	4.97 ±0.41	<0.001
Long face	layperson	5.50 ±0.34	5.45 ±0.32	4.32 ±0.34	<0.001
	general dentist	6.50 ±0.37	6.12 ±0.37	3.94 ±0.44	<0.001
	orthodontist	6.57 ±0.40	5.47 ±0.35	4.17 ±0.35	<0.001
Regardless of facial type	layperson	5.51 ±0.22	5.57 ±0.20	4.79 ±0.20	<0.001
	general dentist	6.40 ±0.24	6.04 ±0.21	4.18 ±0.24	<0.001
	orthodontist	6.41 ±0.26	5.56 ±0.23	4.21 ±0.24	<0.001

VAS – visual analog scale; BC – buccal corridor.



**Fig. 3.** Smile attractiveness scores (VAS score) among different groups of BCs in different facial types VAS – visual analog scale; BC – buccal corridor.

**Table 3.** Pairwise comparisons using the LSD test of smile attractiveness scores (VAS score), expressed as mean  $\pm$  standard deviation (SD), among different groups of BCs in different facial types

Facial type	Raters	BC type		p-value
Short face	layperson	narrow	normal	0.222
		narrow	wide	0.656
		normal	wide	0.478
		narrow	normal	0.698
		narrow	wide	0.001
	general dentist	normal	wide	0.005
		narrow	normal	0.001
		narrow	wide	<0.001
		normal	wide	0.081
		Normal face	layperson	narrow
narrow	wide			0.066
normal	wide			<0.001
narrow	normal			0.161
narrow	wide			<0.001
general dentist	normal		wide	<0.001
	narrow		normal	0.062
	narrow		wide	<0.001
	normal		wide	<0.001
	Long face		layperson	narrow
narrow		wide		<0.001
normal		wide		<0.001
narrow		normal		0.419
narrow		wide		<0.001
general dentist		normal	wide	<0.001
		narrow	normal	0.004
		narrow	wide	<0.001
		normal	wide	0.001
		Regardless of facial type	layperson	narrow
narrow	wide			0.001
normal	wide			<0.001
narrow	normal			0.155
narrow	wide			<0.001
general dentist	normal		wide	<0.001
	narrow		normal	<0.001
	narrow		wide	<0.001
	normal		wide	<0.001
	orthodontist		narrow	wide
normal		wide	<0.001	

LSD test – the least significant difference test; VAS – visual analog scale; BC – buccal corridor.

All 53 raters returned their completed papers. A good agreement between the 1<sup>st</sup> and the 2<sup>nd</sup> evaluation of smile attractiveness was observed (ICC = 0.884–0.952).

In the short facial type, repeated measurements ANOVA showed a significant difference among smile attractiveness of different BC groups rated by orthodontists ( $p < 0.001$ ) and general dentists ( $p = 0.002$ ) (Table 2). General dentists' high score was  $5.25 \pm 0.41$  for the narrow BC type. They preferred narrow and normal BC types over the wide type ( $p = 0.001$  and  $p = 0.005$ , respectively), but there was no difference between the narrow and normal ones

( $p = 0.698$ ). Orthodontists' high score was  $4.93 \pm 0.41$  for the narrow BC type. They preferred narrow over normal and wide BC types ( $p = 0.001$  and  $p < 0.001$ , respectively), but there was no difference between the normal and wide types ( $p = 0.081$ ). While laypersons' scores showed no significant difference among different BC groups ( $p = 0.496$ ), the narrow type reached the highest score ( $4.91 \pm 0.41$ ) (Table 3, Fig. 3).

In the normal facial type, a significant difference in smile attractiveness was seen among different BC groups rated by laypersons ( $p = 0.003$ ), general dentists ( $p < 0.001$ ) and

orthodontists ( $p < 0.001$ ) (Table 2). Laypersons' high score was  $6.80 \pm 0.31$  for the normal BC type. They preferred the normal over the wide type ( $p < 0.001$ ), but there was no difference between the narrow and normal types ( $p = 0.144$ ) and between the narrow and wide ones ( $p = 0.066$ ). General dentists, with a high score of  $7.44 \pm 0.39$  for the narrow BC type, preferred the narrow and normal over the wide type ( $p < 0.001$  for both), but there was no difference between the narrow and normal ones ( $p = 0.161$ ). Orthodontists' high score ( $7.73 \pm 0.38$ ) was assigned to the narrow BC type. They preferred the narrow and normal over the wide type ( $p < 0.001$  for both), but there was no difference between the narrow and normal types ( $p = 0.062$ ) (Table 3, Fig. 3).

With respect to the long facial type, a significant difference in smile attractiveness was seen among different BC groups rated by laypersons ( $p < 0.001$ ), general dentists ( $p < 0.001$ ) and orthodontists ( $p < 0.001$ ) (Table 2). Laypersons, with a high score of  $5.50 \pm 0.34$  for the narrow BC type, preferred the narrow and normal over the wide BC type ( $p < 0.001$  for both), but there was no difference between the narrow and normal types ( $p = 0.870$ ). General dentists' high score was  $6.50 \pm 0.37$  for the narrow BC type. They also preferred the narrow and normal types over the wide BC type ( $p < 0.001$  for both), but there was no difference between the narrow and normal ones ( $p = 0.419$ ). Orthodontists' high scores ( $6.57 \pm 0.40$  and  $5.47 \pm 0.35$ ) were assigned to the narrow and normal BC types, respectively. They preferred the narrow over the normal ( $p = 0.004$ ) and wide types ( $p < 0.001$ ). They also preferred the normal over the wide BC type ( $p = 0.001$ ) (Table 3, Fig. 3).

Overall, regardless of facial types, a significant difference in smile attractiveness was seen among the different BC groups rated by laypersons ( $p < 0.001$ ), general dentists ( $p < 0.001$ ) and orthodontists ( $p < 0.001$ ) (Table 2). Laypersons gave a high score of  $5.57 \pm 0.20$  to the normal BC type. They preferred the narrow and normal types over the wide one ( $p = 0.001$  and  $p < 0.001$ , respectively), but there was no difference between the narrow and normal types ( $p = 0.805$ ). General dentists' high score was  $6.40 \pm 0.24$  and it was assigned to the narrow BC type. They preferred the narrow and normal over the wide BC type ( $p < 0.001$  for both), but there was no difference between the narrow and normal ones ( $p = 0.155$ ). Orthodontists' high score was  $6.41 \pm 0.26$  for the narrow BC type. They preferred the narrow over the normal and wide types, and also the normal over the wide BCs ( $p < 0.001$  for all) (Table 3, Fig. 3).

## Discussion

The present study investigated the impact of the BC size among different facial types on the attractiveness of the smile. Previous studies showed both of these factors were

important in this regard.<sup>9,16,17</sup> Furthermore, in the literature, different judgments of smile attractiveness by different raters have been shown.<sup>27,28,30,37</sup> Some studies assessed in this regard 5 different sizes of BC (2%, 10%, 15%, 22%, and 28%)<sup>17,35,36</sup> and some others used 6 sizes (0%, 5%, 10%, 15%, 20%, and 25%).<sup>30,37</sup> In our study, we constructed only 3 sizes of BC (2%, 15% and 28%). These were matched to the narrow, medium and wide sizes of the other studies and they seemed to be simpler to differentiate, especially for laypersons. Furthermore, regarding the facial type, some of the studies assessed just 2 facial types (short face and long face)<sup>17</sup> and some assessed 3 facial types.<sup>36</sup> We constructed 3 facial types (short face, normal face and long face) according to FI in order to compare smile attractiveness in each facial type.

Finally, regarding raters, most of the studies compared 2 types of raters, usually orthodontists and laypersons.<sup>17,30,37</sup> In our study, we used 3 groups of raters: orthodontists, general dentists and laypersons. This design could cover different judgments between laypersons and professionals, and also differences between the viewpoints of general dentists and orthodontists, who are both highly involved in dental treatment plans and consultations.

Our results showed a total agreement from the viewpoints of general dentists and orthodontists. Although it was not always statistically significant, these raters preferred narrow over normal, and normal over wide BC types in all facial types. On the other hand, laypersons preferred normal and narrow types over the wide one, with the highest score for the normal BC type. This difference between raters' viewpoints could be fundamental for practitioners when deciding upon expansion/extraction treatments plans, especially in borderline cases. The results showed that, although it was not statistically significant, the normal BC size was more attractive than narrow one from the point of view of laypersons. On the other hand, professionals preferred expanded arches with narrow BCs over the normal ones. Furthermore, both laypersons and professionals believed that wide BCs were attributed to the least attractive smiles, and this was consistent with the results of previous studies.<sup>17,30,37</sup> Therefore, it could be concluded that in normal BC size patients with any facial type, it is better to maintain or expand the upper arch. Treatment plans which increase the width of the BC are not preferable from the viewpoints of any of the raters.

As discussed above, wide BCs resulted in the least attractive smiles in all facial types and among all raters, with the exception of the short facial type in the opinion of laypersons. When laypersons judged smile attractiveness in the short facial type, the wide BC type had a score of  $4.73 \pm 0.38$ , which was between the normal and narrow BCs scores ( $4.45 \pm 0.32$  and  $4.91 \pm 0.41$ , respectively). Statistical analysis showed that there was no significant difference between each of these scores. This unusual pattern could be related to such factors as total lower scores

of short facial types than other facial types or the small sample size of raters. On the other hand, when all facial types are combined together, a predictable pattern is observed in the laypersons' opinions. They also marked the wide BC type as the least attractive one.

In the present study, all raters could distinguish the impact of different BCs on smile attractiveness in normal and long facial types, but laypersons could not differentiate between different BCs in short faces (Table 2). These findings are consistent with the results obtained by Zange et al. as to the long facial type part; orthodontists in both studies preferred the narrow BC for long face patients and they could differentiate between each pair of BC sizes.<sup>17</sup> Laypersons were unable to differentiate the attractiveness of smiles except for the wide BC type. Conversely, in regard to the short facial type, our study is in contrast to the study by Zange et al.<sup>17</sup> While we observed that laypersons could not find the differences between each BC, Zange et al. reported that laypersons differentiated each of the BC sizes included in our study (2%, 15% and 28%). Comparing the methodology, they constructed a video of photographs in which raters had only 15 s to evaluate each image and could not go back to see the previous image. They also were not able to compare the images at the same time. In our study, we showed all 9 images of both patients at the same time, with no restriction on the time of evaluation.

Our study investigated the impact of the BC size among different facial types from different viewpoints. It is suggested for future investigators to consider the effect of the patients' sex and also to analyze the viewpoints of different raters, regarding not only their profession, but also their gender, in order to clarify whether the sex of the patients and/or of the raters has any effect on the results.

## Conclusions

For all facial types, orthodontists and general dentists similarly stated that the narrower the BCs are, the more attractive the smile is. Wide (28%) BCs were attributed to the least attractive smiles in all facial types. In normal faces, laypersons, in contrast to the professionals, preferred the normal (15%) BC size. They also could not differentiate the effects of different BCs on the smile attractiveness of the short facial type.

## References

- Brown A, Knight T. Shifts in media images of women appearance and social status from 1960 to 2010: A content analysis of beauty advertisements in two Australian magazines. *J Aging Stud.* 2015;35:74–83.
- Jack RE, Schyns PG. The human face as a dynamic tool for social communication. *Curr Biol.* 2015;25(14):R621–634.
- Dion K, Berscheid E, Walster E. What is beautiful is good. *J Pers Soc Psychol.* 1972;24(3):285–290.
- Faure J, Bolender Y. Beauty judgment: Review of the literature [in French]. *Orthod Fr.* 2014;85(1):3–29.
- Heppt WJ, Vent J. The facial profile in the context of facial aesthetics. *Facial Plast Surg.* 2015;31(5):421–430.
- Tole N, Lajnert V, Kovacevic Pavicic D, Spalj S. Gender, age, and psychosocial context of the perception of facial esthetics. *J Esthet Restor Dent.* 2014;26(2):119–130.
- Van der Geld P, Oosterveld P, Van Heck G, Kuijpers-Jagtman AM. Smile attractiveness. Self-perception and influence on personality. *Angle Orthod.* 2007;77(5):759–765.
- LaFrance M, Hecht MA, Paluck EL. The contingent smile: A meta-analysis of sex differences in smiling. *Psychol Bull.* 2003;129(2):305–334.
- Ackerman JL, Ackerman MB, Brensinger CM, Landis JR. A morphometric analysis of the posed smile. *Clin Orthod Res.* 1998;1(1):2–11.
- Ahrari F, Heravi F, Rashed R, Zarrabi MJ, Setayesh Y. Which factors affect dental esthetics and smile attractiveness in orthodontically treated patients? *J Dent (Tehran).* 2015;12(7):491–503.
- Kaya B, Uyar R. The impact of occlusal plane cant along with gingival display on smile attractiveness. *Orthod Craniofac Res.* 2016;19(2):93–101.
- Machado AW, McComb RW, Moon W, Gandini LG. Influence of the vertical position of maxillary central incisors on the perception of smile esthetics among orthodontists and laypersons. *J Esthet Restor Dent.* 2013;25(6):392–401.
- Sarver DM. The importance of incisor positioning in the esthetic smile: The smile arc. *Am J Orthod Dentofacial Orthop.* 2001;120(2):98–111.
- Jenny J. A social perspective on need and demand for orthodontic treatment. *Int Dent J.* 1975;25(4):248–256.
- Johnston DJ, Hunt O, Johnston CD, Burden DJ, Stevenson M, Hepper P. The influence of lower face vertical proportion on facial attractiveness. *Eur J Orthod.* 2005;27(4):349–354.
- Proffit WR, Fields HW, Sarver DM. *Contemporary Orthodontics.* 4th ed. St. Louis, MO: Mosby; 2007:187,188.
- Zange SE, Ramos AL, Cuoghi OA, de Mendonça MR, Suguino R. Perceptions of laypersons and orthodontists regarding the buccal corridor in long- and short-face individuals. *Angle Orthod.* 2011;81(1):86–90.
- Sarver DM, Ackerman MB. Dynamic smile visualization and quantification: Part 1. Evolution of the concept and dynamic records for smile capture. *Am J Orthod Dentofacial Orthop.* 2003;124(1):4–12.
- Sarver DM, Ackerman MB. Dynamic smile visualization and quantification: Part 2. Smile analysis and treatment strategies. *Am J Orthod Dentofacial Orthop.* 2003;124(2):116–127.
- McNamara JA. Maxillary transverse deficiency. *Am J Orthod Dentofacial Orthop.* 2000;117(5):567–570.
- Ackerman JL, Proffit WR, Sarver DM. The emerging soft tissue paradigm in orthodontic diagnosis and treatment planning. *Clin Orthod Res.* 1999;2(2):49–52.
- Ackerman MB. Buccal smile corridors. *Am J Orthod Dentofacial Orthop.* 2005;127(5):528–529.
- Ghafari JG. Emerging paradigms in orthodontics – an essay. *Am J Orthod Dentofacial Orthop.* 1997;111(5):573–580.
- Rittera DE, Gandini L, Pinto Ados S, Locks A. Esthetic influence of negative space in the buccal corridor during smiling. *Angle Orthod.* 2006;76(2):198–203.
- Parekh S, Fields HW, Beck FM, Rosenstiel SF. The acceptability of variations in smile arc and buccal corridor space. *Orthod Craniofac Res.* 2007;10(1):15–21.
- Maulik C, Nanda R. Dynamic smile analysis in young adults. *Am J Orthod Dentofacial Orthop.* 2007;132(3):307–315.
- Jørnung J, Fardal Ø. Perceptions of patients' smiles: A comparison of patients' and dentists' opinions. *J Am Dent Assoc.* 2007;138(12):1544–1553;quiz 613,614.
- Springer NC, Chang C, Fields HW, et al. Smile esthetics from the layperson's perspective. *Am J Orthod Dentofacial Orthop.* 2011;139(1):e91–e101.
- Meyer AH, Woods MG, Manton DJ. Maxillary arch width and buccal corridor changes with orthodontic treatment. Part 2: Attractiveness of the frontal facial smile in extraction and nonextraction outcomes. *Am J Orthod Dentofacial Orthop.* 2014;145(3):296–304.
- Ioi H, Kang S, Shimomura T, et al. Effects of buccal corridors on smile esthetics in Japanese and Korean orthodontists and orthodontic patients. *Am J Orthod Dentofacial Orthop.* 2012;142(4):459–465.

31. Janson G, Branco NC, Fernandes TM, Sathler R, Garib D, Lauris JR. Influence of orthodontic treatment, midline position, buccal corridor and smile arc on smile attractiveness. *Angle Orthod.* 2011;81(1):153–161.
32. Grover N, Kapoor DN, Verma S, Bharadwaj P. Smile analysis in different facial patterns and its correlation with underlying hard tissues. *Prog Orthod.* 2015;16:28.
33. Chou JC, Thompson GA, Aggarwal HA, Bosio JA, Irelan JP. Effect of occlusal vertical dimension on lip positions at smile. *J Prosthet Dent.* 2014;112(3):533–539.
34. Williams RP, Rinchuse DJ, Zullo TG. Perceptions of midline deviations among different facial types. *Am J Orthod Dentofacial Orthop.* 2014;145(2):249–255.
35. Oshagh M, Zarif NH, Bahramnia F. Evaluation of the effect of buccal corridor size on smile attractiveness. *Eur J Esthet Dent.* 2010;5(4):370–380.
36. Pithon MM, Rocha KS, Costa BdN, et al. Perceptions of brachyfacial, mesofacial and dolichofacial individuals with regard to the buccal corridor in different facial types. *J Appl Oral Sci.* 2014;22(3):382–389.
37. Ioi H, Nakata S, Counts AL. Effects of buccal corridors on smile esthetics in Japanese. *Angle Orthod.* 2009;79(4):628–633.



# Self-reported oral status and habits related to oral care in adult Poles: A questionnaire study

## Samoocena stanu jamy ustnej i nawyków związanych z opieką stomatologiczną dorosłych Polaków – badanie ankietowe

Renata Górską<sup>A,E,F</sup>, Bartłomiej Górski<sup>B–D</sup>

Department of Periodontology and Oral Diseases, Medical University of Warsaw, Poland

A – research concept and design; B – collection and/or assembly of data; C – data analysis and interpretation; D – writing the article; E – critical revision of the article; F – final approval of the article

Dental and Medical Problems, ISSN 1644-387X (print), ISSN 2300-9020 (online)

*Dent Med Probl.* 2018;55(3):313–320

### Address for correspondence

Bartłomiej Górski  
E-mail: bartek\_g3@tlen.pl

### Funding sources

None declared

### Conflict of interest

None declared

### Acknowledgements

Authors would like to thank Prof. Elżbieta Dembowska, Prof. Maria Chomyszyn-Gajewska, PhD Natalia Lewkowicz, Prof. Tomasz Konopka, DDS Urszula Korzeniowska, Prof. Aida Kusiak, DDS Ewa Maliszewska-Bukowińska, PhD Zdzisława Sawkiewicz, PhD Beata Wierucka-Młynarczyk, and DDS Patrycja Załęska for their help with the acquisition of data.

Received on March 19, 2018

Reviewed on May 14, 2018

Accepted on May 28, 2018

### DOI

10.17219/dmp/92317

### Copyright

© 2018 by Wrocław Medical University  
and Polish Dental Society

This is an article distributed under the terms of the  
Creative Commons Attribution Non-Commercial License  
(<http://creativecommons.org/licenses/by-nc-nd/4.0/>)

## Abstract

**Background.** Bacterial plaque control plays a key role in the prevention of caries and periodontal diseases. Hygiene negligence in this respect may influence the state of gingiva, and – in the long term – the number of lost teeth. The recommended method of mechanical control of dental plaque is tooth brushing twice a day.

**Objectives.** The aim of the study was to assess the frequency of tooth brushing, the use of various oral hygiene accessories, the number of preserved teeth, and the occurrence of gingival bleeding in adult Poles, based on a questionnaire study.

**Material and methods.** The prepared questionnaire consisted of a general part, assessing the socio-economic and general medical status of respondents, as well as of specific questions about behavioral actions related to oral hygiene. The study was conducted in 10 Polish cities in Mobile Medical Units as part of the “Health First” campaign in 2017.

**Results.** The study included 713 respondents: 447 females and 264 males at an average age of  $51.1 \pm 17.6$  years. During the previous 6 months, 448 females and 265 males had visited the dentist. The average number of teeth among the respondents aged 35–44 years was 27, and for subjects >65 years old – 13. There were statistically significant differences in the frequency of tooth brushing depending on sex and place of residence. The respondents used manual soft and medium toothbrushes more often than electric brushes ( $p < 0.05$ ). Inhabitants of larger cities, compared to rural residents, used dental floss and toothpicks more frequently ( $p < 0.05$ ). In total, 271 (50%) of the respondents reported gingival bleeding during tooth brushing. There was a statistically significant association of gingival bleeding with genetic load, and with the use of a manual soft toothbrush and mouthwash.

**Conclusions.** Pro-health behaviors of adult Poles in maintaining optimal oral hygiene are unsatisfactory and need improvement.

**Key words:** dental prophylaxis, gingivitis, dental plaque, toothbrush

**Słowa kluczowe:** profilaktyka stomatologiczna, zapalenie dziąseł, płytka nazębna, szczoteczka do zębów

## Introduction

Bacteria present in the oral cavity are characterized by the formation of biofilms.<sup>1</sup> Natural accumulation of supragingival plaque on tooth surfaces is associated with the development of gingivitis. The symptoms of gingivitis include change in color, shape, consistency of gingiva, as well as bleeding while tooth brushing and eating hard foods. Bacterial plaque accumulation is also an etiological factor of dental caries. Regular, mechanical plaque control is, therefore, of fundamental importance in maintaining oral health and constitutes the basis in prevention of the most common oral cavity infections: caries and periodontal diseases.

Supragingival plaque should be removed mechanically by a regular use of a toothbrush at least twice a day. The effectiveness of this procedure depends on the type of toothbrush, brushing technique, patient's motivation, time and frequency of brushing. It should be remembered that the occurrence of supragingival plaque varies depending on the tooth surface and the position of the tooth in the arch. Studies have shown that plaque accumulation is greater on lingual surfaces of teeth and on molars in comparison with anterior teeth.<sup>2,3</sup> Supragingival plaque is also more common on interproximal surfaces of teeth than on vestibular surfaces. In order to reduce the retention of plaque in interdental spaces, it is necessary to use daily additional accessories, such as dental floss and interdental brushes. Besides, mechanical control of bacterial plaque can be supplemented with the use of mouthwash, which – by means of chemical control – reduces the deposition of biofilm also on adhesive surfaces other than hard tissues of teeth, such as mucosal membrane. The use of antiseptics contributes to a greater reduction of plaque and gingivitis.<sup>4</sup> On the other hand, the sole use of mouthwash is not an effective way to control bacterial biofilm.<sup>5</sup> Implementation of various methods of maintaining optimal oral hygiene is particularly important in populations where an increased occurrence of oral infections is observed.

In the population of adult Poles, gingivitis is found in more than 98% of individuals, and almost 100% of subjects suffer from caries.<sup>6–8</sup> Over 16% of Poles aged 35–44 years and almost 20% of those aged 65–74 years require comprehensive and advanced periodontal treatment, which indicates large limitations in the field of dental care.<sup>6,7</sup> Unfavorable oral health situation occurs despite unlimited availability of various oral hygiene products present on the market. One should also take into account the importance of pro-health awareness of patients, the socio-economic and behavioral conditions, as well as raising their sense of co-responsibility for the state of their own health, which is particularly important in the case of social infectious diseases, such as caries and periodontal diseases.

The aim of the study was to assess the frequency of tooth brushing, the use of various oral hygiene accessories, the number of preserved teeth, and the occurrence of gingival bleeding in adult Poles, based on a questionnaire study.

## Material and methods

The study was conducted in 10 Polish cities in Mobile Medical Units as a part of the “Health First” campaign in 2017. The campaign accompanied the “Summer with the Radio” route of the First Channel of the Polish Radio. Patients who approached the medical stand were asked to fill in an anonymous questionnaire. Those who completed the questionnaire form agreed to the obtained data being processed by signing the appropriate statement.

In addition to a general part, concerning gender, age, place of residence (village / medium-sized city / big city), education (primary / secondary / undergraduate / higher), height, weight, diabetes, and number of teeth present in the oral cavity, 6 additional questions were included in the questionnaire. The respondents were asked to provide information on smoking (current / in the past / never; the number of cigarettes smoked per day during the addiction period), genetic load of periodontitis (early loss of teeth in parents or siblings), date of the last visit to the dentist (visit in the last 6 months / more than 6 months, but not more than 12 months ago / over 1 year ago / over 2 years ago), frequency of tooth brushing during the day (0 times a day / once a day / twice a day / 3 times a day / 4 times a day), use of various instruments for oral hygiene (electric toothbrush / sound or sonic brush / manual toothbrush with soft bristles / manual toothbrush with medium bristles / manual toothbrush with hard bristles / interdental or monotip brush / dental floss / toothpick / tongue cleaner / irrigator / mouthwash), and occurrence of gingival bleeding during tooth brushing (never / less than once a week / once every few days / always).

All statistical analyses were performed with the STATISTICA 13 program (StatSoft Polska Sp. z o.o., Kraków, Poland). In order to compare the mean number of teeth between 2 (sex) or more groups (place of residence, education), comparisons were made using the t-test or the analysis of variance (ANOVA). The association between age and number of teeth was evaluated based on the regression analysis, using polynomial functions. The evaluation of the association between the frequency of tooth brushing and gender, age, place of residence, or education was performed using the  $\chi^2$  test. The assessment of the relationship between the occurrence of bleeding from gingiva and other factors was performed using the correlation analysis. For all the analyses, the significance level was assumed at  $p < 0.05$ .

## Results

The study included 713 subjects: 448 females and 265 males. In the case of 2 questionnaires, there was no data regarding sex. The average age was 51.1 ±17.6 years (51.1 ±17.4 years for women, 51.0 ±17.8 years for men). The characteristics of the study group are shown in Table 1. Body mass index (BMI) was calculated by dividing body weight (in kg) by height (in m<sup>2</sup>). Overweight was diagnosed in the case of BMI of 25–29.9 kg/m<sup>2</sup>, and obesity at BMI ≥ 30 kg/m<sup>2</sup>. There were statistically significant differences between the genders regarding the last visit to the dentist (p = 0.009). During the last 6 months, 265 (59.2%) females and 135 (50.9%) males visited the dental office, while 49 (10.9%) females and 50 (18.9%) males were treated earlier than 24 months ago.

No statistically significant differences were observed between the average number of teeth for each sex, as well as for place of residence (Table 2). However, there were significant differences regarding education. Changes in

Table 1. Characteristics of the study group

Parameter	Variable	n (%)
Sex	female	448 (62.8)
	male	265 (37.2)
Age [years]	≤20	37 (5)
	21–34	98 (14)
	35–44	121 (17)
	45–65	296 (42)
	>65	159 (22)
Place of residence	village	86 (12.3)
	medium-sized city	383 (54.9)
	big city	229 (32.8)
Education	primary	82 (12.2)
	secondary	313 (46.6)
	undergraduate	41 (6.1)
	higher	235 (35.0)
BMI [kg/m <sup>2</sup> ]	<18.5 (underweight)	26 (3.85)
	18.5–24.99 (normal)	258 (38.3)
	≥25 (overweight)	390 (57.9)
Nicotiniism	current	84 (13.5)
	in the past	120 (19.3)
	never	419 (67.2)
Diabetes	type I	21 (3.0)
	type II	39 (5.5)
Number of teeth depending on age	≤20 years	27.43
	21–34 years	29.47
	35–44 years	27.80
	45–65 years	21.04
Genetic susceptibility to periodontitis	yes	136 (20.7)
	no	521 (79.3)
Last visit at dental office	≤6 months ago	400 (57.2)
	>6 months and ≤12 months ago	116 (16.6)
	>12 months and ≤24 months ago	82 (11.7)
	>24 months ago	101 (14.4)

BMI – body mass index. Data presented as number (percentage).

Table 2. Average number of teeth depending on sex, place of residence and education

Age [years]	Sex		p-value		
	female	male			
≤20	28.50	26.00	0.218		
21–34	29.79	29.14	0.569		
35–44	27.56	28.00	0.741		
45–65	21.16	20.90	0.888		
>65	13.00	13.91	0.762		
General	22.10	20.79	<0.001		
Age [years]	Place of residence			p-value	
	village	medium-sized city	big city		
≤20	28.00	28.00	27.00	0.911	
21–34	26.50	29.75	29.93	0.152	
35–44	28.00	27.63	27.89	0.977	
45–65	20.94	20.08	22.09	0.627	
>65	20.25	12.77	13.91	0.296	
General	22.35	19.47	23.47	0.024	
Age [years]	Education				p-value
	primary	secondary	undergraduate	higher	
≤20	28.50	28.00	–	–	0.541
21–34	23.00	28.75	–	30.19	0.003
35–44	22.00	26.00	31.00	29.08	0.006
45–65	6.89	20.93	23.75	25.06	<0.001
>65	10.80	16.24	16.00	12.78	0.458
General	13.16	20.80	23.67	25.35	<0.001

the number of teeth depending on age, broken down by sex, place of residence and education, are shown graphically in diagrams (Fig. 1–4).

There were statistically significant differences in the frequency of tooth brushing during the day depending on sex and place of residence. Women, young adults (aged 21–34 years) living in large cities, with higher education brushed teeth more often than men, older people living in the countryside, with basic education (Table 3).

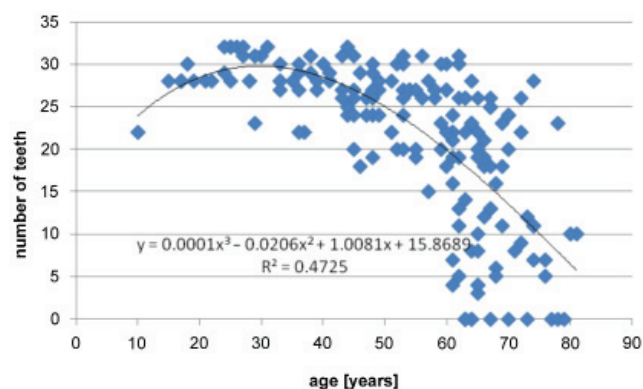


Fig. 1. Graph showing a change in the number of teeth for the whole group depending on age, with a matched regression function (3<sup>rd</sup> degree polynomial function)

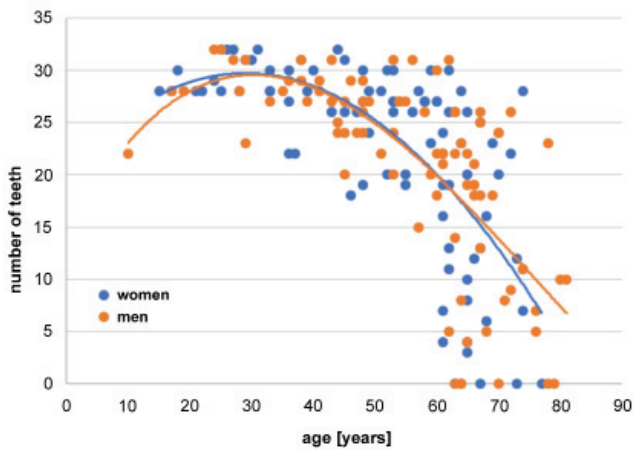


Fig. 2. Graph showing a change in the number of teeth for the whole group depending on age, broken down by sex, with a matched regression function (3<sup>rd</sup> degree polynomial function)

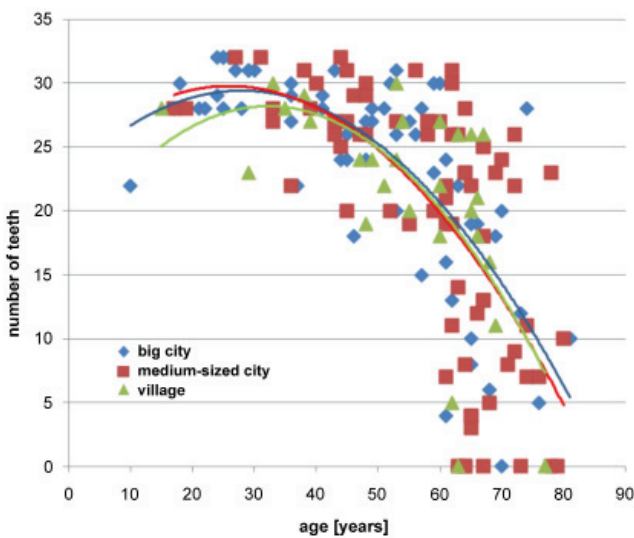


Fig. 3. Graph showing a change in the number of teeth for the whole group depending on age, broken down by place of residence, with a matched regression function (3<sup>rd</sup> degree polynomial function)

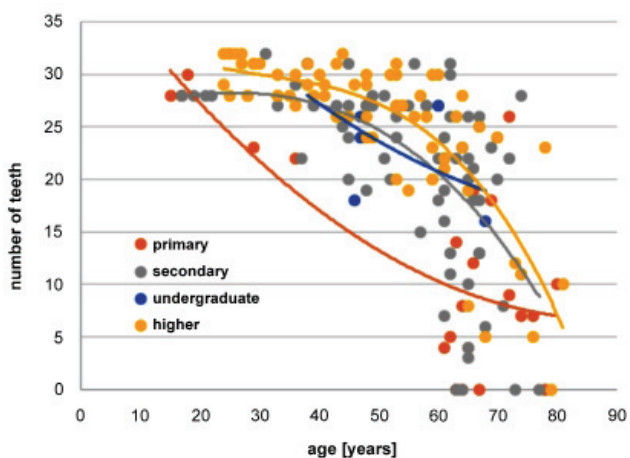


Fig. 4. Graph showing a change in the number of teeth for the whole group depending on age, broken down by education, with a matched regression function (3<sup>rd</sup> degree polynomial function)

The frequency of using various oral hygiene devices is shown in Table 4. There were no statistically significant differences between the frequency of using various types of toothbrushes with regard to gender and place of residence ( $p > 0.05$ ). On the other hand, a statistically significant increase in the use of manual toothbrushes with soft and medium bristles was observed in comparison with electric brushes ( $p < 0.05$ ). Statistically significantly higher frequency of using dental floss, tongue cleaner and mouthwash was found for women compared to men ( $p < 0.001$ ). Inhabitants of larger cities compared to rural residents used dental floss and toothpicks more often ( $p < 0.05$ ).

Two hundred sixty-five (50%) respondents never observed bleeding from gingiva while brushing their teeth, 192 (36%) had bleeding less than once a week, 51 (9%) had bleeding once every few days, while 28 (5%) respondents noticed bleeding during every tooth brushing. A statistically significant positive association of gum bleeding with genetic load, and with the use of a manual brush with soft bristles and mouthwash was observed (Table 5). The chance of bleeding decreased with age, weight, BMI, and nicotine use ( $p < 0.05$ ).

## Discussion

Evaluating pro-health behaviors within the scope of optimal oral hygiene maintenance is of great importance with regard to planning preventive programs and shaping the healthcare system. Periodontal diseases are conditions of complex etiology, but bacterial plaque remains the most important causative factor. The latest epidemiological studies of the periodontal status of adult Poles were conducted in 2012 (subjects aged 35–44 years) and in 2014 (subjects aged 65–74 years).<sup>6,7</sup> Conducting such studies is associated with both economic and organizational problems. Therefore, questionnaires may be used to analyze basic data and to evaluate simple variables as interpreted by patients. The value of surveys in comparison with well-planned epidemiological studies is certainly lower, but absolutely justified, especially with reference to socio-demographic and behavioral factors. Nonetheless, the obtained data should still be evaluated cautiously. The results presented in this work were obtained due to surveys, which were filled out by 713 respondents as part of the “Health First” program. The Mobile Medical Unit was mainly approached by adult people (42% were aged 45–65 years and 22% – over 65 years). The majority of respondents (62.9%) were women, although men are more susceptible to periodontitis (due to addictions and reluctance to visit a dental office). Individuals who volunteered to take part in the survey were mostly residents of medium-sized cities, with higher or secondary education. Only 12% were people living in the countryside with primary education. In the study group, almost 58% of the respondents were overweight or obese, almost 14% smoked, and almost 9% had diabetes.

**Table 3.** Frequency of tooth brushing depending on sex, age, place of residence, and education

Variable		0 times a day	once a day	twice a day	3 times a day	4 times a day	p-value
Sex	female	17 (3.8)	54 (12.1)	252 (56.3)	78 (17.4)	47 (10.5)	<0.001*
	male	8 (3.0)	66 (24.9)	138 (52.1)	37 (14.0)	16 (6.0)	
	general	25 (3.5)	120 (16.9)	390 (54.7)	115 (16.1)	63 (8.8)	
Age [years]	≤20	0 (0.0)	16 (43.2)	18 (48.6)	3 (8.1)	0 (0.0)	<0.001*
	21–34	1 (1.0)	10 (10.2)	57 (58.2)	21 (21.4)	9 (9.2)	
	35–44	1 (0.8)	19 (15.7)	69 (57.0)	19 (15.7)	13 (10.7)	
	45–65	11 (3.7)	46 (15.5)	171 (57.8)	44 (14.9)	24 (8.1)	
	>65	12 (7.5)	29 (18.2)	74 (46.5)	27 (17.0)	17 (10.7)	
Place of residence	village	6 (7.0)	20 (23.3)	48 (55.8)	7 (8.1)	5 (5.8)	<0.001*
	medium-sized city	15 (3.9)	70 (18.3)	204 (53.3)	74 (19.3)	20 (5.2)	
	big city	2 (0.9)	28 (12.2)	129 (56.3)	32 (14.0)	38 (16.0)	
Education	primary	6 (7.3)	29 (35.4)	37 (45.1)	7 (8.5)	3 (3.7)	<0.001*
	secondary	11 (3.5)	62 (19.8)	167 (53.4)	49 (15.7)	24 (7.7)	
	undergraduate	0 (0.0)	6 (14.6)	26 (63.4)	5 (12.2)	4 (9.8)	
	higher	3 (1.3)	18 (7.7)	136 (57.9)	49 (20.9)	29 (12.3)	

\* p-value based on the  $\chi^2$  test, which indicated relationships between frequency of tooth brushing and other categorical traits. Data presented as number (percentage).

**Table 4.** Frequency of use of various oral hygiene devices

Device	Frequency of use			
	every day	once every few days	less than once a week	never
Electric toothbrush	102 (22)	23 (5)	24 (5)	321 (68)
Sound/sonic toothbrush	15 (4)	4 (1)	8 (2)	400 (4)
Manual toothbrush with soft bristles	178 (38)	13 (3)	23 (5)	253 (54)
Manual toothbrush with medium bristles	344 (62)	25 (5)	33 (6)	149 (27)
Manual toothbrush with hard bristles	49 (12)	5 (1)	13 (53)	332 (83)
Interdental/monotip brush	26 (6)	6 (1)	20 (5)	370 (88)
Dental floss	114 (18)	130 (20)	122 (19)	271 (43)
Toothpick	103 (17)	100 (16)	115 (19)	299 (49)
Tongue cleaner	47 (8)	22 (4)	49 (8)	469 (80)
Irrigator	17 (3)	10 (2)	18 (3)	536 (92)
Mouthwash	165 (25)	120 (18)	159 (24)	219 (33)

Data presented as number (percentage).

**Table 5.** Association of various factors with occurrence of gingival bleeding (only statistically significant correlation coefficients are shown)

Variable	Correlation coefficient
Age [years]	–0.12
Weight [kg]	–0.12
BMI [kg/m <sup>2</sup> ]	–0.10
Genetic susceptibility to periodontitis	0.10
Nicotinism [years]	–0.25
Nicotinism [number of cigarettes per day]	–0.16
Using mouthwash	0.12
Using manual toothbrush with soft bristles	0.20

BMI – body mass index. Data presented as number (percentage).

When asked about the last visit to the dentist, 14% of the respondents answered that they had not been to the dental office in the last 2 years, while in the last year, there were almost 17% of the respondents visiting the dental office. The results concerning oral hygiene habits also

turned out to be very disturbing. Although most of the respondents brushed teeth twice a day, as many as 16.9% that they brushed their teeth only once a day, and 3.5% declared that they did not brush them at all. Statistical differences were in favor of women and residents of large cities, where only 0.9% never brushed their teeth. Individuals with higher education brushed teeth more often than those with basic education. In the accessory category, the subjects most frequently used manual brushes with soft or medium bristles. Sixty-eight percent of the respondents had never used an electric brush, 38% did not use dental floss, and as many as 52% had never used interdental brushes, which help maintain optimal mechanical plaque control in interproximal spaces. Thirty-three percent of the respondents did not use any mouthwash. Due to unlimited availability of a variety of oral hygiene products, selection of the most suitable ones for some patients may be problematic. Meanwhile, supragingival plaque should be removed mechanically by regularly applying a tooth-

brush, optimally twice a day, and cleaning the interdental spaces. Electric brushes with oscillating-rotating motion reduce the plaque by 7–57.9%, gingival inflammation by 17–19.8% and bleeding of gingiva by 85.2% more effectively compared to manual brushes.<sup>9,10</sup> The best results in reduction of plaque and gingivitis are demonstrated by electric toothbrushes with oscillating-rotating-pulsating action (working in a 3D system).<sup>2</sup> Modern toothbrushes are characterized by 8,800 oscillating and 40,000 pulsating movements per minute. Electric toothbrushes do not pose a great threat to hard tissues of teeth and to gingiva, in relation to the occurrence of non-carious lesions and gingival recessions, compared to manual brushes.<sup>11</sup>

In order to remove plaque from interdental spaces, it is recommended to regularly use dental floss or interdental brushes. However, the effectiveness of dental floss in the removal of plaque from interdental spaces may be very low (15–19.4%), depending on the patient's manual skills.<sup>12</sup> Without proper instruction, its use does not reduce the occurrence of caries on interproximal surfaces of teeth.<sup>13</sup> In patients with periodontitis, the use of toothbrushes results in better cleaning of interdental spaces than the use of dental floss alone.<sup>12,14</sup> Vogel et al. showed that electric toothbrushes designed to clean interdental spaces are more effective than manual brushes, but their use is also associated with a higher risk of soft tissue damage, especially the gingival papilla.<sup>14</sup> Therefore, it can be concluded that recommending the use of dental floss should be limited only to those interdental spaces that, due to their width, are not accessible for interdental brushes.<sup>15</sup>

Antiseptics may be helpful in controlling bacterial plaque, especially for individuals who have difficulty maintaining optimal oral hygiene with mechanical devices.<sup>16</sup> The most effective compound used in mouthwash solutions is definitely chlorhexidine, which has anti-plaque (inhibits plaque development) and anti-inflammatory properties.<sup>17,18</sup> It should not be used for more than 2 weeks due to local side effects (discoloration of teeth, fillings, prosthetic restorations, and mucosal membrane, as well as taste disorders and exfoliation of mucosal membrane epithelium). Such antiseptics also include plaque inhibitors that slow the growth of bacterial plaque: triclosan with a copolymer, essential oils, and aminofluorides in the form of toothpastes, gels and rinses. Regular use of mouthwashes containing fluorine compounds in childhood reduces the occurrence of carious lesions in permanent dentition.<sup>19</sup> An effective, as far as plaque control and reduction of gingival inflammation are concerned, but at the same time the least popular antiseptic carrier is an aerosol.<sup>20</sup>

On the basis of our research results, it can be stated that pro-health behaviors of Poles aimed at maintaining oral health are unsatisfactory. This was confirmed by epidemiological studies carried out on individuals aged 65–74 years.<sup>7</sup> As many as 78.3% of subjects regularly visited the dental office at least once a year. The most com-

mon reason for the visit was pain (48.8%). Only 25% of individuals were on regular control visits. A total of 5.7% of respondents did not use a toothbrush every day, 18% brushed their teeth once a day, 50.2% twice a day, and 26% more often than twice a day. Only 17.22% of subjects regularly used dental floss.

Negligence in bacterial plaque control can cause gingivitis, manifested by bleeding while brushing teeth or eating hard foods. It should be remembered that gingival status assessment based on bleeding observed by patients is not reliable. Patients might not notice bleeding every time it occurs, especially if it concerns the posterior dentition or the lingual/palatal side of teeth, or when a slight inflammation of gingiva is present. The best way to verify inflammation is the dichotomous BoP (bleeding on probing) index according to Ainamo and Bay, which assesses the occurrence of gingival bleeding during careful probing of the bottom of the pocket on 4 surfaces of each tooth.<sup>21</sup> The BoP value <10% indicates no inflammation of the gums. In this study, bleeding from gums was reported by 50% of the respondents, including 5% of subjects with bleeding during every tooth brushing. A positive association of gum bleeding with genetic load, and with the use of a manual brush with soft bristles and mouthwash was observed. A soft bristle manual toothbrush may not be effective enough to control bacterial plaque, especially in the case of individuals with lower manual skills. On the other hand, the use of mouthwash as a substitute for tooth brushing also does not guarantee optimal plaque control, which can manifest itself in gingivitis. In the study group, the chance of gingival bleeding during tooth brushing decreased with age, weight, BMI, and nicotine use. The dynamics of inflammation in the oral cavity can diminish with age, especially in the cases of advanced periodontal diseases, which involve tooth extractions. Nicotine use is a risk factor for occurrence and development of periodontitis, but due to the vasoconstriction action of nicotine, clinical symptoms of gingivitis are less pronounced. It is difficult to explain the association observed between BMI and occurrence of gingival bleeding. Scientific studies have shown that the cumulative odds ratio (OR) for obesity and overweight, as a risk factor for periodontitis, was significant and equaled 2.13 (confidence interval – CI: 1.40–3.36;  $p < 0.001$ ).<sup>22</sup> With increased BMI, the risk of periodontitis also rises, and this relationship has a dose-effect nature. Perhaps the results of our study indicate a lower pro-health awareness of overweight individuals, who may overlook symptoms of gingivitis such as bleeding from gingiva. Moreover, these individuals might pay less attention to their oral health and, as a result, brush their teeth less frequently. However, this is actually a very debatable issue.

In long-term observations, hygienic habits that translate into bacterial plaque control may be reflected in the state of dentition and the number of retained teeth. The main cause of tooth loss in adult population is definite-

ly caries. Less frequent causes are periodontal diseases, injuries, and orthodontic or prosthetic indications. Risk factors of early tooth loss, apart from medical ones, also include demographic, socio-economic and behavioral causes. Danish studies showed that regular dental care at school during childhood, the amount of personal income, education, and frequency of visits to the dental office constitute the most important factors affecting the preservation of own teeth.<sup>23</sup> Some of these variables were evaluated in the present study. The number of lost teeth increased with age and the average number of teeth was 27 for the age group of 35–44 years. In the epidemiological study conducted by Górska et al. in 2012, the average number of teeth in this age group amounted to 26.<sup>6</sup> This data does not differ significantly from the average number of teeth in residents of other European Union countries. A similar number of teeth was found among the population of France – 27.1, lower in Germans and Danes – 25.1, and in Hungarians – 19.1.<sup>22,24–26</sup> A high dynamics of tooth loss in Poles is observed between 45 and 65 years of age. Our own questionnaire showed that over the age of 65, the average number of teeth is 13, similarly to the latest Polish epidemiological study.<sup>7</sup> With reference to earlier studies, however, a clear trend of an increase in the average number of teeth in this age group can be observed. In the study by Jodkowska from 2009, the average number of teeth among Poles aged 65–74 years was only 6.6.<sup>27</sup> The current situation is not significantly different compared to other European Union countries. Among Spaniards and the Swiss, the average number of teeth is 14.2 and 17.6, respectively, among Germans – 13.6; however, a lower number of teeth is found in Danes – 12.5 and Hungarians – 9.1.<sup>25,26,28–30</sup> Additionally, in our own study, the number of teeth did not differ significantly depending on sex, but was related to the place of residence. Inhabitants of large cities had a total of 23 teeth and residents of countryside villages – 22 teeth. Interestingly, the lowest number of teeth was observed among residents of medium-sized cities.<sup>19</sup> However, it should be noted that village residents constituted only 12.3% of the respondents and it can be assumed that these results are subject to a considerable error. On the other hand, a clear trend was observed regarding an increase in the number of teeth present in the oral cavity depending on education. The respondents with higher education had on average 25 teeth compared to 13 teeth among respondents with primary education.

## Conclusions

Pro-health behaviors of adult Poles in maintaining optimal oral hygiene are unsatisfactory. Women, young people living in big cities and those with higher education brush their teeth more often than men, older people living in the countryside, who received only primary education. For this purpose, manual brushes with medium and

soft bristles are most commonly used, while additional instruments for interdental plaque control are implemented very rarely. This affects the state of gingiva. Inflammation, manifested by bleeding observed by the patients, occurs in 50% of the respondents. The average number of teeth does not differ significantly from that reported in epidemiological studies and remains associated with education.

## References

1. Socransky SS, Haffajee AD. Dental biofilms: Difficult therapeutic targets. *Periodontol 2000*. 2002;28:12–55.
2. Mielczarek A, Banach J, Górska R. Comparison of effectiveness of manual and electric toothbrushes in elimination of dental plaque and gingivitis reduction. *Dent Med Probl*. 2013;50(4):467–471.
3. Sreenivasan PK, Prasad KVV. Distribution of dental plaque and gingivitis within dental arches. *J Int Med Res*. 2017;45(5):1585–1596.
4. Spivakovskiy S, Keenan A. The effect of anti-plaque agents on gingivitis. *Evid Based Dent*. 2016;17(2):48–49.
5. Claydon NC. Current concepts in toothbrushing and interdental cleaning. *Periodontol 2000*. 2008;48:10–22.
6. Górska R, Pietruska M, Dembowska E, Wysokińska-Miszczuk J, Włosowicz M, Konopka T. Prevalence of periodontal diseases in 35–44 year-olds in the large urban agglomerations [in Polish]. *Dent Med Probl*. 2012;49(1):19–27.
7. Konopka T, Dembowska E, Pietruska M, Dymalski P, Górska R. Periodontal status and selected parameters of oral condition of Poles aged from 65 to 74 years. *Przegl Epidemiol*. 2015;69(3):537–542.
8. The evaluation of oral health and its determinants in Poles aged 35–44 and 65–74. Epidemiological studies carried out in 2013 within the framework of health policy: “The monitoring of oral health of Polish population over the period 2013–2015”, Ministry of Health, 2015.
9. Grender J, Williams K, Walters P, et al. Plaque removal efficacy of oscillating-rotating power toothbrushes: Review of six comparative clinical trials. *Am J Dent*. 2013;26(2):68–74.
10. Robinson PG, Deacon SA, Deery C, et al. Manual versus powered toothbrushing for oral health. *Cochrane Database Syst Rev*. 2005;18(2):CD002281.
11. Dörfer CE, Staehle HJ, Wolff D. Three-year randomized study of manual and power toothbrush effects on pre-existing gingival recession. *J Clin Periodontol*. 2016;43(6):512–519.
12. Blanck M, Mankodi S, Wesley P, Tasket R, Nelson B. Evaluation of the plaque removal efficacy of two commercially available dental floss devices. *J Clin Dent*. 2007;18(1):1–6.
13. Terézhalmy GT, Bartizek RD, Biesbrock AR. Plaque-removal efficacy of four types of dental floss. *J Periodontol*. 2008;79(2):245–250.
14. Vogel M, Sener B, Roos M, Attin T, Schmidlin PR. Interdental cleaning and gingival injury potential of interdental toothbrushes. *Swiss Dent J*. 2014;124(12):1290–1295.
15. Chapple IL, Van der Weijden F, Dörfer CE, et al. Primary prevention of periodontitis: Managing gingivitis. *J Clin Periodontol*. 2015;42(Suppl 16):S71–76.
16. Luís HS, Luís LS, Bernardo M, Santos NR. Randomized controlled trial on mouth rinse and flossing efficacy on interproximal gingivitis and dental plaque. *Int J Dent Hyg*. 2017;16(2):e73–e78.
17. Serrano J, Escribano M, Roldán S, Martín C, Herrera D. Efficacy of adjunctive anti-plaque chemical agents in managing gingivitis: A systematic review and meta-analysis. *J Clin Periodontol*. 2015;42(Suppl 16):S106–138.
18. Reddy R, Palaparthi R, Durvasula S, et al. Gingivitis and plaque prevention using three commercially available dentifrices: A comparative clinical and microbiological randomized control parallel study. *Int J Pharm Investig*. 2017;7(3):111–118.
19. Marinho VC, Chong LY, Worthington HV, Walsh T. Fluoride mouthrinses for preventing dental caries in children and adolescents. *Cochrane Database Syst Rev*. 2016;7:CD002284.
20. Zhang J, Ab Malik N, McGrath C, Lam O. The effect of antiseptic oral sprays on dental plaque and gingival inflammation: A systematic review and meta-analysis. *Int J Dent Hyg*. 2018. doi: 10.1111/idh.12331

21. Ainamo J, Bay I. Problems and proposals for recording gingivitis and plaque. *Int Dent J.* 1975;25(4):229–235.
22. Suvan J, D'Aiuto F, Moles DR, Petrie A, Donos N. Association between overweight/obesity and periodontitis in adults: A systematic review. *Obes Rev.* 2011;12(5):e381–404.
23. Petersen OE, Kjøller M, Christensen LB, Krstrup U. Changing dentate status of adults, use of dental health services, and achievement of National Dental Health Goals in Denmark by the year 2000. *J Public Health Dent.* 2004;64(3):127–135.
24. Hescot P, Bourgeois D, Doury J. Oral health in 35–44-year-old adults in France. *Int Dent J.* 1997;47(2):94–99.
25. Holtfreter B, Kocher T, Hoffmann T, Desvarieux M, Micheelis W. Prevalence of periodontal disease and treatment demands based on a German dental survey (DMS IV). *J Clin Periodontol.* 2010;37(3):211–219.
26. Madléna M, Hermann P, Jáhn M, Fejérdy P. Caries prevalence and tooth loss in Hungarian adult population. *BMC Public Health.* 2008;8:364–364.
27. Jodkowska E. The condition of dentition status of adult Polish citizens in years 1998–2009 [in Polish]. *Przegl Epidemiol.* 2010;64(4):571–576.
28. Zitzmann NU, Staehelin K, Walls AW, Menghini G, Weiger R, Zemp Stutz E. Changes in oral health over a 10-year period in Switzerland. *Eur J Oral Sci.* 2008;116(1):52–59.
29. Krstrup U, Petersen PE. Periodontal conditions in 35–44 and 65–74-year-old adults in Denmark. *Acta Odont Scand.* 2006;64(2):65–73.
30. König J, Holtfreter B, Kocher T. Periodontal health in Europe: Future trends based on treatment needs and the provision of periodontal services – position paper 1. *Eur J Dent Educ.* 2010;14(Suppl 1):4–24.



# Effectiveness of laser irradiation in preventing enamel demineralization during orthodontic treatment: A systematic review

## Skuteczność promieniowania laserowego w zapobieganiu demineralizacji szkliwa podczas leczenia ortodontycznego – systematyczny przegląd piśmiennictwa

Tuqa Rashad Raghis<sup>1,A–D,F</sup>, Ghiath Mahmoud<sup>1,B–F</sup>, Omar Hamadah<sup>1,2,C,E,F</sup>

<sup>1</sup> Department of Orthodontics, Faculty of Dental Medicine, University of Damascus, Syria

<sup>2</sup> Higher Institute for Laser Research and Applications, University of Damascus, Syria

A – research concept and design; B – collection and/or assembly of data; C – data analysis and interpretation;

D – writing the article; E – critical revision of the article; F – final approval of the article

Dental and Medical Problems, ISSN 1644-387X (print), ISSN 2300-9020 (online)

*Dent Med Probl.* 2018;55(3):321–332

### Address for correspondence

Omar Hamadah

E-mail: omar.hamadah@gmail.com

### Funding sources

None declared

### Conflict of interest

None declared

### Acknowledgements

The authors would like to kindly thank Dr. Michaela Goodson for her linguistic assistance.

Received on April 29, 2018

Reviewed on June 14, 2018

Accepted on June 27, 2018

### Abstract

The objective of this study was to investigate the in vivo effectiveness of laser in the prevention of enamel demineralization during orthodontic treatment.

A search of electronic databases (PubMed, ScienceDirect, Google Scholar, Scopus, the Cochrane Central Register of Controlled Trials – CENTRAL, OpenGrey, and ProQuest Dissertations and Theses – PQDT Open from ProQuest) was carried out. In vivo studies, randomized and/or controlled clinical trials regarding the use of laser treatment to prevent enamel demineralization during orthodontic treatment were included. The risk of bias of the studies included was assessed independently by 2 authors according to Cochrane guidelines.

Eight articles were identified, comprising a total of 183 patients. Significant differences were observed in enamel demineralization between laser-irradiated and control groups for all laser types: argon laser, CO<sub>2</sub> laser, neodymium-doped yttrium aluminum garnet (Nd:YAG) laser, and Optodan® laser, except for argon laser application for curing bracket adhesives, where no statistically significant differences were noted.

Laser irradiation may be effective in inhibiting demineralization during orthodontic treatment, but there is a need for further randomized, controlled clinical trials, utilizing different laser systems to determine real clinical efficacy of the technique.

**Key words:** prevention, laser, orthodontics, white spot lesions, demineralization

**Słowa kluczowe:** zapobieganie, laser, ortodoncja, białe plamy próchnicowe, demineralizacja

### DOI

10.17219/dmp/92636

### Copyright

© 2018 by Wrocław Medical University  
and Polish Dental Society

This is an article distributed under the terms of the  
Creative Commons Attribution Non-Commercial License  
(<http://creativecommons.org/licenses/by-nc-nd/4.0/>)

## Introduction

Enamel demineralization or white spot lesion (WSL) development during orthodontic treatment with fixed appliances is a common clinical problem in modern orthodontic practice.<sup>1</sup> Fixed attachments may encourage prolonged plaque accumulation, particularly in patients with poor oral hygiene, compliancy or disability.<sup>2</sup> In addition, a prolonged period of fixed orthodontic treatment increases the risk of WSL formation.<sup>3</sup>

The prevalence of WSLs in patients undergoing orthodontic treatment is about 68.4%, so professional preventive procedures are recommended for fixed orthodontic treatment patients.<sup>3</sup> The responsibility of the orthodontist is to minimize decalcification through education and motivation of the patient to maintain good oral hygiene.<sup>4</sup> Topical fluoride (high-fluoride toothpaste, fluoride mouthwashes, gels and varnishes) is effective in caries prevention and management of WSLs during and after orthodontic treatment.<sup>5</sup>

There is evidence in the literature that laser irradiation modifies the enamel structure, making it more resistant to acid dissolution,<sup>6</sup> so laser application may serve as a preventive measure for WSL formation for orthodontic patients without relying on patient compliancy.

Several types of laser beams have been used to increase enamel resistance to decalcification during orthodontic treatment. These include CO<sub>2</sub>, neodymium-doped yttrium aluminum garnet (Nd:YAG), erbium-doped yttrium aluminum garnet (Er:YAG), erbium, chromium: yttrium-scandium-gallium-garnet (Er, Cr:YSGG), diode, and argon lasers.<sup>7,8</sup>

The effectiveness of different lasers in decreasing the susceptibility of the enamel surface to caries have been investigated mostly by in vitro studies and a handful of in vivo studies,<sup>8,9</sup> but the clinical evidence about laser effectiveness is still unclear. There is only 1 published systematic review investigating the effect of lasers in preventing demineralization during orthodontic treatment; however, this study did not involve all types of laser beams that could be applied for this purpose.<sup>10</sup> Equally, there are no reports about the effective and safe laser parameters for clinical use in managing WSL formation.

The aim of this systematic review is to investigate the in vivo effectiveness of different types of laser in preventing enamel demineralization during orthodontic treatment. A secondary aim is to evaluate, using published reports, the effective and safe laser settings that can be used to manage demineralization during orthodontic treatment.

## Material and methods

### Protocol and registration

This systematic review was conducted following the Preferred Reporting Items for Systematic Reviews and Meta-Analyses (PRISMA) guidelines.<sup>11</sup>

Review questions:

1. Does laser irradiation significantly increase enamel resistance to demineralization during orthodontic treatment?
2. What are the most effective and safest lasers for the prevention of demineralization related to orthodontic treatment?

Table 1. Review questions – PICO study design

Review questions – PICO study design	
Population	<p>Eligibility criteria:</p> <ul style="list-style-type: none"> <li>– healthy patients with permanent teeth, receiving orthodontic treatment with fixed orthodontic appliances (no predetermined restrictions on initial malocclusion or indications for treatment);</li> <li>– patients of any age;</li> <li>– patients of both genders;</li> <li>– patients of any ethnic group.</li> </ul> <p>Exclusion criteria:</p> <ul style="list-style-type: none"> <li>– syndromic patients;</li> <li>– patients with any systemic disease;</li> <li>– patients with teeth with enamel imperfections or restorations</li> </ul>
Intervention	Application of different laser beams on enamel during orthodontic treatment.
Comparison	Formation of WSLs or enamel demineralization – comparison between laser-irradiated enamel and non-manipulated enamel, or with other preventive procedures applied.
Outcome	<p>Primary outcome:</p> <ul style="list-style-type: none"> <li>– formation or no formation of WSLs, assessed by clinical diagnosis or on digital images;</li> <li>– degree of decalcification;</li> <li>– changes in the enamel structure after laser application.</li> </ul>
Study design	<p>Eligibility criteria:</p> <ul style="list-style-type: none"> <li>– in vivo studies (human studies);</li> <li>– RCTs;</li> <li>– CCTs;</li> <li>– no predetermined restrictions on language, year of publication or publication status.</li> </ul> <p>Exclusion criteria:</p> <ul style="list-style-type: none"> <li>– case reports or case series;</li> <li>– editorials, personal opinions, reviews, and technique description articles, without a reported sample;</li> <li>– in vitro studies and animal studies.</li> </ul>

PICO – population, intervention, comparison, and outcome study design; WSL – white spot lesion; RCT – randomized controlled trial; CCT – controlled clinical trial.

These review questions were developed according to the population, intervention, comparison, and outcome (PICO) study design (Table 1).

## Types of publications

This review included all publications, regardless of language, about the clinical application of different laser types to prevent WSLs or enamel demineralization during fixed orthodontic treatment. Personal opinions, editorials, literature reviews, and abstracts were excluded.

Eligibility criteria of the population were:

- healthy patients with permanent teeth, receiving orthodontic treatment with fixed orthodontic appliances;
- patients of any age;
- patients of both genders;
- patients of any ethnic groups.

Exclusion criteria of the population were:

- syndromic patients;
- patients with any systemic disease;
- patients with teeth with enamel imperfections or restorations.

## Information sources

The search strategy incorporated searching electronic databases, supplemented by hand searching. The electronic search was performed in PubMed (National Library of Medicine – NLM, National Center for Biotechnology Information – NCBI), ScienceDirect, Google Scholar, Scopus, the Cochrane Central Register of Controlled Trials (CENTRAL), OpenGrey (to identify the grey literature), and ProQuest Dissertations and Theses (PQDT Open) from ProQuest (to identify dissertations and theses). The references of each relevant study were screened to discover additional relevant publications and to improve the sensitivity of the search. ClinicalTrials.gov and the World Health Organization International Clinical Trials Registry Platform Search Portal (ICTRP) were also screened to evaluate any unpublished studies or current accomplished research work.

Hand searching was carried out in the following journals: “American Journal of Orthodontics and Dentofacial Orthopedics”; “Australasian Orthodontic Journal”; “Caries Research”; “European Journal of Orthodontics”; “Journal of Biomedical Optics”; “Lasers in Medical Science”; “Lasers in Surgery and Medicine”; “Laser Therapy”; “Orthodontics and Craniofacial Research”; “Photomedicine and Laser Surgery”; “Seminars in Orthodontics”; “Angle Orthodontist”; “Journal of Orthodontics”; and “Korean Journal of Orthodontics”.

## Search

PubMed, Scopus, ScienceDirect, Google Scholar, and Cochrane databases were explored through advanced searches. The search was conducted in June 2017, using the following keywords: (laser therapy) OR (laser irradiation) OR (laser application) AND (enamel caries prevention) OR (enamel resistance) OR (enamel decalcification) OR (enamel demineralization) OR (white spot lesions WSLs) OR (enamel dissolution) OR (enamel microhardness) AND (orthodontics) OR (orthodontic treatment) OR (orthodontic brackets) OR (fixed appliances). The full electronic search strategy is presented in Supplementary Material 1.

## Study selection

The obtained articles were independently subjected to clear inclusion and exclusion criteria by 2 authors (TRR and GM).

Inclusion criteria for the studies were:

- in vivo studies (human studies);
- randomized controlled trials (RCTs);
- controlled clinical trials (CCTs).

Exclusion criteria for the studies were:

- case reports or case series;
- editorials, personal opinions, reviews, and technique description articles, without a reported sample;
- in vitro studies and animal studies.

## Sequential search strategy

Firstly, all article titles were screened and the irrelevant articles, reviews, case reports, and in vitro studies were excluded. Then, abstracts of the remaining articles were screened to eliminate studies based on data obtained from abstracts. Finally, the full text of the remaining articles was screened to confirm the acceptability of the articles depending on the inclusion and exclusion criteria.

The authors compared their decisions and resolved differences through discussion, consulting a third author (OH) when consensus could not be reached. The 3<sup>rd</sup> author was an experienced senior reviewer.

## Data extraction

The data was extracted from the studies according to the aims of the systematic review by the same 2 authors (TRR and GM) independently and were arranged in the following fields: general information (name of author and year of publication); study characteristics (study design and treatment comparison); sample description (size, age and sex); laser application (type of laser beam, laser parameters and details of irradiation protocol); and outcomes (primary outcomes, methods of primary outcome measurement, and statistical significance of the reported differences between treated and control groups).

Supplementary Material 1. Literature databases searched with a search strategy (last search on June 30, 2017)

Database	Site	Search strategy	Search builder	Limits	Items	Items involved after excluding irrelevant articles
PubMed	<a href="http://www.ncbi.nlm.nih.gov/pubmed/">http://www.ncbi.nlm.nih.gov/pubmed/</a>	(laser therapy) OR (laser irradiation) OR (laser application) AND (enamel caries prevention) OR (enamel resistance) OR (enamel decalcification) OR (enamel demineralization) OR (white spot lesions WSLs) OR (enamel dissolution) OR (enamel microhardness) AND (orthodontics) OR (orthodontic treatment) OR (orthodontic brackets) OR (fixed appliances)	all fields	–	42,045	106
CENTRAL (Cochrane Library)	<a href="http://www.cochranelibrary.com/">http://www.cochranelibrary.com/</a>	(laser therapy) OR (laser irradiation) OR (laser application) AND (enamel caries prevention) OR (enamel resistance) OR (enamel decalcification) OR (enamel demineralization) OR (white spot lesions WSLs) OR (enamel dissolution) OR (enamel microhardness) AND (orthodontics) OR (orthodontic treatment) OR (orthodontic brackets) OR (fixed appliances)	title, abstract, keywords	trials	8,650	27
ScienceDirect	<a href="https://www.sciencedirect.com/">https://www.sciencedirect.com/</a>	(laser therapy) OR (laser irradiation) OR (laser application) AND (enamel caries prevention) OR (enamel resistance) OR (enamel decalcification) OR (enamel demineralization) OR (white spot lesions WSLs) OR (enamel dissolution) OR (enamel microhardness) AND (orthodontics) OR (orthodontic treatment) OR (orthodontic brackets) OR (fixed appliances)	title, abstract, keywords	–	7	6
Google Scholar	<a href="https://scholar.google.com/">https://scholar.google.com/</a>	(laser therapy) OR (laser irradiation) OR (laser application) AND (enamel caries prevention) OR (enamel resistance) OR (enamel decalcification) OR (enamel demineralization) OR (white spot lesions WSLs) OR (enamel dissolution) OR (enamel microhardness) AND (orthodontics) OR (orthodontic treatment) OR (orthodontic brackets) OR (fixed appliances)	–	–	1,520	53
Scopus	<a href="http://www.scopus.com/">http://www.scopus.com/</a>	(laser therapy) OR (laser irradiation) OR (laser application) AND (enamel caries prevention) OR (enamel resistance) OR (enamel decalcification) OR (enamel demineralization) OR (white spot lesions WSLs) OR (enamel dissolution) OR (enamel microhardness) AND (orthodontics) OR (orthodontic treatment) OR (orthodontic brackets) OR (fixed appliances)	title, abstract, keywords	–	118	22
OpenGrey	<a href="http://www.opengrey.eu/">http://www.opengrey.eu/</a>	(laser therapy) OR (laser irradiation) OR (laser application) AND (enamel caries prevention) OR (enamel resistance) OR (enamel decalcification) OR (enamel demineralization) OR (white spot lesions WSLs) OR (enamel dissolution) OR (enamel microhardness) AND (orthodontics) OR (orthodontic treatment) OR (orthodontic brackets) OR (fixed appliances)	–	orthodontics	416	5
PQDT Open (from ProQuest)	<a href="http://pqdtopen.proquest.com/">http://pqdtopen.proquest.com/</a>	(laser therapy) OR (laser irradiation) OR (laser application) AND (enamel caries prevention) OR (enamel resistance) OR (enamel decalcification) OR (enamel demineralization) OR (white spot lesions WSLs) OR (enamel dissolution) OR (enamel microhardness) AND (orthodontics) OR (orthodontic treatment) OR (orthodontic brackets) OR (fixed appliances)	–	–	0	0
ClinicalTrials.gov	<a href="https://clinicaltrials.gov/">https://clinicaltrials.gov/</a>	Condition or disease: (enamel caries prevention) OR (enamel resistance) OR (enamel decalcification) OR (enamel demineralization) OR (white spot lesions WSLs) OR (enamel dissolution) OR (enamel microhardness) Other terms: (laser therapy) OR (laser irradiation) OR (laser application) AND (orthodontics) OR (orthodontic treatment) OR (orthodontic brackets) OR (fixed appliances)	all	–	8	1
WHO ICTRP	<a href="http://apps.who.int/trialsearch/">http://apps.who.int/trialsearch/</a>	(laser therapy) OR (laser irradiation) OR (laser application) AND (enamel caries prevention) OR (enamel resistance) OR (enamel decalcification) OR (enamel demineralization) OR (white spot lesions WSLs) OR (enamel dissolution) OR (enamel microhardness) AND (orthodontics) OR (orthodontic treatment) OR (orthodontic brackets) OR (fixed appliances)	all	–	776	2
Overall					53,540	222*

\* There were 53,540 items identified from electronic databases. 473 items were added through hand searching and references screening. After excluding irrelevant articles, there were 222 items involved from electronic search and 150 items from hand searching and references screening. Then, after filtering for duplication, there were 304 items left (155 items from electronic databases and 149 items from hand searching and references screening).

## Assessment of methodological quality

The risk of bias of the included trials was also assessed independently by the same 2 authors (TRR and GM), using the recommended approach for assessing the risk of bias in studies included in Cochrane reviews.<sup>12</sup> The studies were evaluated in the following fields as low, high or unclear risk of bias: sequence generation (selection bias); allocation concealment (selection bias); blinding of participants and personnel (performance bias); blinding of outcome assessors (detection bias); incomplete outcome data addressed (attrition bias); selective outcome reporting (reporting bias); and other bias types. The overall risk of bias of the included trials was assessed according to the following criteria: low risk of bias – if all fields were assessed as low risk of bias; unclear risk of bias – if at least 1 field was assessed as unclear risk of bias; and high risk of bias – if at least 1 field was assessed as high risk of bias.

## Synthesis of results and statistical analysis

Relevant data related to the previously stated variables was collected and organized into tables. No meta-analyses could be performed due to the heterogeneity of study designs, treatment protocols and outcomes.

## Results

### Study selection

Article review and data extraction was performed according to the PRISMA flow diagram. The initial search identified a total of 54,013 references. Following the screening of the article titles, 304 potentially relevant articles were identified. Independent screening of the abstracts resulted in the selection of 23 publications and 1 protocol (for ongoing study) for possible inclusion. The inclusion and exclusion criteria were applied to the 23 full-text articles. Finally, 8 articles that met the pre-defined criteria were included in the current systematic review. The PRISMA flow chart (Fig. 1) illustrates the search methodology and results.

### Exclusion of studies

The reasons for excluding studies after full-text assessment were as follows: use of non-human enamel ( $n = 1$ ), in vitro studies ( $n = 4$ ), the clinical aspect not applied through orthodontic treatment ( $n = 7$ ), studies on primary teeth ( $n = 1$ ), full text non-available ( $n = 2$ ). The excluded studies, together with the reasons of excluding, are outlined in Supplementary Material 2.

## Quality assessment

The quality assessment of the included studies revealed unclear risk of bias (for 1 or more key domains) in the 8 studies included. Blinding of participants and blinding during outcome assessment were the most problematic fields (unclear risk of bias in 87.5% and 75% of studies, respectively). The overall risk of bias for the included studies is summarized in Fig. 2 and 3.

## Study characteristics

The studies were compared regarding the sample size, study design, type and parameters of the laser applied, and the main outcomes. The 8 articles were published between 2000 and 2015. They involved 183 patients, and the main inclusion criterion was healthy patients in need of orthodontic treatment without caries, demineralization or restorations on the facial surfaces of teeth, except for the trial by Harazaki et al., which included orthodontic patients with early demineralization.<sup>13</sup> Intervention in all trials was the application of different laser types; 4 studies applied an argon laser, 2 studies applied a CO<sub>2</sub> laser, 1 study applied an Nd:YAG laser, and 1 study applied an Optodan<sup>®</sup> laser. The characteristics of the 8 studies are summarized in Table 2.

## Results of individual studies

Four clinical studies applied an argon laser<sup>14–17</sup> and 3 of them reported a significant reduction in the lesion depth, measured on microphotographs of the polarized light microscopy, for the argon laser-irradiated groups of teeth compared to the control groups ( $p \leq 0.05$ ).<sup>14–16</sup> One study did not find a significant effect of argon laser curing on enamel WSL formation, evaluated on the basis of photographs, in the laser group compared to the control group ( $p \geq 0.05$ ).<sup>17</sup>

Two studies applied a CO<sub>2</sub> laser to enamel around orthodontic brackets and reported that CO<sub>2</sub> laser irradiation produced marked demineralization inhibition in short and medium follow-up terms, as it led to significantly higher enamel microhardness compared to the control non-irradiated enamel ( $p \leq 0.04$ ).<sup>18,19</sup>

One clinical study applied an Nd:YAG laser to enamel with WSLs and showed that it was effective in inhibiting the development of dental caries, as the increase of the WSL area was significantly lower compared to the control group ( $p \leq 0.05$ ).<sup>13</sup>

One clinical trial used an Optodan low-intensity laser around orthodontic brackets and reported that the growth index in dental and surface caries intensity was significantly lower in the laser therapy group than in the control group ( $p \leq 0.001$ ).<sup>20</sup> The results of the studies included are summarized in Table 3.

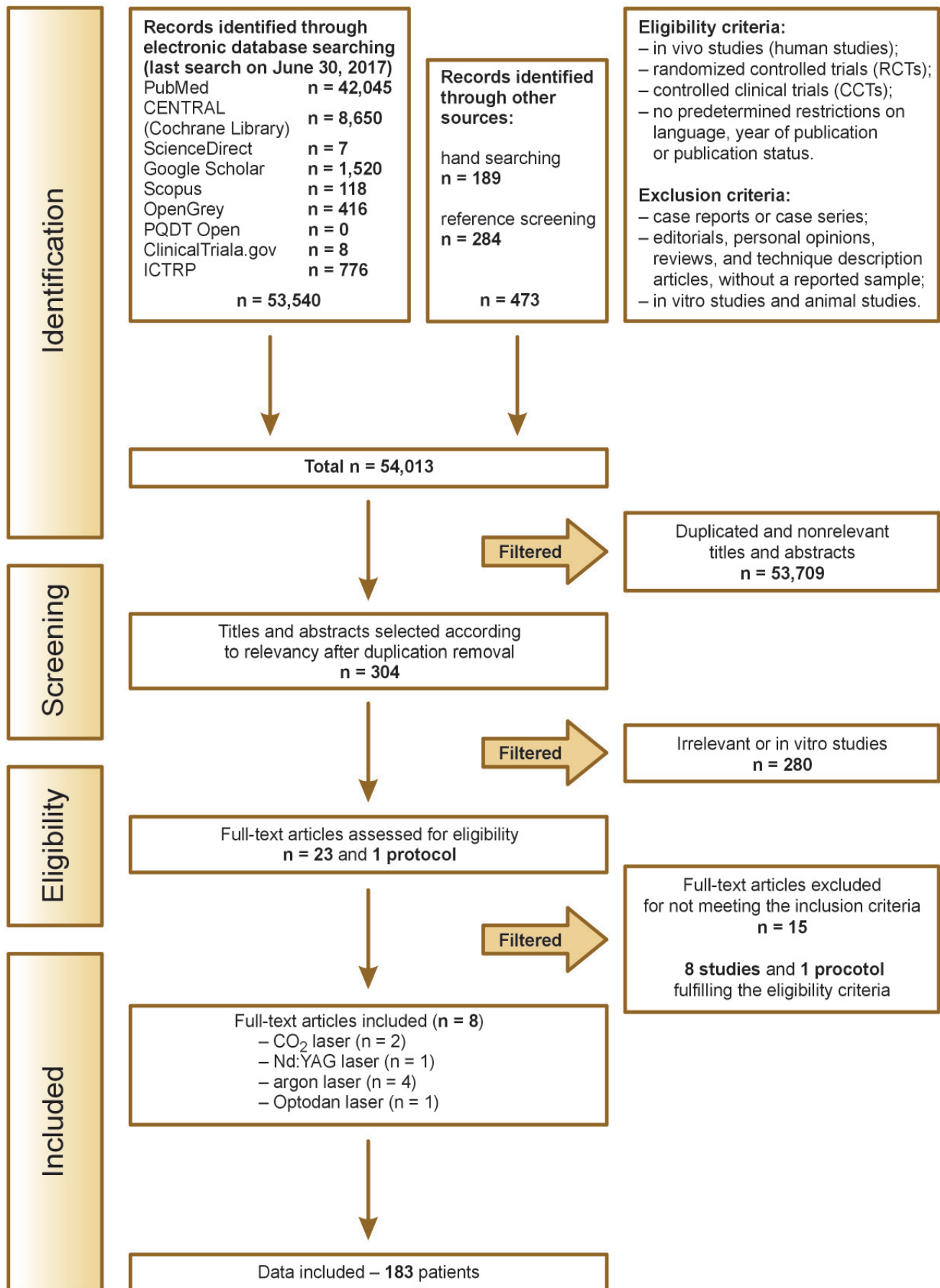


Fig. 1. PRISMA flow diagram illustrating the literature search protocol  
PRISMA – Preferred Reporting Items for Systematic Reviews and Meta-Analyses.

Supplementary Material 2. Studies excluded after full text reading with the reasons of excluding

Study	Reason of excluding
Souza-Gabriel AE, Turssi CP, Colucci V, Tenuta LM, Serra MC, Corona SA. In situ study of the anticariogenic potential of fluoride varnish combined with CO <sub>2</sub> laser on enamel. <i>Arch Oral Biol.</i> 2015;60(6):804–810.	non-human enamel
Stangler LP, Romano FL, Shirozaki MU, et al. Microhardness of enamel adjacent to orthodontic brackets after CO <sub>2</sub> laser irradiation and fluoride application. <i>Braz Dent J.</i> 2013;24(5):508–512.	in vitro study
Seino PY, Freitas PM, Marques MM, de Souza Almeida FC, Botta SB, Moreira MS. Influence of CO <sub>2</sub> (10.6 μm) and Nd:YAG laser irradiation on the prevention of enamel caries around orthodontic brackets. <i>Lasers Med Sci.</i> 2015;30(2):611–616.	in vitro study
Kantorowitz Z, Featherstone JD, Fried D. Caries prevention by CO <sub>2</sub> laser treatment: Dependency on the number of pulses used. <i>J Am Dent Assoc.</i> 1998;129(5):585–591.	in vitro study
Lara-Carrilloa E, Doroteo-Chimalb C, Lopez-Gonzalez S, et al. Remineralization effect of low-level laser and amorphous sodium–calcium–phosphosilicate paste in teeth with fixed orthodontic appliances. <i>Tanta Dental Journal.</i> 2016;13(1):55–62.	in vitro study
ZeZell DM, Boari HGD, Ana PA, Eduardo Cde P, Powell GL. Nd:YAG laser in caries prevention: A clinical trial. <i>Lasers Surg Med.</i> 2009;41(1):31–35.	clinical study, but not applied during orthodontic treatment
Correa-Afonso AM, Pécora JD, Palma-Dibb RG. Influence of laser irradiation on pits and fissures: An in situ study. <i>Photomed Laser Surg.</i> 2013;31(2):82–89.	clinical study, but not applied during orthodontic treatment
Nammour S, Demortier G, Florio P, et al. Increase of enamel fluoride retention by low fluence argon laser in vivo. <i>Lasers Surg Med.</i> 2003;33(4):260–263.	clinical study, but not applied during orthodontic treatment
Nammour S, Rocca JP, Pireaux JJ, Powell G, Morciaux Y, Demortier G. Increase of enamel fluoride retention by low fluence argon laser beam: A 6-month follow-up study in vivo. <i>Lasers Surg Med.</i> 2005;36(3):220–224.	clinical study, but not applied during orthodontic treatment
Apel C, Birker L, Meister J, Weiss C, Gutknecht N. The caries-preventive potential of subablative Er:YAG and Er:YSGG laser radiation in an intraoral model: A pilot study. <i>Photomed Laser Surg.</i> 2004;22(4):312–317.	clinical study, but not applied during orthodontic treatment
Korytnicki D, Mayer MP, Daronch M, Singer Jda M, Grande RH. Effects of Nd:YAG laser on enamel microhardness and dental plaque composition: An in situ study. <i>Photomed Laser Surg.</i> 2006;24(1):59–63.	clinical study, but not applied during orthodontic treatment
Rechmann P, Charland DA, Rechmann BM, Le CQ, Featherstone JD. In vivo occlusal caries prevention by pulsed CO <sub>2</sub> laser and fluoride varnish treatment: A clinical pilot study. <i>Lasers Surg Med.</i> 2013;45(5):302–310.	clinical study, but not applied during orthodontic treatment
Rauci-Neto W, de Castro-Rauci LM, Lepri CP, Faraoni-Romano JJ, Gomes da Silva JM, Palma-Dibb RG. Nd:YAG laser in occlusal caries prevention of primary teeth: A randomized clinical trial. <i>Lasers Med Sci.</i> 2015;30(2):761–768.	study on primary teeth
Jacobson A. The effect of argon laser irradiation on reducing enamel decalcification during orthodontic treatment: An in vitro and in vivo study. <i>Am J Orthod Dentofacial Orthop.</i> 2006;129(1):82.	full text non-available
Rodrigues L, Parisotto T, Steiner-Oliveira C, Azevedo L, Tabchoury C. Effect of CO <sub>2</sub> laser and fluoride dentifrice on demineralization around orthodontic brackets: An in situ study. <i>Lasers Surg Med.</i> 2014;46:57.	full text non-available

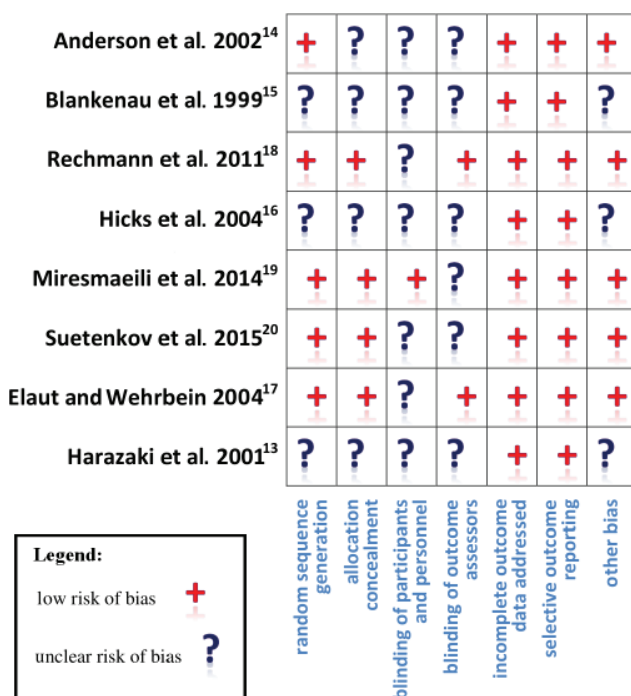


Fig. 2. Summary of the risk of bias for the studies included

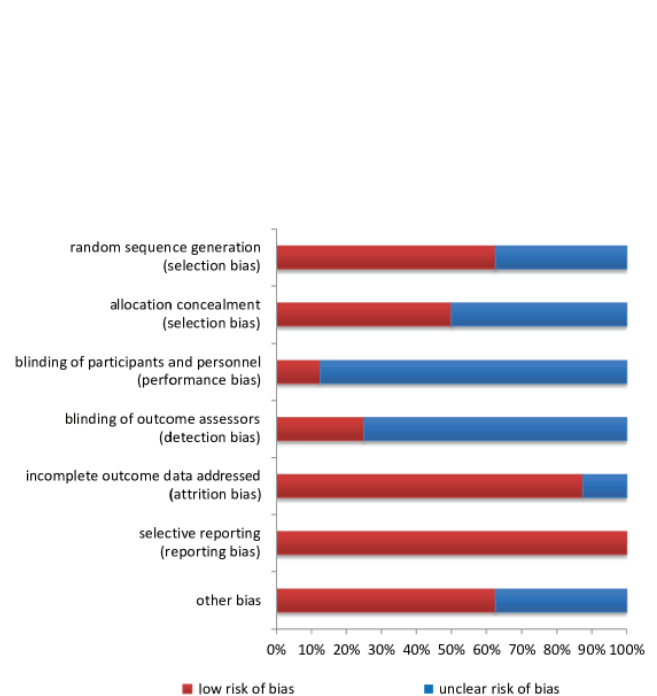


Fig. 3. Overall risk of bias score for each field

Table 2. Characteristics of the trials included

Study	Methods		Participants	Intervention		Follow-up time	Primary outcomes	Methods of measurement of primary outcomes	
	study design	treatment comparison		type of laser beam	laser parameters				details of irradiation protocol
Anderson et al. 2002 <sup>14</sup>	RCT	amount of decalcification in the control group and the argon laser-irradiated groups of teeth (non-pumiced-non-etched group, pumiced group and etched group)	9 patients scheduled for orthodontic treatment with the extraction of 4 premolars; 36 premolars allocated in 4 groups (inclusion criteria: teeth without enamel defects or decalcification)	argon laser	– beam: 325 mW; – time: 60 s; – fluence (energy density): 100 J/cm <sup>2</sup> ; – beam diameter: 5 mm; irradiated through a wand handled at a distance of about 3 mm from the facial surface of the tooth	in 3 lased groups, the laser was applied alone or after pumicing or after pumicing and etching; then modified orthodontic bands with pockets to plaque accumulation were fitted on the premolars	5 weeks; then the teeth were extracted	lesion depth measurement [μm]; lesion area measurement [μm <sup>2</sup> ]	polarized light microscopy – digital microscope images were examined and measured
Blankenau et al. 1999 <sup>15</sup>	clinical pilot study	demineralization of enamel in the laser-irradiated and control teeth	4 patients needing orthodontic treatment with bilateral premolar extraction; 4 pairs of premolars from each participant (1 experimental and 3 control)	argon laser	– beam: 250 mW; – time: 10 s; – fluence: 12 J/cm <sup>2</sup> ; – beam diameter: 5 mm	after experimental teeth irradiation, modified orthodontic bands were fitted on the lased and control teeth	5 weeks; then the teeth were extracted	lesion depth	polarized light microscopy
Elaut and Wehrbein 2004 <sup>17</sup>	RCT (SP)	bracket bonding failure and enamel decalcification in argon laser-cured and conventional light-cured bracket adhesives through orthodontic treatment	45 patients (28 girls and 17 boys), average age: 12 years 11 months, 742 teeth; in each patient, teeth with odd numbers received argon laser curing and teeth with even numbers had conventional light curing of bracket adhesives; the maxillary anterior teeth (212) were evaluated for decalcification (inclusion criteria: patients with fully erupted and restoration-free contralateral pairs of teeth)	argon laser	– beam: 250 mW (continuous mode) – time: 5 s from the incisal side and 5 s from the gingival side; – fluence: 12 J/cm <sup>2</sup> ; – beam diameter: 5 mm	thermoformed plastic/aluminium foil was used to cover the control teeth during argon laser curing	14 months for enamel decalcification (after removing brackets from the maxillary anterior teeth), 12 months for plaque accumulation; the bonding failure rate was evaluated for 4–5 weeks after bonding	absence or degree of WSLs on enamel on the facial surfaces of maxillary anterior teeth; plaque accumulation on the maxillary anterior teeth; the bonding failure rate during the study period	enamel decalcification and plaque accumulation were evaluated through comparing digital images before and after the study period by a team of 7 examiners
Harazaki et al. 2001 <sup>13</sup>	clinical trial	increase in WSLs in the laser-irradiated and the control patients; enamel changes in the irradiated and non-manipulated parts of enamel of the premolar	in vivo part of the study: 10 patients undergoing orthodontic treatment, with enamel WSLs on their teeth, the other 10 patients were a control group; the focus was on maxillary incisors in vitro part of the study: laser irradiation was applied to 1 extracted premolar	Nd:YAG laser	– pulse width: 0.3 ms; – pulse energy: 0.75 J; – power: 2 × 10 W; – repeated 20 pps; – time: 5 s; – fluence: 40 J/cm <sup>2</sup>	in vivo study: the experimental group of 10 patients was administered a black liquid agent, then it was irradiated with laser, and finally the APF gel was applied in vitro study: one part of the extracted premolar was painted with a black liquid, and then irradiated with laser, while the other part of the premolar was used as a control	1 year	increase in the area of WSLs after 1 year in the experimental and control groups; enamel surface changes in the irradiated and control parts of the extracted premolar	WSLs were traced by taking photographs and with tracing paper, and the total WSL area was calculated before laser irradiation and after 1 year; enamel surface changes were observed by SEM
Hicks et al. 2004 <sup>16</sup>	clinical pilot study	lesion depth in argon laser irradiated-teeth in the argon and fluoride group and the control (non-treatment) group	5 patients (3 females, 2 males), age: 19–28 years, requiring orthodontic treatment with tooth extraction (14 teeth); the teeth were caries-free on the buccal surfaces	argon laser	– beam: 250 mW; – time: 10 s; – fluence: 12 J/cm <sup>2</sup>	the teeth were assigned in 3 groups: argon laser, topical fluoride followed by argon laser irradiation, and no treatment (control), then modified orthodontic bands with plaque retentive slots were placed on the teeth	5 weeks; then the teeth were extracted	lesion depth in the 3 groups	polarised light microscopy
Miresmaeili et al. 2014 <sup>19</sup>	RCT (SP)	enamel surface microhardness in the treated and control premolars	16 patients (11 females, 5 males) scheduled for the extraction of at least 2 premolars. (1 first or second premolar treated with laser – 16 teeth, the premolar from the other side in the same patient served as a control – 16 teeth) (inclusion criteria: age <25 years, complete eruption of teeth, no lesions on the enamel surfaces, moderate to good oral hygiene; exclusion criteria: patients with enamel lesions or cracks on the buccal surfaces)	CO <sub>2</sub> laser	– wave length: 10.6 μm; – pulse duration: 3 s; – pulse repetition rate: 5 Hz; – beam diameter: 0.2 mm; – power: 0.7 W	the experimental teeth were irradiated with laser and the control premolars were exposed to non-therapeutic light; then orthodontic brackets were attached to both premolars and the T-loop was engaged to the brackets to increase plaque accumulation	at least 2 months after laser irradiation, then the teeth were extracted (1 tooth from each group was extracted after 1 week of laser irradiation for the SEM evaluation)	enamel surface microhardness around orthodontic brackets; enamel surface changes after laser therapy	Vickers diamond microhardness testing machine was used to evaluate enamel surface microhardness; SEM was used to observe enamel surface changes
Rechmann et al. 2011 <sup>18</sup>	RCT (PG)	enamel demineralization around orthodontic brackets in the laser-irradiated area and other area in the same tooth as a control	24 patients (13 females, 11 males), average age: 14.9 ± 2.2 years, randomly assigned to 4-week (average age: 14.6 ± 2.3 years) and 12-week (average age: 15.2 ± 2.1 years) study arms (inclusion criteria: healthy patients, aged 12–18 years, scheduled to premolar extraction for orthodontic reasons, teeth without caries or restorations on the facial surface; exclusion criteria: systematic diseases, medication affecting oral flora or salivary flow, fluoride treatment in the last 3 months)	CO <sub>2</sub> laser	– wave length: 9.6 μm; – pulse duration: 20 μs; – pulse repetition rate: 20 Hz; – beam diameter: 1,100 μm; – fluence per pulse: 3.3–4.4 J/cm <sup>2</sup> ; irradiated through a straight laser handpiece	the laser beam was applied on enamel, cervical to the bracket of the premolar on one side of an imaginary line, perpendicular to the bracket slot, while the other side of the line in the same tooth served as a control; each spot of the testing area was irradiated with 20 pulses and laser irradiation was applied only once	4 weeks for one group (12 patients) and 12 weeks for the other group (12 patients); then the teeth were extracted	overall relative mineral loss in the 4-week and 12-week arms in the irradiated and control enamel	cross-sectional microhardness testing
Suetenkov et al. 2015 <sup>20</sup>	RCT	dental caries and oral hygiene in the group with traditional preventive measures and the group with laser therapy and traditional preventive measures	60 patients (20 girls, 40 boys), age: 12–13 years, divided into 2 groups (30 patients in each group)	Optodan (low-intensity) laser	– wave length: 0.98–0.85 nm; – power: 0.5–1.0 W; – pulse repetition rate: 2000 Hz; – time: 2 min for each segment	the irradiated area included 2 segments (upper and lower teeth alignments); irradiation was applied after professional oral hygiene measures were taken, and there were 4 courses per year, every 3 months	1 year (after orthodontic treatment completion and removing orthodontic brackets)	oral hygiene and caries intensity before and after orthodontic treatment in both groups	visual examination to determine OHI-S, DMFT index and DMFS index before and after the treatment for both groups

APF – acidulated phosphate fluoride; DMFT – count of Decayed, Missing and Filled Teeth; DMFS – count of Decayed, Missing and Filled tooth Surfaces; Nd:YAG – neodymium-doped yttrium aluminum garnet; OHI-S – simplified oral hygiene index; PG – parallel groups; pps – pulse per second; RCT – randomized controlled trial; SEM – scanning electron microscopy; SP – split-mouth design; WSL – white spot lesion.



Table 2. Characteristics of the trials included

Study	Methods		Participants	Intervention		Follow-up time	Primary outcomes	Methods of measurement of primary outcomes	
	study design	treatment comparison		type of laser beam	laser parameters				details of irradiation protocol
Anderson et al. 2002 <sup>14</sup>	RCT	amount of decalcification in the control group and the argon laser-irradiated groups of teeth (non-pumiced-non-etched group, pumiced group and etched group)	9 patients scheduled for orthodontic treatment with the extraction of 4 premolars; 36 premolars allocated in 4 groups (inclusion criteria: teeth without enamel defects or decalcification)	argon laser	– beam: 325 mW; – time: 60 s; – fluence (energy density): 100 J/cm <sup>2</sup> ; – beam diameter: 5 mm; irradiated through a wand handled at a distance of about 3 mm from the facial surface of the tooth	in 3 lased groups, the laser was applied alone or after pumicing or after pumicing and etching; then modified orthodontic bands with pockets to plaque accumulation were fitted on the premolars	5 weeks; then the teeth were extracted	lesion depth measurement [μm]; lesion area measurement [μm <sup>2</sup> ]	polarized light microscopy – digital microscope images were examined and measured
Blankenau et al. 1999 <sup>15</sup>	clinical pilot study	demineralization of enamel in the laser-irradiated and control teeth	4 patients needing orthodontic treatment with bilateral premolar extraction; 4 pairs of premolars from each participant (1 experimental and 3 control)	argon laser	– beam: 250 mW; – time: 10 s; – fluence: 12 J/cm <sup>2</sup> ; – beam diameter: 5 mm	after experimental teeth irradiation, modified orthodontic bands were fitted on the lased and control teeth	5 weeks; then the teeth were extracted	lesion depth	polarized light microscopy
Elaut and Wehrbein 2004 <sup>17</sup>	RCT (SP)	bracket bonding failure and enamel decalcification in argon laser-cured and conventional light-cured bracket adhesives through orthodontic treatment	45 patients (28 girls and 17 boys), average age: 12 years 11 months, 742 teeth; in each patient, teeth with odd numbers received argon laser curing and teeth with even numbers had conventional light curing of bracket adhesives; the maxillary anterior teeth (212) were evaluated for decalcification (inclusion criteria: patients with fully erupted and restoration-free contralateral pairs of teeth)	argon laser	– beam: 250 mW (continuous mode) – time: 5 s from the incisal side and 5 s from the gingival side; – fluence: 12 J/cm <sup>2</sup> ; – beam diameter: 5 mm	thermoformed plastic/aluminium foil was used to cover the control teeth during argon laser curing	14 months for enamel decalcification (after removing brackets from the maxillary anterior teeth), 12 months for plaque accumulation; the bonding failure rate was evaluated for 4–5 weeks after bonding	absence or degree of WSLs on enamel on the facial surfaces of maxillary anterior teeth; plaque accumulation on the maxillary anterior teeth; the bonding failure rate during the study period	enamel decalcification and plaque accumulation were evaluated through comparing digital images before and after the study period by a team of 7 examiners
Harazaki et al. 2001 <sup>13</sup>	clinical trial	increase in WSLs in the laser-irradiated and the control patients; enamel changes in the irradiated and non-manipulated parts of enamel of the premolar	in vivo part of the study: 10 patients undergoing orthodontic treatment, with enamel WSLs on their teeth, the other 10 patients were a control group; the focus was on maxillary incisors in vitro part of the study: laser irradiation was applied to 1 extracted premolar	Nd:YAG laser	– pulse width: 0.3 ms; – pulse energy: 0.75 J; – power: 2 × 10 W; – repeated 20 pps; – time: 5 s; – fluence: 40 J/cm <sup>2</sup>	in vivo study: the experimental group of 10 patients was administered a black liquid agent, then it was irradiated with laser, and finally the APF gel was applied in vitro study: one part of the extracted premolar was painted with a black liquid, and then irradiated with laser, while the other part of the premolar was used as a control	1 year	increase in the area of WSLs after 1 year in the experimental and control groups; enamel surface changes in the irradiated and control parts of the extracted premolar	WSLs were traced by taking photographs and with tracing paper, and the total WSL area was calculated before laser irradiation and after 1 year; enamel surface changes were observed by SEM
Hicks et al. 2004 <sup>16</sup>	clinical pilot study	lesion depth in argon laser irradiated-teeth in the argon and fluoride group and the control (non-treatment) group	5 patients (3 females, 2 males), age: 19–28 years, requiring orthodontic treatment with tooth extraction (14 teeth); the teeth were caries-free on the buccal surfaces	argon laser	– beam: 250 mW; – time: 10 s; – fluence: 12 J/cm <sup>2</sup>	the teeth were assigned in 3 groups: argon laser, topical fluoride followed by argon laser irradiation, and no treatment (control), then modified orthodontic bands with plaque retentive slots were placed on the teeth	5 weeks; then the teeth were extracted	lesion depth in the 3 groups	polarised light microscopy
Miresmaeili et al. 2014 <sup>19</sup>	RCT (SP)	enamel surface microhardness in the treated and control premolars	16 patients (11 females, 5 males) scheduled for the extraction of at least 2 premolars. (1 first or second premolar treated with laser – 16 teeth, the premolar from the other side in the same patient served as a control – 16 teeth) (inclusion criteria: age <25 years, complete eruption of teeth, no lesions on the enamel surfaces, moderate to good oral hygiene; exclusion criteria: patients with enamel lesions or cracks on the buccal surfaces)	CO <sub>2</sub> laser	– wave length: 10.6 μm; – pulse duration: 3 s; – pulse repetition rate: 5 Hz; – beam diameter: 0.2 mm; – power: 0.7 W	the experimental teeth were irradiated with laser and the control premolars were exposed to non-therapeutic light; then orthodontic brackets were attached to both premolars and the T-loop was engaged to the brackets to increase plaque accumulation	at least 2 months after laser irradiation, then the teeth were extracted (1 tooth from each group was extracted after 1 week of laser irradiation for the SEM evaluation)	enamel surface microhardness around orthodontic brackets; enamel surface changes after laser therapy	Vickers diamond microhardness testing machine was used to evaluate enamel surface microhardness; SEM was used to observe enamel surface changes
Rechmann et al. 2011 <sup>18</sup>	RCT (PG)	enamel demineralization around orthodontic brackets in the laser-irradiated area and other area in the same tooth as a control	24 patients (13 females, 11 males), average age: 14.9 ± 2.2 years, randomly assigned to 4-week (average age: 14.6 ± 2.3 years) and 12-week (average age: 15.2 ± 2.1 years) study arms (inclusion criteria: healthy patients, aged 12–18 years, scheduled to premolar extraction for orthodontic reasons, teeth without caries or restorations on the facial surface; exclusion criteria: systematic diseases, medication affecting oral flora or salivary flow, fluoride treatment in the last 3 months)	CO <sub>2</sub> laser	– wave length: 9.6 μm; – pulse duration: 20 μs; – pulse repetition rate: 20 Hz; – beam diameter: 1,100 μm; – fluence per pulse: 3.3–4.4 J/cm <sup>2</sup> ; irradiated through a straight laser handpiece	the laser beam was applied on enamel, cervical to the bracket of the premolar on one side of an imaginary line, perpendicular to the bracket slot, while the other side of the line in the same tooth served as a control; each spot of the testing area was irradiated with 20 pulses and laser irradiation was applied only once	4 weeks for one group (12 patients) and 12 weeks for the other group (12 patients); then the teeth were extracted	overall relative mineral loss in the 4-week and 12-week arms in the irradiated and control enamel	cross-sectional microhardness testing
Suetenkov et al. 2015 <sup>20</sup>	RCT	dental caries and oral hygiene in the group with traditional preventive measures and the group with laser therapy and traditional preventive measures	60 patients (20 girls, 40 boys), age: 12–13 years, divided into 2 groups (30 patients in each group)	Optodan (low-intensity) laser	– wave length: 0.98–0.85 nm; – power: 0.5–1.0 W; – pulse repetition rate: 2000 Hz; – time: 2 min for each segment	the irradiated area included 2 segments (upper and lower teeth alignments); irradiation was applied after professional oral hygiene measures were taken, and there were 4 courses per year, every 3 months	1 year (after orthodontic treatment completion and removing orthodontic brackets)	oral hygiene and caries intensity before and after orthodontic treatment in both groups	visual examination to determine OHI-S, DMFT index and DMFS index before and after the treatment for both groups

APF – acidulated phosphate fluoride; DMFT – count of Decayed, Missing and Filled Teeth; DMFS – count of Decayed, Missing and Filled tooth Surfaces; Nd:YAG – neodymium-doped yttrium aluminum garnet; OHI-S – simplified oral hygiene index; PG – parallel groups; pps – pulse per second; RCT – randomized controlled trial; SEM – scanning electron microscopy; SP – split-mouth design; WSL – white spot lesion.

Table 3. Summary of the results of the studies included

Study	Sample size of each group	Outcome	Mean	Standard deviation (SD)	p-value	Results
Anderson et al. 2002 <sup>14</sup>	36 teeth in 4 groups (9 per group)	lesion depth in PLM	G1 (ctr): 15.69 µm G2 (pumice+laser): 6.45 µm G3 (pumice+etch+laser): 1.71 µm G4 (laser only): 1.34 µm	G1 (ctr): 9.30 G2 (pumice+laser): 8.70 G3 (pumice+etch+laser): 4.80 G4 (laser only): 3.80	<0.05	reduction in lesion depth was significant as compared to G1: G2: 58.9% G3: 89.1% G4: 91.6%
Blankenau et al. 1999 <sup>15</sup>	4 patients 4 pairs of teeth (each patient 1 ctr and 1 exp tooth)	lesion depth in PLM	pair 1 – ctr: 17,959 nm/exp: 11,976 nm pair 2 – ctr: 313,622 nm/exp: 213,445 nm pair 3 – ctr: 178,528 nm/exp: 128,218 nm pair 4 – ctr: 154,163 nm/exp: 118,004 nm			decrease in lesion depth in the lased tooth: pair 1: 33% pair 2: 31.9% pair 3: 28.1% pair 4: 23.4%
Elaut and Wehrbein 2004 <sup>17</sup>	45 patients 742 teeth 212 teeth evaluated for decalcification (106 with traditional curing + 106 with argon curing)	comparison of the incidence of decalcification before and after the treatment plaque accumulation	ctr group: 85/106 teeth (54%) showed more decalcification at the end of the treatment exp group: 62/106 teeth (58.5%) showed more decalcification  plaque accumulation scores: ctr group: 2.34 exp group: 2.39	plaque accumulation scores: ctr group: 0.86 exp group: 9.81	>0.05	differences in decalcification increase were not statistically significant  there were no significant differences in the plaque accumulation scores between the 2 groups
Harazaki et al. 2001 <sup>13</sup>	10 patients in each of the 2 groups	increase in the WSL area in the 6 maxillary anterior teeth	ctr group: 286.84 mm <sup>2</sup> exp group: 140.76 mm <sup>2</sup>	ctr group: 209.37 exp group: 38.05	<0.05	differences in the increase of the WSL areas between the laser-irradiated and control groups were significant
Hicks et al. 2004 <sup>16</sup>	5 patients 14 teeth, assigned in 3 groups	lesion depth in PLM	G1 (ctr): 261 µm G2 (argon): 147 µm G3 (fluoride+argon): 99 µm	G1 (ctr): 24 G2 (argon): 18 G3 (fluoride+argon): 12	<0.05	reduction in lesion depth: G2 vs G1: 44% G3 vs G1: 62% G3 vs G2: 32%
Miresmaeili et al. 2014 <sup>19</sup>	16 patients 16 exp teeth 16 ctr teeth (in each patient, one of the premolars was exp and the other was ctr)	surface microhardness	ctr group: 183.9 VHN exp group: 301.81 VHN	ctr group: 72.08 exp group: 94.29	<0.001 CI: 95%	laser irradiation resulted in significantly higher surface microhardness as compared to the control teeth
Rechmann et al. 2011 <sup>18</sup>	24 patients (12 patients with 4-week evaluation time + 12 patients with 12-week evaluation time) (the same teeth divided into the exp and ctr area)	sectional microhardness (overall relative mineral loss)	in the 4-week arm: ctr group: 737 ΔZ exp group: 402 ΔZ  in the 12-week arm: ctr group: 1,076 ΔZ exp group: 135 ΔZ	in the 4-week arm: ctr group: 131 exp group: 85  in the 12-week arm: ctr group: 254 exp group: 98	0.04  0.002	in the 4-week arm: laser produced 46% demineralization inhibition  in the 12-week arm: laser produced 86% demineralization inhibition
Suetenkov et al. 2015 <sup>20</sup>	60 patients (30 in each of the 2 groups)	growth in caries intensity (DMFT and DMFS indices)	ctr group (traditional preventive procedure): Δ DMFT: 2.77 Δ DMFS: 2.66 exp group (laser+traditional preventive procedure): Δ DMFT: 1.05 Δ DMFS: 1.37	ctr group (traditional preventive procedure): Δ DMFT: 0.56 Δ DMFS: 0.30 exp group (laser+traditional preventive procedure): Δ DMFT: 0.14 Δ DMFS: 0.13	<0.001	growth of dental and surface caries intensity was significantly lower in the experimental group

CI – confidence interval; ctr – control; DMFT: count of Decayed, Missing and Filled Teeth; DMFS: count of Decayed, Missing and Filled tooth Surfaces; Δ DMFT and Δ DMFS – growth in caries intensity indices; exp – experimental; G – group; PLM – polarized light microscopy; VHN – Vickers hardness number (measurement unit for surface microhardness); WSL – white spot lesion; ΔZ – overall relative mineral loss (measured by plotting normalized volume percent mineral against distance from the enamel surface; vol% × µm).

## The most effective and safest laser types and parameters for the prevention of enamel demineralization

Studies that compared the effectiveness of 2 or more laser beams in demineralization inhibition during orthodontic treatment were all in vitro.<sup>21,22</sup> Studies that compared the effect of different parameters of the same laser type were also in vitro and did not concern orthodontic treatment. There were no studies undertaken during orthodontic treatment comparing the improvement in demineralization resistance among different laser types or different laser settings.

## Discussion

The prevention of demineralization or WSL formation during orthodontic treatment is one of the most difficult challenges orthodontists have to face. Many preventive procedures have been used in the literature for this purpose. Laser irradiation has been widely studied in vitro and showed its effectiveness in increasing enamel resistance to decalcification, suggesting that it could be useful during orthodontic treatment. As presented in the literature, many laser types have been used to prevent enamel demineralization around orthodontic appliances, including Er:YAG,<sup>23–25</sup> Nd:YAG,<sup>13,21,22</sup> CO<sub>2</sub>,<sup>18–22,26–28</sup> diode,<sup>29,30</sup> and argon laser.<sup>14–17,31,32</sup> Although the clinical application of lasers during orthodontic treatment for a preventive purpose is still limited, the present review showed clinical effectiveness of laser irradiation in inhibiting enamel demineralization.

There were no clinical trials that applied Er:YAG or diode lasers during orthodontic treatment to prevent WSL formation.

In 3 studies, the application of argon laser irradiation on the enamel surface showed significant reduction in lesion depth in comparison with non-irradiated teeth, and its effect was significantly higher when it was combined with fluoride application,<sup>14–16</sup> but the sample sizes in these studies were small, with short follow-up periods. The effect of irradiation with an argon laser on WSL formation while curing the adhesives of orthodontic brackets was evaluated in 1 RCT lasting 1 year, but no significant effect on enamel demineralization was observed.<sup>17</sup>

Irradiation with a CO<sub>2</sub> laser had a significant effect on enamel microhardness around orthodontic brackets and it decreased mineral loss in comparison with non-irradiated enamel in 2 RCTs.<sup>18,19</sup> The wave lengths applied clinically were 9.6 μm and 10.6 μm, respectively. However, the effect of CO<sub>2</sub> lasers during orthodontic treatment was not evaluated for a long follow-up period.

The effect of Nd:YAG laser irradiation on existing WSLs was studied in only 1 clinical trial, with a 1-year follow-up.<sup>13</sup> The increases in the WSL area were signifi-

cantly lower in the laser-irradiated group of patients in comparison with the control group. This type of laser had not been previously applied clinically on sound enamel during orthodontic treatment to prevent decalcification.

The effect of an Optodan laser on enamel demineralization was studied in a RCT by comparing the development of tooth caries intensity (growth of the Decayed, Missing and Filled Teeth index – ΔDMFT, and growth of the Decayed, Missing and Filled tooth Surfaces index – ΔDMFS) between the laser group and the control group for a 1-year follow-up period, and it showed significantly lower caries intensity in the lased group as compared to the control non-irradiated group.<sup>20</sup>

Changes in the enamel structure after laser irradiation were evaluated in 2 of the included studies by scanning electron microscopy. Miresmaeili et al. evaluated enamel surface changes by extracting 2 premolars (irradiated and control) of 1 patient after 1 week of CO<sub>2</sub> laser irradiation; the lased tooth showed melting of the enamel surface.<sup>19</sup> As studied in the literature, the prevention of caries by CO<sub>2</sub> laser irradiation could stem from reduced enamel permeability and solubility as a result of melting.<sup>33,34</sup> Harazaki et al. studied enamel changes after Nd:YAG irradiation in vitro.<sup>13</sup> The irradiated portion of the tooth had a smooth surface with a small number of cracks.

The limitations of this review are related primarily to the lack of high-level evidence from RCTs and the heterogeneity among studies in irradiation protocols, outcomes, follow-up periods, and methods of outcome measurement.

## Conclusions

This review showed that laser irradiation may be effective in preventing demineralization during orthodontic treatment, but further studies are needed, including RCTs using different lasers, to evaluate which is the most effective laser and what settings should be used. There is also a need for longer follow-up periods to evaluate the longevity of treatment.

## References

1. Bergstrand F, Twetman S. A review on prevention and treatment of post-orthodontic white spot lesions – evidence-based methods and emerging technologies. *Open Dent J.* 2011;5:158–162.
2. Sudjalim TR, Woods MG, Manton DJ. Prevention of white spot lesions in orthodontic practice: A contemporary review. *Aust Dent J.* 2006;51(4):284–289,quiz 347.
3. Sundararaj D, Venkatachalapathy S, Tandon A, Pereira A. Critical evaluation of incidence and prevalence of white spot lesions during fixed orthodontic appliance treatment: A meta-analysis. *J Int Soc Prev Community Dent.* 2015;5(6):433–439.
4. Zabokova-Bilbilova E, Popovska L, Kapusevska B, Stefanovska E. White spot lesions: Prevention and management during the orthodontic treatment. *Pril (Makedon Akad Nauk Umet Odd Med Nauki).* 2014;35:161–168.
5. Lapenaite E, Lopatiene K, Ragauskaitė A. Prevention and treatment of white spot lesions during and after fixed orthodontic treatment: A systematic literature review. *Stomatologija.* 2016;18(1):3–8.

6. Featherstone JD. Lasers in dentistry 3. The use of lasers for the prevention of dental caries [in Dutch]. *Ned Tijdschr Tandheelkd*. 2002;109(5):162–167.
7. Karandish M. The efficiency of laser application on the enamel surface: A systematic review. *J Lasers Med Sci*. 2014;5(3):108–114.
8. Rodrigues LKA, de Freitas PM, Nobre-dos-Santos M. Lasers in caries prevention. In: Freitas PM, Simões A, eds. *Lasers in Dentistry: Guide for Clinical Practice*. Hoboken, NJ: Wiley-Blackwell; 2015:126–130.
9. Rezaei Y, Bagheri H, Esmailzadeh M. Effects of laser irradiation on caries prevention. *J Lasers Med Sci*. 2011;2(4):159–164.
10. Sadr Haghghi H, Skandarinejad M, Abdollahi AA. Laser application in prevention of demineralization in orthodontic treatment. *J Lasers Med Sci*. 2013;4(3):107–110.
11. Moher D, Liberati A, Tetzlaff J, Altman DG; PRISMA Group. Preferred Reporting Items for Systematic Reviews and Meta-Analyses: The PRISMA statement. *Int J Surg*. 2010;8(5):336–341.
12. Higgins JP, Altman DG, Gøtzsche PC, et al.; Cochrane Bias Methods Group, Cochrane Statistical Methods Group. The Cochrane Collaboration's tool for assessing risk of bias in randomised trials. *BMJ*. 2011;343:d5928.
13. Harazaki M, Hayakawa K, Fukui T, Isshiki Y, Powell LG. The Nd-YAG laser is useful in prevention of dental caries during orthodontic treatment. *Bull Tokyo Dent Coll*. 2001;42(2):79–86.
14. Anderson AM, Kao E, Gladwin M, Benli O, Ngan P. The effects of argon laser irradiation on enamel decalcification: An in vivo study. *Am J Orthod Dentofacial Orthop*. 2002;122(3):251–259.
15. Blankenau RJ, Powell G, Ellis RW, Westerman GH. In vivo caries-like lesion prevention with argon laser: Pilot study. *J Clin Laser Med Surg*. 1999;17(6):241–243.
16. Hicks J, Winn D 2<sup>nd</sup>, Flaitz C, Powell L. In vivo caries formation in enamel following argon laser irradiation and combined fluoride and argon laser treatment: A clinical pilot study. *Quintessence Int*. 2004;35(1):15–20.
17. Elaut J, Wehrbein H. The effects of argon laser curing of a resin adhesive on bracket retention and enamel decalcification: A prospective clinical trial. *Eur J Orthod*. 2004;26(5):553–560.
18. Rechmann P, Fried D, Le CQ, et al. Caries inhibition in vital teeth using 9.6- $\mu\text{m}$  CO<sub>2</sub>-laser irradiation. *J Biomed Opt*. 2011;16(7):071405.
19. Miresmaeili A, Farhadian N, Rezaei-soufi L, Saharkhizan M, Veisi M. Effect of carbon dioxide laser irradiation on enamel surface microhardness around orthodontic brackets. *Am J Orthod Dentofacial Orthop*. 2014;146(2):161–165.
20. Suetenkov DY, Petrova AP, Kharitonova TL. Photo activated disinfection efficiency of low-intensity laser and comprehensive prevention of caries and gingivitis in adolescents using bracket system. *J Innovat Opt Health Sci*. 2015;8(3):1541002.
21. Seino PY, Freitas PM, Marques MM, de Souza Almeida FC, Botta SB, Moreira MS. Influence of CO<sub>2</sub> (10.6  $\mu\text{m}$ ) and Nd:YAG laser irradiation on the prevention of enamel caries around orthodontic brackets. *J Lasers Med Sci*. 2015;30(2):611–616.
22. Paulos RS, Seino PY, Fukushima KA, et al. Effect of Nd:YAG and CO<sub>2</sub> laser irradiation on prevention of enamel demineralization in orthodontics: In vitro study. *Photomed Laser Surg*. 2017;35(5):282–286.
23. Ulkur F, Sungurtekin Ekçi E, Nalbantgil D, Sandalli N. In vitro effects of two topical varnish materials and Er:YAG laser irradiation on enamel demineralization around orthodontic brackets. *Sci World J*. 2014;2014:490503.
24. Fornaini C, Brulat N, Milia G, Rockl A, Rocca JP. The use of sub-ablative Er:YAG laser irradiation in prevention of dental caries during orthodontic treatment. *Laser Ther*. 2014;23(3):173–181.
25. Garma NM, Jasim ES. The effect of Er:YAG laser on enamel resistance to caries during orthodontic treatment: An in vitro study. *J Bagh Coll Dentistry*. 2015;27(1):182–188.
26. de Souza-e-Silva CM, Parisotto TM, Steiner-Oliveira C, Kamiya RU, Rodrigues LK, Nobre-dos-Santos M. Carbon dioxide laser and bonding materials reduce enamel demineralization around orthodontic brackets. *J Lasers Med Sci*. 2013;28(1):111–118.
27. Mirhashemi AH, Hakimi S, Ahmad Akhoundi MS, Chiniforush N. Prevention of enamel adjacent to bracket demineralization following carbon dioxide laser radiation and titanium tetra fluoride solution treatment: An in vitro study. *J Lasers Med Sci*. 2016; 7(3):192–196.
28. Stangler LP, Romano FL, Shirozaki MU, et al. Microhardness of enamel adjacent to orthodontic brackets after CO<sub>2</sub> laser irradiation and fluoride application. *Braz Dent J*. 2013;24(5):508–512.
29. Lacerda AS, Hanashiro FS, de Sant'Anna G, Steagall W Júnior, Barbosa P, de Souza-Zaroni WC. Effects of near infrared laser radiation associated with photoabsorbing cream in preventing white spot lesions around orthodontic brackets: An in vitro study. *Photomed Laser Surg*. 2014;32:686–693.
30. Lara-Carrilloa E, Doroteo-Chimalb C, Lopez-Gonzalez S, et al. Remineralization effect of low-level laser and amorphous sodium–calcium–phosphosilicate paste in teeth with fixed orthodontic appliances. *Tanta Dent J*. 2016;13(1):55–62.
31. Miresmaeili A, Etrati Khosroshahi M, Motahary P, et al. Effect of argon laser on enamel demineralization around orthodontic brackets: An in vitro study. *J Dent (Tehran)*. 2014;11(4):411–417.
32. Noel L, Rebellato J, Sheats RD. The effect of argon laser irradiation on demineralization resistance of human enamel adjacent to orthodontic brackets: An in vitro study. *Angle Orthod*. 2003;73(3):249–258.
33. Stern RH, Vahl J, Sognaes RF. Lased enamel: Ultrastructural observations of pulsed carbon dioxide laser effects. *J Dent Res*. 1972;51(2):455–460.
34. Borggreven JM, van Dijk JW, Driessens FC. Effect of laser irradiation on the permeability of bovine dental enamel. *Arch Oral Biol*. 1980;25:831–832.

## Local drug delivery in periodontitis treatment: A review of contemporary literature

## Miejscowe dokieszonkowe podawanie leków w zapaleniu przyzębia – przegląd współczesnego piśmiennictwa

Małgorzata Szulc<sup>A,D</sup>, Aneta Zakrzewska<sup>B,D</sup>, Jacek Zborowski<sup>B,D</sup>

Department of Periodontology, Wrocław Medical University, Poland

A – research concept and design; B – collection and/or assembly of data; C – data analysis and interpretation;  
D – writing the article; E – critical revision of the article; F – final approval of the article

Dental and Medical Problems, ISSN 1644-387X (print), ISSN 2300-9020 (online)

*Dent Med Probl.* 2018;55(3):333–342

### Address for correspondence

Małgorzata Szulc  
E-mail: malgorzata.szulc@umed.wroc.pl

### Funding sources

None declared

### Conflict of interest

None declared

Received on July 9, 2018  
Reviewed on August 11, 2018  
Accepted on September 5, 2018

### Abstract

Traditional methods of non-surgical treatment of periodontitis, including mechanical scaling/root planing (SRP), do not guarantee remission of the disease. Local delivery of antimicrobial agents in periodontitis entails antimicrobial therapy placed directly in periodontal pockets. The advantage of this form of treatment is that the concentration of the drug after application significantly exceeds the minimum inhibitory concentration (MIC) and persists for up to several weeks. Therefore, many systems of locally applied devices, using a variety of antibiotics or antiseptics have been developed. There is continuous research aimed at introducing new forms of locally administered drugs, some of which have not proved to be effective, while others are promising. For almost 30 years such systems have been used for treatment as an adjuvant to SRP, and their efficacy has been evaluated. The aim of this article is to systematically review the contemporary literature regarding the currently available chemotherapeutics locally administered in the treatment of periodontitis.

**Key words:** periodontitis, local drug delivery, chlorhexidine chip

**Słowa kluczowe:** zapalenie przyzębia, miejscowe dokieszonkowe podawanie leków, listek chlorheksydynowy

### DOI

10.17219/dmp/94890

### Copyright

© 2018 by Wrocław Medical University  
and Polish Dental Society  
This is an article distributed under the terms of the  
Creative Commons Attribution Non-Commercial License  
(<http://creativecommons.org/licenses/by-nc-nd/4.0/>)

According to epidemiological studies conducted in Poland in 2012, 51.1% of people aged 35–44 years suffer from chronic periodontitis.<sup>1</sup> Deep periodontal pockets (>6 mm) were found in 16.4% of people in this age group.<sup>1</sup> Traditional methods of non-surgical treatment, including mechanical scaling/root planing (SRP), do not guarantee remission of the disease. The additional use of antibiotics systemically in the treatment of periodontitis is limited, due to the need for high doses to achieve the appropriate concentration of the drug in the gingival fluid, rapidly growing resistance of the bacteria, and side effects of the drugs. In addition, due to the advanced organization of the structure and function of the subgingival biofilm, antibiotics may not be effective or can be inactivated.

Therefore, for almost 30 years, drug systems (antibiotics and antiseptics) have been developed in the form of direct subgingival administration.<sup>2,3</sup> The advantage of this form of treatment that the concentration of the drug after application significantly exceeds the minimum inhibitory concentration (MIC) and persists for up to several weeks. With this form of application, many side effects that are associated with general antibiotic therapy can be avoided. However, it is always possible to use multi-drug systems as an add-on to non-surgical treatment of the periodontium and not as an independent form of therapy. The first papers evaluating such drugs showed high efficiency of the evaluated systems and recommended them as a valuable auxiliary element in the treatment of deep pockets in periodontitis.<sup>4</sup>

The aim of this article is to present a systematic review of the literature regarding the currently available chemotherapeutics locally administered in the treatment of periodontitis.

To assess the efficacy of medications used in the treatment of periodontitis, studies published since 2010, available in the MEDLINE and Scopus databases, were qualified. The key words used for searching were: “chlorhexidine chip”, “PerioChip<sup>®</sup>”, “chlorhexidine xanthan gel”, “metronidazole gel”, “Elyzol<sup>®</sup>”, “Periodontal Plus<sup>®</sup> AB”, “tetracycline fiber”, “subgingival antibiotic therapy”, “local drug delivery”, “doxycycline hyclate”, “Arestin<sup>®</sup>”, “and Atridox<sup>®</sup>”. In all of the studies considered, the efficacy of administering the drug carrier to periodontal pockets after the SRP procedure was compared to a control group that was treated only by SRP. In all of these studies, the effects of the treatment on the periodontal pocket depth (PD) and on the level of the connective tissue attachment – clinical attachment level (CAL) were evaluated. The minimum follow-up period in the selected studies was 3 months.

All the key words in the search strategy were defined based on the following focus question and the population, intervention, comparison, and outcome (PICO) framework: “Does local drug delivery (LDD) significantly improve the clinical parameters in comparison with the tra-

ditional protocol for the treatment of periodontitis?”. This question is addressed according to the following criteria:

- population: humans presenting periodontitis;
- intervention: usage of LDD after SRP in the treatment of periodontal pockets;
- control: periodontal pockets after SRP alone;
- outcome: improvement of periodontal condition evaluated with PD and CAL measurements.

## Chlorhexidine

The antibacterial activity of chlorhexidine (CHX) results from the fact that its molecules have a positive charge. Therefore, it has a strong affinity with negatively charged ions or molecules of microorganisms, salivary glycoproteins and salivary phosphoproteins, and their acquired casings, oral mucosa epithelial cells.<sup>3,5</sup> By binding to negatively charged cell walls of microorganisms, CHX changes the osmotic balance of cells, leading to leakage or precipitation of elements of the cytoplasm, which causes their death or significant limitation of function. By binding to the anionic acid groups of salivary glycoproteins, CHX inhibits the formation of acquired casings and the colonization of plaque.<sup>3</sup> It also binds to salivary bacteria, disrupting their adsorption on the tooth surface.

Binding of CHX molecules to the surface of the teeth and mucous membranes results in the release of the antiseptic from these reservoirs for a long time, so the effect of CHX substantively lasts for several hours after its application. Chlorhexidine retains its properties in an alkaline environment (which prevails in periodontal pockets); at pH < 7, it works less effectively. It is inactivated by plasma proteins, so it is not used in the decontamination of open wounds.<sup>6</sup> Studies have shown very low CHX toxicity and no bacterial resistance. However, in recent years there have been reports in the literature of the emergence of CHX-resistant bacterial strains, including multi-drug-resistant strains that can survive in the biofilm, especially when CHX is used for too long.<sup>7</sup>

## Preparations containing chlorhexidine

In the treatment of periodontitis, a 4 × 5 mm film, of a thickness of approx. 350 μm and weighing approx. 7 mg, containing 2.5 mg CHX gluconate is used – PerioChip (Dexel Pharma, Or Akiva, Israel) or PerioCol<sup>®</sup>-CG (Eucare Pharmaceuticals Ltd., Chennai, India). The matrix is formed by transversely cross-linked hydrolyzed gelatin and glycerol or type I collagen of fish origin. The advantage of chitosan films is their bioadhesive, antibacterial and wound-healing properties. After administration, gradual release of CHX takes about 7–9 days. The highest concentration of the drug in the gingival fluid is maintained for about 72 h (1400–1900 μg/mL, with 125 μg/mL being considered the concentration elimi-

nating 99% of bacteria).<sup>8</sup> After this time, the concentration decreases gradually. Another application of the film is recommended after 3–4 weeks.

A second form of CHX used in intra-pocket applications in the treatment of periodontitis is a plastic gel containing 1.5% CHX in 2 forms: 0.5% chlorhexidine digluconate and 1% chlorhexidine dihydrochloride – Chlosite® (Ghimas S.p.A., Casalecchio di Reno, Italy). These active substances are suspended in xanthan – a saccharide polymer that forms a 3-dimensional pseudo-plastic mesh with water, which maintains and slowly releases the compounds contained therein. According to the manufacturer's information, chlorhexidine digluconate is rapidly released during the first 24 h. About 34% of the total amount of CHX is released from the gel at a fast and constant rate, reaching a concentration greater than 100 µg/mL, which allows the destruction of pathogenic bacteria.<sup>9</sup> This process takes on average 6–9 days and releases 85% of the total amount of CHX contained in the gel. At the same time, chlorhexidine dihydrochloride is released slowly and, by maintaining a concentration with bacteriostatic and bactericidal action, prevents recolonization of the pockets by

pathogenic bacteria. After 9 days, when chlorhexidine digluconate is completely released, the presence of dihydrochloride ensures the efficacy and microbiological activity of the drug for another 6 days.<sup>9</sup>

Tables 1 and 2 present the results of studies on subgingival forms of drugs containing CHX. In the majority of studies published in 2010–2016, evaluating the effectiveness of the CHX film, there was no improvement in the clinical status of periodontal tissues after the treatment. Two publications confirm a statistically significant improvement in the parameters evaluated after using a CHX chip in comparison with traditional treatment. In a study by Pattnaik et al.<sup>13</sup>, after a 3-month observation, PD was reduced by 2.36 mm ±0.84 and CAL was improved by 2.29 mm ±0.5 (p < 0.001). In a study by Lecic et al., after 3 months of observation, periodontal pockets were 3.41 mm shallower and CAL improved by 1 mm (p < 0.001).<sup>14</sup> Among the studies evaluating the efficacy of a gel containing 2 CHX compounds, only 2 show no statistically significant improvement in the parameters evaluated. In 5 articles, CAL was improved and periodon-

**Table 1.** List of studies using chlorhexidine (CHX) in the form of a film (PerioChip, PerioCol-CG)

Author	Assessed groups	Time of observation	Results		p-value	
			test group	control group		
Sakellari et al. 2010 <sup>10</sup>	50 patients (4 pockets >5 mm, <7 mm) 25 patients – SRP 25 patients – SRP and CHX assessed: PD, CAL 8 bacteria, DNA-DNA hybridization	6 months	no statistically significant differences between assessed clinical and microbiological parameters		–	
Medaiah et al. 2014 <sup>11</sup>	15 patients (3 pockets >5 mm) 15 pockets – SRP 15 pockets – SRP and CHX 15 pockets – CHX assessed: PD, CAL	3 months	no statistically significant differences between assessed clinical parameters		–	
Kumar et al. 2014 <sup>12</sup>	30 patients 10 patients – SRP 10 patients – SRP and CHX 10 patients – PerioChip® assessed: PD, CAL, BANA	3 months	no statistically significant differences between assessed clinical and biochemical parameters		–	
Pattnaik et al. 2015 <sup>13</sup>	20 patients, split mouth 20 pockets – SRP and CHX 20 pockets – SRP assessed: PD, CAL	1 month 3 months	PD [mm]	baseline: 6.42 ±1.04	6.52 ±1.15	–
				change after 1 month: 1.45 ±0.59	0.87 ±0.34	<0.001
			CAL [mm]	baseline: 6.28 ±1.01	6.27 ±1.22	–
				change after 1 month: 1.23 ±0.42	0.77 ±0.36	<0.001
Lecic et al. 2016 <sup>14</sup>	40 pockets, split mouth 20 pockets – SRP and CHX 20 pockets – SRP assessed: PD, CAL	1 month 3 months	PD [mm]	baseline: 5.70 ±0.97	5.25 ±1.01	–
				after 1 month: 2.80 ±1.28	3.10 ±0.71	NS
			CAL [mm]	baseline: 3.70 ±1.41	3.90 ±1.02	–
				after 1 month: 2.65 ±1.69	2.85 ±1.13	NS

Data presented as mean ± standard deviation (SD). SRP – scaling/root planing; PD – pocket depth; CAL – clinical attachment level; BANA – referring to the enzymatic breakdown of N-benzoyl-dL-arginine-2-naphthylamide; NS – nonsignificant.

**Table 2.** List of studies using chlorhexidine (CHX) in the form of a gel (Chlosite)

Author	Assessed groups	Time of observation	Results			p-value
				test group	control group	
Kranti et al. 2010 <sup>15</sup>	10 patients (60 pockets) 30 pockets – SRP and placebo 30 pockets – SRP and CHX assessed: PD, CAL	3 months	PD [mm]	reduction after 3 months: 2.25 ±0.58	1.68 ±0.50	<0.001
			6 months	reduction after 6 months: 3.11 ±0.47	2.44 ±0.55	<0.001
		6 months	CAL [mm]	gain after 3 months: 2.24 ±0.62	1.69 ±1.03	<0.001
				gain after 6 months: 3.11 ±0.65	2.44 ±0.98	<0.001
Verma et al. 2012 <sup>9</sup>	46 patients (92 pockets) 46 pockets – SRP 46 pockets – SRP and CHX assessed: PD, CAL	1 month	PD [mm]	difference between 1 month and 3 months: 1.24 ±0.82	0.35 ±0.67	<0.001
		3 months	CAL [mm]	difference between 1 month and 3 months: 0.85 ±0.63	0.22 ±0.42	<0.001
Matesanz et al. 2013 <sup>16</sup>	21 patients (4–10 pockets >4mm) SRP and placebo SRP and CHX assessed: PD, CAL	1 month 3 months 6 months		no statistically significant improvement of assessed parameters		
Chauhan et al. 2013 <sup>17</sup>	40 patients 20 patients [pockets?] – SRP 20 patients – SRP and CHX assessed: PD, CAL	3 months	PD [mm]	baseline: 5.95 ±0.31 after 3 months: 3.48 ±0.34	5.90 ±0.27 4.30 ±0.33	– <0.001
			CAL [mm]	baseline: 6.15 ±0.36 after 3 months: 5.03 ±0.36	6.10 ±0.38 5.55 ±0.37	– NS
Chitsazi et al. 2013 <sup>18</sup>	20 patients, split mouth 20 patients [pockets] – SRP 20 patients – SRP and CHX assessed: PD, CAL	1 month 3 months		no statistically significant improvement of assessed parameters		
Jain et al. 2013 <sup>19</sup>	30 patients, split mouth 30 pockets – SRP 30 pockets – SRP and CHX assessed: PD, CAL	6 weeks	PD [mm]	baseline: 5.20 ±0.48 after 6 weeks: 2.60 ±0.81	5.20 ±0.48 3.00 ±0.91	– 0.083
			3 months	after 3 months: 2.50 ±0.73	3.07 ±0.69	0.002
		6 months		after 6 months: 2.40 ±0.68	3.00 ±0.91	0.002
			CAL [mm]	baseline: 11.70 ±2.81 after 6 weeks: 10.37 ±3.11	11.43 ±2.75 9.30 ±2.96	<0.001
		3 months		after 3 months: 10.03 ±2.98	9.20 ±2.85	0.006
		6 months		after 6 months: 10.03 ±2.98	9.20 ±0.51	0.014
Phogat et al. 2014 <sup>20</sup>	10 patients SRP SRP and CHX assessed: PD, CAL	1 month	PD [mm]	change after 1 month: 2.14 ±0.01	1.16 ±0.06	<0.001
		3 months	CAL [mm]	change after 3 months: 3.76 ±0.01	2.26 ±0.03	<0.001
				change after 1 month: 2.41 ±0.01	2.04 ±0.09	<0.001
				change after 3 months: 2.91 ±0.05	2.41 ±0.08	<0.001

Data presented as mean ± standard deviation (SD). SRP – scaling/root planing; PD – pocket depth; CAL – clinical attachment level; NS – nonsignificant.

tal pockets became shallower compared to the control group, and the results were statistically significant.

In both the CHX film and xanthan gel studies, the short follow-up periods are worth noting – the maximum time observation period is 6 months – as are the small study groups. In addition, it should be emphasized that in the period after 2010, fewer works evaluate the additional use of CHX carriers as adjunctive treatment in periodontitis. In a systematic review of LDD methods published in 2005, 17 reviews of CHX chips were collected.<sup>21</sup> A statistically significant improvement in PD was observed in 2 studies, and in CAL – in 3 works. Taking this into account, it seems that CHX on a xanthan carrier may prove to be a valuable addition to traditional treatment.

## Tetracycline

Tetracyclines are broad-spectrum bacteriostatic antibiotics for Gram-positive and Gram-negative bacteria, *Rickettsia* sp., *Mycoplasma* sp., *Chlamydia* sp., and *Spirochaeta* sp.<sup>22</sup> They do not act in viral or fungal infections. The basis of the chemical structure of this group of antibiotics is the 4-membered tetracycline ring, which affects their physicochemical properties, such as alkaline nature, poor solubility in water and durability. The mechanism of action of tetracyclines consists in inhibiting protein biosynthesis and phosphorylation processes in bacterial cells. Tetracyclines are teratogenic and embryotoxic. They should not be used in pregnant women or in children un-



der 12 years due to the accumulation of tetracycline-calcium-phosphate complexes in the shafts of long bones.

In the last 2 decades, the use of tetracyclines in many bacterial infections has been limited due to the widespread development of bacteria resistant to the antibiotics of this group. Two types of tetracycline resistance are known: nonspecific and specific.<sup>23,24</sup> The former is low-grade resistance and results from the reduction of tetracycline transport through purine channels in the outer membrane to the interior of the cell. Specific resistance can be associated with one of the 3 mechanisms: enzymatic inactivation of drug molecules; removal of tetracyclines from the inside of bacterial cells by means of active pumps; or protection of the ribosome against tetracyclines.

Minocycline is the most lipid-soluble and most active semi-synthetic tetracycline antibiotic. It affects both Gram-positive and Gram-negative bacteria as well as bacteria that do not have a cell wall. The action of minocycline is related to the inhibition of protein synthesis. Minocycline pass-

es directly through the lipid bilayer or passively diffuses through the porous channels in the bacterial membrane. It binds to the 30S ribosomal subunit, which prevents the binding of tRNA to the mRNA-ribosomal complex, as a result of which protein translation is stopped.<sup>23</sup> The weakness and impaired function of the bacteria leads to their destruction by the body's natural defense mechanisms.

A periodontics preparation containing minocycline is Arestin (OraPharma Inc., Warminster, USA). It contains 1 mg of minocycline in the form of microspheres. Arestin has an application system constructed in such a way that the microspheres are administered in the form of a powder to allow easy, targeted placement at the base of the periodontal pocket. After placing the preparation in the pocket, the microspheres instantly aggregate into the surrounding surfaces, providing a prolonged release of minocycline at the site of active infection.

In the majority of the studies reviewed (Table 3), statistically significant effects were found between the study

**Table 3.** List of studies evaluating the efficacy of subgingival minocycline

Author	Assessed groups	Time of observation	Results		p-value	
			test group	control group		
Tabenski et al. 2017 <sup>25</sup>	30 patients 15 [pockets?] – SRP 15 – SRP+minocycline assessed: PD, CAL	3 months 6 months 12 months	no statistically significant improvement of assessed parameters			
Killeen et al. 2016 <sup>26</sup>	27 patients – SRP 24 patients – SRP+minocycline assessed: PD, CAL	6 months 12 months	PD [mm]	baseline: 5.30 ±0.60 after 6 months: 0.92 ±0.83 after 12 months: 1.00 ±0.95	5.50 ±0.80 0.62 ±1.02 1.22 ±0.80	– <0.001 <0.001
			CAL [mm]	baseline: 5.40 ±0.70 after 6 months: 0.92 ±0.83 after 12 months: 0.70 ±0.88	5.80 ±0.90 0.65 ±1.13 1.22 ±0.93	– <0.001 0.006
			PD [mm]	baseline: 6.28 ±0.50 after 3 months: 4.80 ±0.70 after 6 months: 4.40 ±0.40	6.53 ±0.43 5.90 ±0.60 5.58 ±0.60	– <0.05 <0.05
			CAL [mm]	baseline: 6.80 ±0.20 after 3 months: 5.75 ±0.35 after 6 months: 5.75 ±0.15	6.90 ±0.40 6.40 ±0.30 6.45 ±0.70	– <0.05 <0.05
Pandit et al. 2013 <sup>28</sup>	20 patients 20 pockets – SRP 20 pockets – SRP+minocycline assessed: PD, CAL	1 month 3 months	PD [mm]	baseline: 6.85 ±0.81 after 1 month: 4.75 ±0.72 after 3 months: 3.75 ±0.79	6.25 ±0.91 5.30 ±0.80 4.60 ±0.82	– 0.020 <0.001
			CAL [mm]	baseline: 7.05 ±1.65 after 1 month: 5.30 ±1.31 after 3 months: 4.45 ±1.20	6.65 ±1.75 5.90 ±1.43 4.95 ±1.65	– <0.001 0.030
			PD [mm]	baseline: 6.13 ±0.79 after 3 months: 2.84 ±0.44 after 6 months: 2.25 ±0.46	5.82 ±0.48 3.36 ±0.37 2.60 ±0.47	– <0.001 <0.001
			CAL [mm]	baseline: 6.19 ±0.85 after 3 months: 2.79 ±0.53 after 6 months: 2.31 ±0.42	5.97 ±0.68 3.51 ±0.43 2.66 ±0.38	– <0.001 <0.001

Data presented as mean ± standard deviation (SD). SRP – scaling/root planing; PD – pocket depth; CAL – clinical attachment level; NS – nonsignificant.

groups. In the group where minocycline was used in addition to standard SRP therapy, better PD and CAL values were found in comparison with the control group. The results obtained depended to a large extent on the time in which the assessment was conducted, and it is worth noting that the research cohorts were not very large. The observation periods lasted up to 12 months. In research carried out between 1993 and 2002, statistically significant reduction in PD in comparison with traditional non-surgical treatment was achieved in 4 of the 8 works reviewed.<sup>22</sup>

Doxycycline is a long-acting tetracycline antibiotic. Its antibacterial spectrum is *Brucella* sp., *Mycoplasma* sp., *Pasteurella tularensis*, *Chlamydia* sp., *Ureaplasma* sp., *Neisseria gonorrhoeae*, *Leptospira* sp., *Actinomyces* sp., *Haemophilus* sp., *Rickettsia* sp., *Borrelia* sp. (*B. burgdorferi*), *Treponema* sp., *Yersinia* sp., *Legionella* sp., *Campylobacter* sp., *Vibrio* sp., *Listeria* sp., *Moraxella catarrhalis*, streptococci, including *Streptococcus pneumoniae* (resistant strains are present), Gram-negative rods from the Enterobacteriaceae family (resistant strains), with the exception of *Proteus* sp., *Providencia* sp., *Serratia* sp., staphylococci, anaerobes *Propionibacterium* sp., *Clostridium* sp. as well as *Bacteroides fragilis* (resistant strains).<sup>23,24</sup> Tetracyclines are inactive against *Pseudomonas aeruginosa*. The mechanism of resistance of bacterial strains is associated with reduction in the ability to penetrate the inside

of the bacterial cell or with active removal of the antibiotic from the bacterial cell.<sup>23,24</sup> The antibacterial spectrum is very wide, but the long-term use of tetracyclines in clinical practice has led to the selection of a high percentage of resistant strains both among Gram-positive cocci and Gram-negative bacilli.

Atridox (DenMat, Lompoc, USA) is a preparation that releases subgingival doxycycline. Before use, one should mix the contents of the 2 syringes in which the product is delivered. Syringe A contains 450 mg of Atrigel, which is a bioabsorbable, liquid polymer preparation of poly(DL-lactide) (PDLA), dissolved in 63.3% *N*-methyl-2-pyrrolidone (NMP). Syringe B contains 42.5 mg of active doxycycline. The product thus formed is a light yellow viscous liquid with a concentration of 10%. The preparation is inserted into the periodontal pocket using a bent needle, filling the pocket to the edge of the gum. The filled pocket should be covered with surgical cement. The dressing is left for 7 days, and then Atridox can be removed or allowed to biodegrade.

In 3 out of the 5 studies evaluated (Table 4), statistically significant differences were found between the study groups.<sup>30,33,34</sup> In the group where doxycycline was used in addition to standard SRP therapy, better PD and CAL values were obtained in comparison with the control group. In the remaining 2 studies, no statistical differences were

**Table 4.** List of studies evaluating the efficacy of intra-pocket doxycycline (Atridox)

Author	Assessed groups	Time of observation	Results			p-value
				test group	control group	
Ahamed et al. 2013 <sup>30</sup>	12 patients 30 pockets – SRP 30 pockets – SRP+doxycycline assessed: PD, CAL	6 months	PD [mm]	baseline: 6.40 ±0.20	6.60 ±0.30	–
				gain after 6 months: 4.50 ±1.10	5.80 ±1.10	<0.040
			CAL [mm]	gain after 6 months: 1.00 ±0.70	0.36 ±0.40	<0.050
Javali and Vandana 2012 <sup>31</sup>	4 patients 130 pockets SRP SRP+doxycycline assessed: PD, CAL	3 months	no statistically significant difference between groups in assessed parameters			
Al Hulami et al. 2011 <sup>32</sup>	12 patients 12 pockets – SRP 12 pockets – SRP+doxycycline assessed: PD, CAL	3 months	no statistically significant difference between groups in assessed parameters			
Deo et al. 2011 <sup>33</sup>	60 patients 30 patients – SRP 30 patients – SRP+doxycycline assessed: PD, CAL	6 months	PD [mm]	baseline: 5.83 ±0.53	5.70 ±0.65	–
				after 6 months: 2.80 ±0.76	3.40 ±0.49	<0.001
			CAL [mm]	baseline: 6.50 ±0.50	6.53 ±0.68	0.830
				after 6 months: 4.50 ±0.50	5.40 ±0.67	<0.001
Sandhya et al. 2011 <sup>34</sup>	45 patients 45 pockets – SRP 45 pockets – SRP+doxycycline assessed: PD, CAL	1 month	PD [mm]	baseline: 6.40 ±1.03	6.27 ±1.07	–
				after 1 month: 4.93 ±0.94	5.20 ±1.06	0.209
		6 months		after 6 months: 3.47 ±0.63	4.53 ±0.73	<0.001
			CAL [mm]	baseline: 5.60 ±0.96	5.47 ±1.04	–
			after 1 month: 4.20 ±0.92	4.40 ±1.03	0.334	
				after 1 month: 4.20 ±0.92	3.73 ±0.86	<0.001

Data presented as mean ± standard deviation (SD). SRP – scaling/root planing; PD – pocket depth; CAL – clinical attachment level; NS – nonsignificant.

found between the groups. The periods of observation were short (3–6 months) and the number of participants was small (4–12 patients). However, it is worth noting that in studies conducted on a larger number of patients (45–60 people), a statistically significant improvement in the clinical parameters evaluated was achieved.<sup>33,34</sup>

## Tetracycline fibers

Periodontal Plus AB (Advanced Biotech Products (P) Ltd., Chennai, India) is a biodegradable collagen fiber soaked with 8% tetracycline, releasing the drug in the dental pocket for a period of 10–14 days.<sup>35</sup> A collagen tow containing 25 mg of pure filamentous type I collagen provides a carrier for about 1.7 mg of tetracycline hydrochloride. This collagen strand is not transversely cross-linked, which results in systematic release of the drug according to how the collagen fibers are degraded. The advantages of this product are easy placement and good retention in the gingival pocket.<sup>36</sup>

A study assessing the therapeutic effects resulting from the use of additional tetracycline fibers over longer periods clearly shows greater reduction in PD and a greater improvement in CAL (Table 5).<sup>37–40</sup> The results of the test group, where a combined therapy in the form of SRP and Periodontal Plus AB was used, and the results of the control group, where only SRP was used, were significantly better at the end of the therapy than at the beginning, but they were comparable between the 2 groups, without significant statistical differences ( $p = 0.288$ ,  $p = 0.0530$ , respectively).<sup>39</sup> However, in all the works with follow-up periods longer than 3 months<sup>37–40</sup> as well as in the review by Nadjig and Shah,<sup>41</sup> the improvement of the PD and CAL parameters was significant ( $p < 0.05$ ), which clearly indicates that the use of fibers saturated with tetracycline in addition to mechanical cleansing favorably improves the effects of treatment and enhances tissue healing. The benefits of using tetracycline threads observed over a period of 90 days are undoubtedly as-

**Table 5.** List of studies evaluating the efficacy of tetracycline fibers (Periodontal Plus AB)

Author	Assessed groups	Time of observation	Results		p-value	
			test group	control group		
Sachdeva and Agarwal 2011 <sup>37</sup>	35 patients test group – SRP+Periodontal Plus AB® control group – SRP assessed: PD, CAL	1 month 2 months 3 months	PD [mm]	baseline: 6.83 ± 0.85	6.71 ± 0.93	0.001
				after 1 month: 5.23 ± 1.00	5.69 ± 0.99	
				after 2 months: 4.29 ± 1.04	5.29 ± 0.78	
			CAL [mm]	after 3 months: 4.14 ± 1.08	5.14 ± 0.73	0.001
				baseline: 7.31 ± 1.10	7.29 ± 1.04	
				after 1 month: 6.20 ± 1.23	6.49 ± 0.88	
Dodwad et al. 2012 <sup>38</sup>	40 patients test group – SRP+Periodontal Plus AB® control group – SRP assessed: PD, CAL	1 month 3 months	PD [mm]	after 2 months: 5.69 ± 1.32	6.29 ± 1.10	0.015
				after 3 months: 5.43 ± 1.21	6.26 ± 1.06	
				baseline: 3.55 ± 0.81	3.27 ± 0.88	
			CAL [mm]	after 1 month: 2.53 ± 0.59	2.92 ± 0.97	0.125
				after 3 months: 2.14 ± 0.54	2.78 ± 0.96	
				baseline: 13.80 ± 0.83	13.10 ± 1.97	
Sinha et al. 2014 <sup>39</sup>	100 patients test group – SRP+Periodontal Plus AB® control group – SRP assessed: PD, CAL	15 days 45 days 90 days	PD [mm]	after 1 month: 11.35 ± 0.67	12.40 ± 2.09	0.043
				after 3 months: 10.70 ± 0.87	12.15 ± 2.28	
				baseline: 5.80 ± 0.65	5.61 ± 0.51	
			CAL [mm]	after 15 days: 4.66 ± 0.64	5.38 ± 0.69	0.018
				after 45 days: 4.16 ± 0.76	5.14 ± 0.64	
				after 90 days: 3.42 ± 0.79	4.44 ± 0.75	
Khan et al. 2015 <sup>40</sup>	40 patients test group – SRP+Periodontal Plus AB® control group – SRP assessed: PD, CAL	3 months	PD [mm]	baseline: 3.67 ± 1.63	3.55 ± 0.56	0.530
				after 15 days: 2.81 ± 0.61	3.36 ± 0.69	
				after 45 days: 2.22 ± 0.71	3.14 ± 0.63	
			CAL [mm]	after 90 days: 1.45 ± 0.65	2.54 ± 0.65	0.000
				baseline: 6.00 ± 0.72	5.58 ± 0.55	
				after 3 months: 3.28 ± 0.60	4.18 ± 0.71	
CAL [mm]	baseline: 10.70 ± 0.61	10.48 ± 0.64	<0.001			
	after 3 months: 8.03 ± 0.55	9.01 ± 0.64				

Data presented as mean ± standard deviation (SD). SRP – scaling/root planing; PD – pocket depth; CAL – clinical attachment level; NS – nonsignificant.

sociated with the adhesive properties of tetracyclines in relation to root cement and the inhibitory effects on collagenase and matrix metalloproteinase.<sup>39,40</sup>

## Metronidazole

Metronidazole is a chemotherapeutic active against most Gram-positive and Gram-negative anaerobic bacteria and protozoa. It easily penetrates into single-cell organisms and bacteria. Metronidazole oxidase reduction potential is lower than in the case of ferredoxin – an electron-transporting protein found in anaerobic and oxygen-poor organisms. The potential difference causes the reduction of the 5-nitro group of metronidazole, and the compound makes the DNA chain break in these organisms.<sup>42</sup>

In periodontology, metronidazole is administered in the form of Elyzol Dentagel (A. L. Pharma, Englewood, USA), with a 25% concentration corresponding to 1 g of metronidazole benzoate encapsulated in a glycerol matrix and sesame oil.<sup>35</sup> Concentrations of approx. 120 µg/mL are measurable for at least 8 h and concentrations over 1 µg/mL have been found at 36 h. Applied to the periodontal pocket twice a week, it tightens in contact with the gum fluid, precipitating crystals.<sup>35</sup>

In one of the studies reviewed, the reduction of PD during the 3-month follow-up period was statistically significant in both the test group, which combined SRP and a metronidazole gel, and the SRP-only control group.<sup>28</sup> The reduction of PD by an additional 0.5 mm in the test group in comparison with the control group was non-significant, as was the improvement in CAL by an additional 0.25 mm. In the second of the studies evaluated, the reduction of PD in both groups was statistically significant, especially in the first 6 weeks of observation ( $p < 0.001$ ).<sup>43</sup>

However, there were no statistically significant differences in the improvement of CAL between the test and control group (Table 6). In a review by Bonito et al., ambiguous results were observed. Out of 11 studies reviewed, statistically significant improvement in CAL was observed in only 2 – 0.66 mm after 6 weeks ( $p < 0.001$ ) and 0.4 mm after 39 weeks ( $p < 0.001$ ).<sup>21</sup>

## Conclusions

The review of the literature presented here does not give a definite answer to the question of whether LDD significantly improves the effectiveness of non-surgical treatment of periodontitis. It can be noted that the statistical significance of improvements in the clinical parameters was more often obtained using antibiotics compared to CHX. However, most of the current treatment systems are imperfect, due to the form of administration, and the mode and time of drug release. One of the disadvantages is also the price of preparations, which in the absence of high predictability of treatment is a problem for both the patient and the doctor.

Locally delivered drugs seem to be a good solution for the causal treatment of periodontitis, and work on improving carriers and the use of medicinal substances should be continued. Bisphosphonates have been tested as osteoclasts and binding calcium inhibitors,<sup>44</sup> probiotics as organisms that restore bacterial balance in periodontal pockets,<sup>45</sup> as well as new carriers based on liotropic liquid crystal systems that persist in pockets for over a week.<sup>46</sup> Drugs used in periodontal pockets in many cases help to avoid the general antibiotic therapy with its side effects. At the same time, there is no risk of overdose or overuse, as the concept of a subgingival application is still only a supplement to traditional non-surgical treatment.

**Table 6.** List of studies evaluating the efficacy of 25% metronidazole gel (Elyzol)

Author	Assessed groups	Time of observation	Results		p-value	
			test group	control group		
Kadkhoda et al. 2012 <sup>43</sup>	20 patients test group – SRP+Elyzol® control group – SRP assessed: PD, CAL	6 weeks 12 weeks	PD [mm]	baseline: 6.09 ±1.13	6.30 ±1.55	0.580
				after 6 weeks: 3.39 ±0.98	4.04 ±1.21	0.002
				after 12 weeks: 3.02 ±0.91	3.76 ±1.21	0.001
			CAL [mm]	baseline: 5.17 ±1.43	5.61 ±2.02	
				after 6 weeks: 7.20 ±1.75	7.43 ±2.44	0.078
				after 12 weeks: 7.72 ±1.89	7.83 ±2.51	
Pandit et al. 2013 <sup>28</sup>	20 patients test group – SRP+Elyzol® control group – SRP assessed: PD, CAL	1 month 3 months	PD [mm]	baseline: 6.80 ± 1.00	6.25 ±0.91	0.200
				after 1 month: 5.10 ±1.02	5.30 ±0.80	0.490
				after 3 months: 4.10 ±0.91	4.60 ±0.82	0.070
			CAL [mm]	baseline: 6.60 ±1.99	6.65 ±1.75	0.860
				after 1 month: 5.45 ±1.65	5.90 ±1.43	0.070
				after 3 months: 4.60 ±1.76	4.95 ±1.65	0.200

Data presented as mean ± standard deviation (SD). SRP – scaling/root planing; PD – pocket depth; CAL – clinical attachment level; NS – nonsignificant.

## References

- Górska R, Pietruska M, Dembowska E, Wysokińska-Miszczuk J, Włosowicz M, Konopka T. Prevalence of periodontal diseases in 35–44-year-olds in large urban agglomerations [in Polish]. *Dent Med Probl.* 2012;49(1):19–27.
- Goodson JM, Cugini MA, Kent RL, et al. Multicenter evaluation of tetracycline fiber therapy: I. Experimental design, methods and baseline data. *J Periodontol Res.* 1991;26(4):361–370.
- Brecx MC, Liechti T, Widmer J, Gehr P, Lang NP. Histological and clinical parameters of human gingiva following 3 weeks of chemical (chlorhexidine) or mechanical plaque control. *J Clin Periodontol.* 1989;16(3):150–155.
- Kornman KS. Controlled-release local delivery antimicrobials in periodontics: Prospects for the future. *J Periodontol.* 1993;64(8 Suppl):782–791.
- Gaffar A, Afflitto J, Nabi N. Chemical agents for the control of plaque and plaque microflora: An overview. *Eur J Oral Sci.* 1997;105(5 Pt 2):502–507.
- Kampf G. Acquired resistance to chlorhexidine: Is it time to establish an “antiseptic stewardship” initiative? *J Hosp Infect.* 2016;94(3):213–227.
- Kulik EM, Waltimo T, Weiger R, et al. Development of resistance of *mutans streptococci* and *Porphyromonas gingivalis* to chlorhexidine digluconate and amine fluoride / stannous fluoride-containing mouthrinses, in vitro. *Clin Oral Investig.* 2015;19(6):1547–1553.
- Soskolne WA, Chajek T, Flashner M, et al. An in vivo study of the chlorhexidine release profile of the PerioChip® in the gingival crevicular fluid, plasma and urine. *J Clin Periodontol.* 1998;25(12):1017–1021.
- Verma A, Sanghi S, Grover D, Aggarwal S, Gupta R, Pandit N. Effect of insertion of xanthan-based chlorhexidine gel in the maintenance phase following the treatment of chronic periodontitis. *J Indian Soc Periodontol.* 2012;16(3):381–385.
- Sakellari D, Ioannidis I, Antoniadou M, Slini T, Konstantinidis A. Clinical and microbiological effects of adjunctive, locally delivered chlorhexidine on patients with chronic periodontitis. *J Int Acad Periodontol.* 2010;12(1):20–26.
- Medaiah S, Srinivas M, Melath A, Girish S, Polepalle T, Dasari AB. Chlorhexidine chip in the treatment of chronic periodontitis: A clinical study. *J Clin Diagn Res.* 2014;8(6):ZC22–25.
- Kumar AJ, Ramesh Reddy BV, Chava VK. Effect of chlorhexidine chip in the treatment of chronic periodontitis. *J Nat Sci Biol Med.* 2014;5(2):268–272.
- Pattnaik S, Anand N, Chandrasekaran SC, Chandrashekar L, Mahalakshmi K, Satpathy A. Clinical and antimicrobial efficacy of a controlled-release device containing chlorhexidine in the treatment of chronic periodontitis. *Eur J Clin Microbiol Infect Dis.* 2015;34(10):2103–2110.
- Lecic J, Cakic S, Janjic Pavlovic O, et al. Different methods for subgingival application of chlorhexidine in the treatment of patients with chronic periodontitis. *Acta Odontol Scand.* 2016;74(6):502–507.
- Kranti K, Hema S, Sameer Z. Clinical evaluation of topical subgingival application of biodegradable xanthan-based 1.5% chlorhexidine gel for treatment of periodontal pockets. *JADR.* 2010;1:47–54.
- Matesanz P, Herrera D, Echeverría A, O'Connor A, González I, Sanz M. A randomized clinical trial on the clinical and microbiological efficacy of a xanthan gel with chlorhexidine for subgingival use. *Clin Oral Investig.* 2013;17(1):55–66.
- Chauhan AS, Bains VK, Gupta V, Singh GP, Patil SS. Comparative analysis of hyaluronan gel and xanthan-based chlorhexidine gel, as adjunct to scaling and root planing with scaling and root planing alone in the treatment of chronic periodontitis: A preliminary study. *Contemp Clin Dent.* 2013;4(1):54–61.
- Chitsazi MT, Kashefimehr A, Pourabbas R, Shirmohammadi A, Ghasemi Barghi V, Daghigh Azar B. Efficacy of subgingival application of xanthan-based chlorhexidine gel adjunctive to full-mouth root planing assessed by real-time PCR: A microbiologic and clinical study. *J Dent Res Dent Clin Dent Prospects.* 2013;7(2):95–101.
- Jain M, Dave D, Jain P, Manohar B, Yadav B, Shetty N. Efficacy of xanthan-based chlorhexidine gel as an adjunct to scaling and root planing in treatment of the chronic periodontitis. *J Indian Soc Periodontol.* 2013;17(4):439–443.
- Phogat M, Rana T, Prasad N, Baiju CS. Comparative evaluation of subgingivally delivered xanthan-based chlorhexidine gel and herbal extract gel in the treatment of chronic periodontitis. *J Indian Soc Periodontol.* 2014;18(2):172–177.
- Bonito AJ, Lux L, Lohr KN. Impact of local adjuncts to scaling and root planing in periodontal disease therapy: A systematic review. *J Periodontol.* 2005;76(8):1227–1236.
- Markiewicz Z, Kwiatkowski ZA. *Bacteria, Antibiotics, Drug Resistance* [in Polish]. Warszawa, Poland: PWN; 2012.
- Chopra I, Roberts M. Tetracycline antibiotics: Mode of action, applications, molecular biology, and epidemiology of bacterial resistance. *Microbiol Mol Biol Rev.* 2001;65(2):232–260.
- Schnappinger D, Hellen W. Tetracyclines: Antibiotic action, uptake and resistance mechanisms. *Arch Microbiol.* 1996;165(6):359–369.
- Tabenski L, Moder D, Cieplik F, et al. Antimicrobial photodynamic therapy vs local minocycline in addition to non-surgical therapy of deep periodontal pockets: A controlled randomized clinical trial. *Clin Oral Investig.* 2017;21(7):2253–2264.
- Killeen A, Harn J, Erickson L, Yu F, Reinhardt R. Local minocycline effect on inflammation and clinical attachment during periodontal maintenance: Randomized clinical trial. *J Periodontol.* 2016;87(10):1149–1157.
- Aboelsaad N, Ghandour R, Abiad R. Clinical efficacy of local delivered minocycline in the treatment of chronic periodontitis smoker patients. *J Dent Oral Health.* 2014;1:1–5.
- Pandit N, Dahiya R, Gupta R, Bali D, Kathuria A. Comparative evaluation of locally delivered minocycline and metronidazole in the treatment of periodontitis. *Contemp Clin Dent.* 2013;4(1):48–53.
- Sweatha Ch, Srikanth Ch, Babu M. A comparative study of the effect of minocycline microspheres as an adjunct to scaling and root planing versus scaling and root planing alone in the treatment of chronic periodontitis. *Int J Recent Res.* 2015;6(4):3540–3550.
- Ahamed S, Jalaluddin M, Khalid I, Moon N, Shaf TK, Ali FM. The use of controlled release locally delivered 10% doxycycline hyclate gel as an adjunct to scaling and root planing in the treatment of chronic periodontitis: Clinical and microbiological results. *J Contemp Dent Pract.* 2013;14(6):1080–1086.
- Javali MA, Vandana KL. A comparative evaluation of atrigel delivery system (10% doxycycline hyclate) Atridox with scaling and root planing and combination therapy in treatment of periodontitis: A clinical study. *J Indian Soc Periodontol.* 2012;16(1):43–48.
- Al Hulami H, Babay N, Awartani F, Anil S. The effect of locally delivered doxycycline as an adjunctive therapy to scaling and root planing in smokers. *Saudi Dent J.* 2011;23(3):143–148.
- Deo V, Ansari S, Mandia S, Bhongade M. Therapeutic efficacy of subgingivally delivered doxycycline hyclate as an adjunct to non-surgical treatment of chronic periodontitis. *J Oral Maxillofac Res.* 2011;2(1):e3.
- Sandhya YP, Prabhuji ML, Chandra RV. Comparative evaluation of the efficacy of 10% doxycycline hyclate in the periodontal treatment of smokers: A clinical and microbiological study. *Oral Health Prev Dent.* 2011;9(1):59–65.
- Yadav SK, Khan G, Mishra B. Advances in patents related to intrapocket technology for the management of periodontitis. *Recent Pat Drug Deliv Formul.* 2015;9(2):129–145.
- Green J, Schotland S, Stauber DJ, Kleeman CR, Clemens TL. Cell-matrix interaction in bone: Type I collagen modulates signal transduction in osteoblast-like cells. *Am J Physiol.* 1995;268(5 Pt 1):1090–1103.
- Sachdeva S, Agarwal V. Evaluation of commercially available biodegradable tetracycline fiber therapy in chronic periodontitis. *J Indian Soc Periodontol.* 2011;15(2):130–134.
- Dodwad V, Ahuja S, Kukreja BJ. Effect of locally delivered tetracycline hydrochloride as an adjunct to scaling and root planing on Hba1c, C-reactive protein, and lipid profile in type 2 diabetes: A clinico-biochemical study. *Contemp Clin Dent.* 2012;3(2):150–154.
- Sinha S, Kumar S, Dagli N, Dagli RJ. Effect of tetracycline HCl in the treatment of chronic periodontitis: A clinical study. *J Int Soc Prev Community Dent.* 2014;4(3):149–153.
- Khan FY, Jan SM, Mushtaq M. Clinical utility of locally delivered collagen-based biodegradable tetracycline fibers in periodontal therapy: An in vivo study. *J Investig Clin Dent.* 2015;6(4):307–312.

41. Nadig PS, Shah MA. Tetracycline as local drug delivery in treatment of chronic periodontitis: A systematic review and meta-analysis. *J Indian Soc Periodontol*. 2016;20(6):576–583.
42. Kostowski W, Herman Z. *Pharmacology: Basics of Pharmacotherapy* [in Polish]. Warszawa, Poland: PZWL; 2004.
43. Kadkhoda Z, Rafiei Tari S, Owlia P, Seyyed Zadeh Sabounchei S. Comparison of 1-periodontal indices and cultural *Porphyromonas gingivalis* colony count in aggressive periodontitis patients treated by scaling and root planning with or without metronidazole gel. *J Dent (Tehran)*. 2012;9(1):50–58.
44. Chen J, Chen Q, Hu B, Wang Y, Song J. Effectiveness of alendronate as an adjunct to scaling and root planing in the treatment of periodontitis: A meta-analysis of randomized controlled clinical trials. *J Periodontal Implant Sci*. 2016;46(6):382–395.
45. Teughels W, Newman MG, Coucke W, et al. Guiding periodontal pocket recolonization: A proof of concept. *J Dent Res*. 2007;86(11):1078–1082.
46. Mei L, Huang X, Xie Y, et al. An injectable in situ gel with cubic and hexagonal nanostructures for local treatment of chronic periodontitis. *Drug Deliv*. 2017;24(1):1148–1158.

# Microdontia after chemotherapy in a patient treated for neuroblastoma: Histopathological findings

## Mikrodoncja po chemioterapii u pacjenta leczonego z powodu nerwiaka zarodkowego – badania histopatologiczne

Anna Jodłowska<sup>1,A–D</sup>, Jacek Pająk<sup>2,B,C,E</sup>, Lidia Postek-Stefańska<sup>1,E,F</sup>

<sup>1</sup> Department of Pediatric Dentistry, Medical University of Silesia, Katowice, Poland

<sup>2</sup> Department of Patomorphology and Molecular Diagnostics, Medical University of Silesia, Katowice, Poland

A – research concept and design; B – collection and/or assembly of data; C – data analysis and interpretation; D – writing the article; E – critical revision of the article; F – final approval of the article

Dental and Medical Problems, ISSN 1644-387X (print), ISSN 2300-9020 (online)

*Dent Med Probl.* 2018;55(3):343–349

### Address for correspondence

Anna Jodłowska  
ajodlowska@sum.edu.pl

### Funding sources

Statutory sources (grant No. KNW 1-021/N/7/I).

### Conflict of interest

None declared

Received on July 3, 2018

Reviewed on August 19, 2018

Accepted on September 10, 2018

### Abstract

Microdontia is one of the late effects of antineoplastic therapy in children. This study is based on the comparative histological examination of abnormal, peg-shaped premolars, erupted in a patient treated for neuroblastoma, and of non-affected teeth, extracted in a healthy child. Apart from the size, the teeth vary in tissue morphology. The number of dentinal tubules, dependent on the number of odontoblasts, is smaller in the microdontal sample when observation in the same-sized field of view is conducted. Moreover, the youngest, more than 100-micrometer-thick layer of the microdontal dentin seems to be the secondary dentin, with crispy-shaped tubules and empty spaces between them. No irregular dentin is deposited in the samples of physiologically developed teeth. The structure of cementum is different as well. Unlike regularly shaped premolars, in which typical 2-layer tissue is seen, in sections of microdontal teeth, only acellular tissue with cementoblasts overlying its surface is present. Thorough analysis of drug administration effects, which are visible in microscopic sections, and of time of anticancer treatment could provide insight into the developmental mechanisms of tooth germ formation.

**Key words:** chemotherapy, histopathology, tooth abnormalities, neuroblastoma

**Słowa kluczowe:** chemioterapia, histopatologia, zaburzenia zębowe, nerwiak zarodkowy

### DOI

10.17219/dmp/95028

### Copyright

© 2018 by Wrocław Medical University  
and Polish Dental Society

This is an article distributed under the terms of the  
Creative Commons Attribution Non-Commercial License  
(<http://creativecommons.org/licenses/by-nc-nd/4.0/>)

## Introduction

Numerous clinical studies have shown changes in dental morphology after chemotherapy and head radiotherapy.<sup>1–7</sup> When used together, it is difficult to decide which of these treatment modalities is responsible for developmental anomalies. According to the literature, chemotherapy mainly induces qualitative dental tissue changes, whereas body irradiation can produce both qualitative and quantitative disturbances in enamel and dentin formation.<sup>8</sup> However, some literature reports based on the examination of patients treated only with multi-agent chemotherapy showed severely altered dental development as well.<sup>4,9,10</sup> Many experimental histological studies have demonstrated impaired and delayed tooth development after administration of different chemotherapeutics used for human treatment.<sup>4,11–17</sup> The follow-up in animals was not long enough to show all histological changes. The animal model is not similar to the human model, which prevents depicting quantitative developmental abnormalities.<sup>16,17</sup> However, analysis of histological experimental findings can be helpful in predicting the effect of chemotherapy. There are different types of toxic effects posed by chemotherapy. It can disturb DNA synthesis or replication and RNA transcription, and thus interfere with the proliferating cell cycle. It can also have an impact on cytoplasmic metabolism in the form of disturbed transport mechanisms.<sup>17,18</sup>

The most common anticancer agents used in pediatric oncology are vincristine (VCR), cyclophosphamide (CPX) and actinomycin. Their cytotoxic mechanisms have been widely demonstrated on animal models. Vincristine – a vinca-alkaloid, the so-called microtubule poison – causes mitotic cessation in the metaphase or death of actively proliferating germinative pulp cells, including preodontoblasts. It also changes the function of mature odontoblasts.<sup>12–14</sup> The interrupted transport from the rough endoplasmic reticulum to the Golgi complex caused by VCR in ameloblasts, odontoblasts and cementoblasts is well-known side effect.<sup>19,20</sup> Cyclophosphamide – an alkylating substance – cross-links the guanine bases in DNA, and thus inhibits cell division or leads to mutations in dentin and enamel precursor cells.<sup>4,11</sup> Actinomycin D is an intercalating agent – an antibiotic that inserts itself into DNA, leading to its damage and subsequent inhibition of RNA and protein synthesis. Even low doses induce damage in young premature cells, while much higher doses can disturb fully developed secretory ameloblasts and odontoblasts.<sup>15</sup> However, the above-mentioned cytotoxic mechanisms were presented following a single drug injection and a short follow-up time, related to animal teeth at late development. The abnormalities described were transient and not severe. Severe dental damage is a long-term side effect and may occur after long-term chemotherapy at early developmental stages.<sup>4,21</sup> Reports based on the histological examination of teeth damaged before the onset of apposition are missing.

## Case report

A male patient at the age of 10 years presented at the Children's Dentistry Outpatient Clinic of the Department of Pediatric Dentistry in Katowice, Poland, for dental evaluation before orthodontic treatment. The intraoral examination revealed no carious lesions and correct oral hygiene. The boy was in the mixed dentition period with only permanent first molars and incisors present. The mandibular primary canines were exfoliated and the permanent successors were ready to erupt, as evidenced by the panoramic radiograph delivered. The germs of permanent first premolars seemed to be absent, which was the reason the orthodontist recommended to remove all the deciduous first molars. Careful analysis revealed that small mineralized structures between the roots of the primary first molars were likely to exist. It was found from a medical history that the patient had received anticancer treatment between 12 months and 2 years of age. The boy received multi-agent chemotherapy with, among other things, VCR, CPX and actinomycin. After exfoliating the mandibular primary first molars and after taking a panoramic radiograph, a diagnosis of microdontia was established (Fig. 1). Finally, a removal of the maxillary primary first molars was planned. At the age of 13 years, the patient returned to our clinic with a recommendation for the extraction of partially erupted microdontal teeth (Fig. 2). The teeth obtained were then fixed with 10% neutral buffered formalin and sent for histological examination. For a comparative study, the same procedure was performed on 4 fully erupted, non-affected permanent first premolars, removed for orthodontic reasons in a 14-year-old patient with a non-contributory medical history.

After specimen delivery to the Department of Pathomorphology (Medical University of Silesia, Katowice, Poland), a few-month decalcification procedure using a TBD-2 Decalcifier (Fisher Scientific, Hampton, USA) was performed. Subsequently, 4-micrometer-thick paraffin-embedded serial longitudinal sections were prepared. In order to better show discreet dental structures, the specimens were counterstained according to hematoxylin

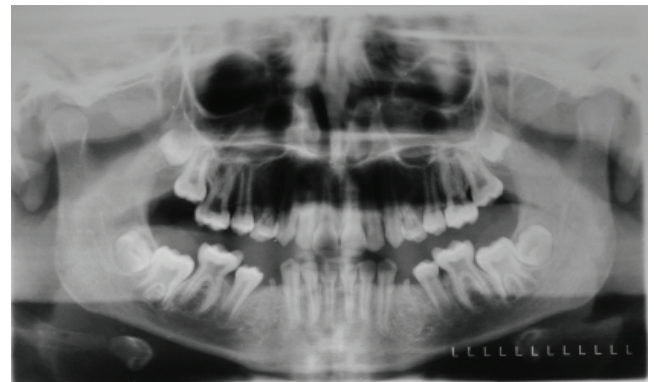

Fig. 1. Panoramic radiograph in the 11-year-old patient. Unerupted microdontal permanent first premolars are clearly visible



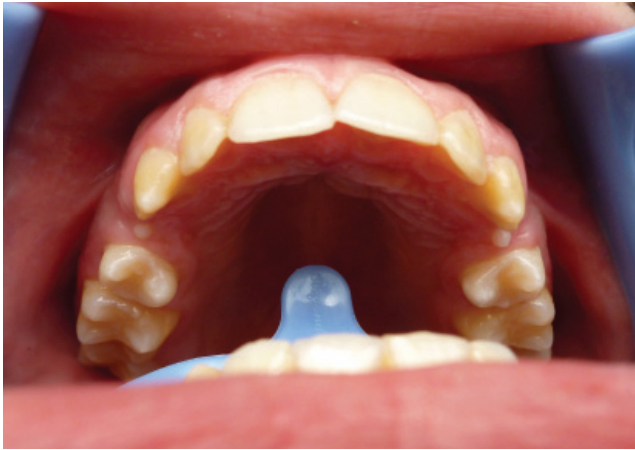

Fig. 2. Clinical image of the upper dental arch of the patient aged 13 years. Partially erupted maxillary first premolars are shown

and eosin (H&E), periodic acid-Schiff (PAS) and Masson's trichrome protocols. The microscopic images were taken at  $\times 40$ – $400$  magnification, using an Olympus BX-51 microscope (Olympus Corporation, Tokyo, Japan) and dedicated cellSens software (Fig. 3–10).

Both the well-shaped and microdontal teeth had their roots fully developed. The microdontal sample was approx. 20 times smaller than its normal counterpart. The results obtained are presented in the Figures, showing the histological structure of the dentin, pulp tissue and cementum. The enamel tissue was destroyed during the decalcification procedure; therefore, it is not visible in the photographs.

The dentine appears as a fibrous compact structure with long tubules passing through its entire width. The number of tubules, dependent on the number of odontoblasts, is smaller in microdontal teeth when observation in the same-sized field of view is conducted. The newly formed tissue adjacent to the pulp, which is termed predentin,

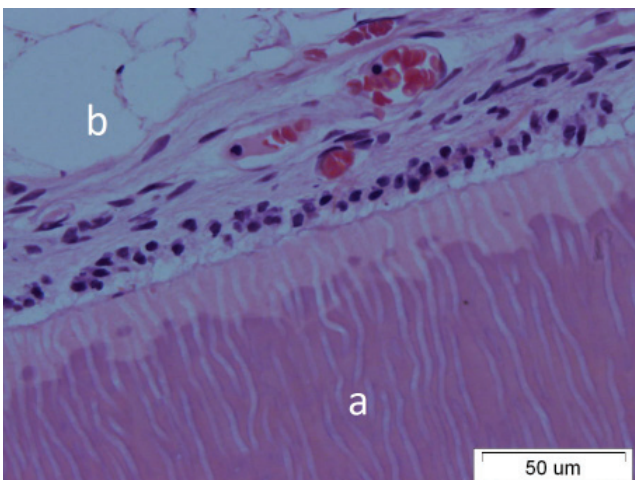


Fig. 3. Microdontal maxillary right first premolar. Dentinal tubules: a – dentin with a decreased number of tubules and brightly stained pre-dentin; b – pulp with darkly stained nuclei of odontoblasts, vessels with blood cells and adipocytes of adipose tissue (H&E,  $\times 400$  magnification) H&E – hematoxylin and eosin.




Fig. 4. Non-affected mandibular left first premolar. Dentinal tubules at the same magnification: a – dentin with a high number of tubules and slightly marked pre-dentin; b – pulp with crowded odontoblasts and star-shaped cells of fibrous tissue (H&E,  $\times 400$  magnification) H&E – hematoxylin and eosin.




Fig. 5A. Microdontal mandibular left first premolar. Irregular secondary dentin-like tissue with a thickness of approx.  $100\ \mu\text{m}$ : a – crispy tubules in a decreased number; b – regular tubular pattern of primary dentin (Masson's trichrome,  $\times 200$  magnification)






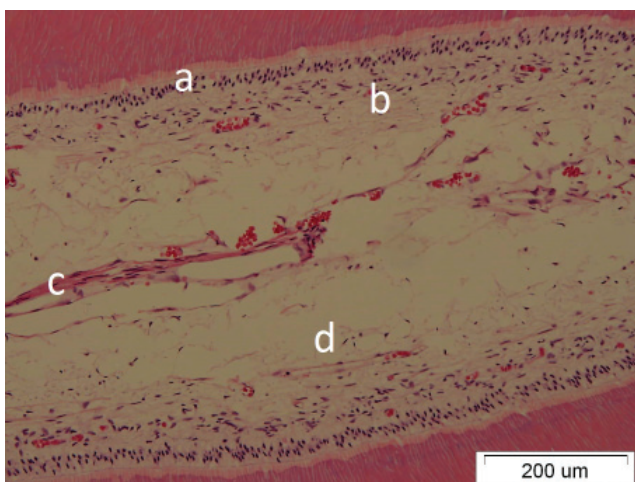
Fig. 5B. Microdontal mandibular left first premolar. Stratum of irregular secondary dentin from Fig. 5A at a higher magnification: the line marks the border between the first deposited primary dentin and irregular secondary tissue (H&E,  $\times 400$  magnification) H&E – hematoxylin and eosin.



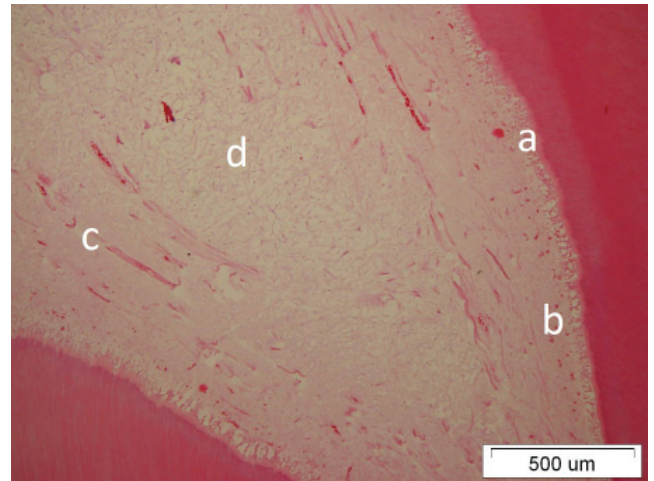
**Fig. 6A.** Non-affected mandibular left first premolar. Properly built primary tubular dentin without traces of secondary tissue: a – regular pattern of parallel dentinal tubules; b – a multilayer-looking line of odontoblasts; c – star-shaped germinative pulp cells (Masson's trichrome, magnification  $\times 200$ )



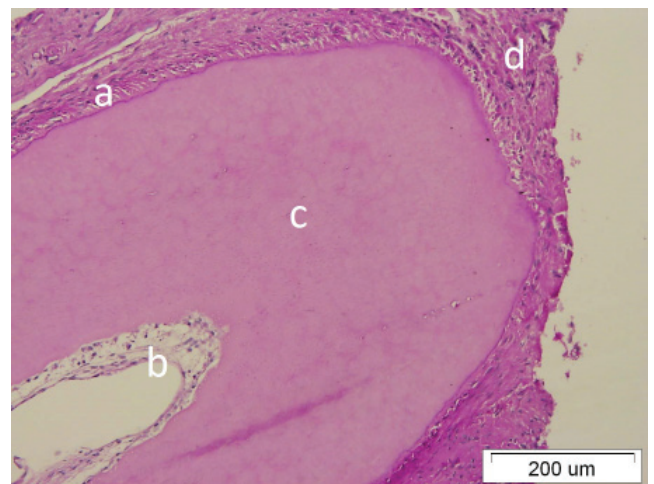
**Fig. 6B.** Non-affected mandibular left first premolar. Primary dentin from Fig. 6A at a higher magnification: a – inside dentin tubules, blue-stained unmyelinated nerve fibers, originating from pulp; b – odontoblasts (Masson's trichrome, magnification  $\times 400$ )



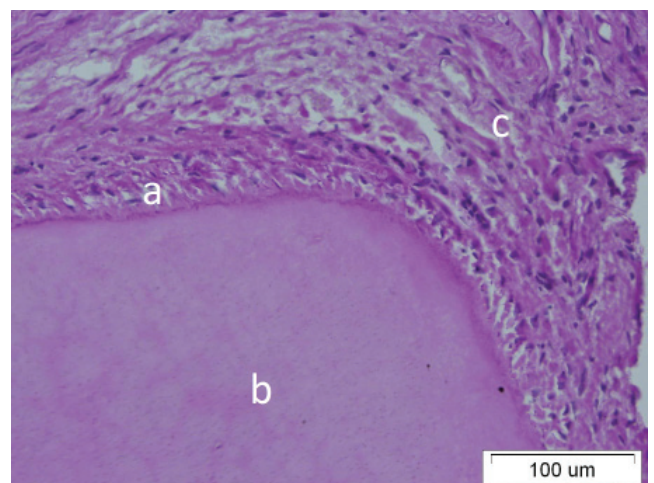
**Fig. 7.** Microdontal maxillary right first premolar. Dental pulp: a – odontoblasts – dentin producing cells; b – cell-rich zone; c – collagen fibers adjacent to blood vessels; d – adipocytes (H&E, magnification  $\times 100$ ) H&E – hematoxylin and eosin.



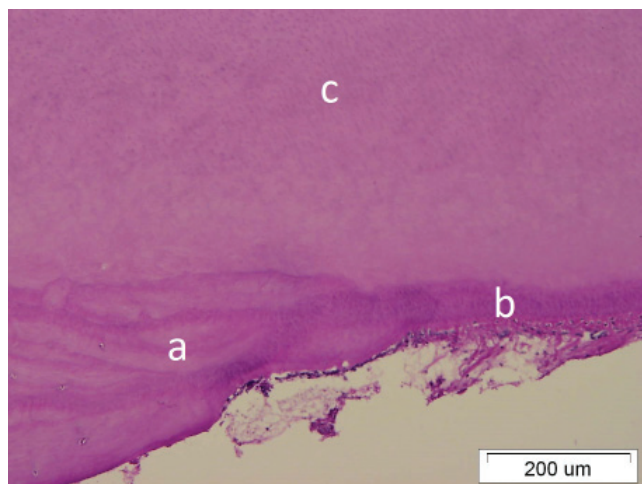
**Fig. 8.** Non-affected mandibular left first premolar. Dental pulp: a – odontoblasts; b – cell-rich zone; c – collagen fibers; d – adipose tissue (H&E, magnification  $\times 40$ ) H&E – hematoxylin and eosin.



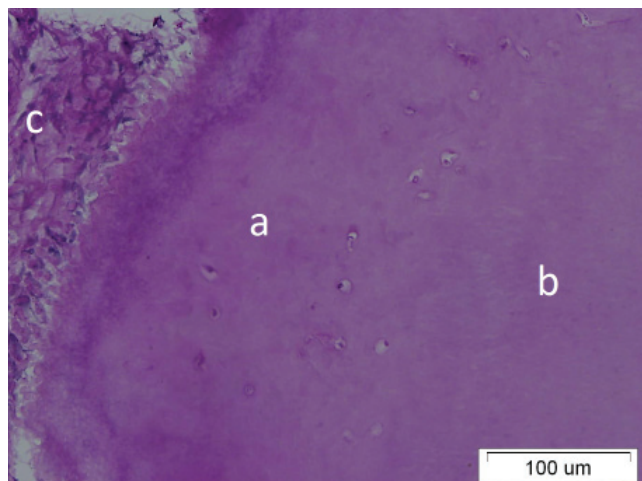
**Fig. 9A.** Microdontal maxillary right first premolar. Cementum in the apex region: a – 1 layer of acellular fibrous cementum; b – pulp chamber of a small volume; c – tubular dentin; d – periodontal ligament (PAS, magnification  $\times 100$ ) PAS – periodic acid-Schiff.



**Fig. 9B.** Microdontal maxillary right first premolar. Part of cementum from Fig. 9A at a higher magnification: a – a thin layer of acellular fibrous cementum covered with cementoblasts; b – tubular dentin; c – periodontal ligament with numerous collagen fibers and fibroblasts (PAS, magnification  $\times 200$ ) PAS – periodic acid-Schiff.



**Fig. 10A.** Non-affected maxillary right first premolar. Cementum in the apical third of the root: a – typical multilayer cellular cementum with cementocytes embedded inside hard tissue; b – acellular fibrous cementum covered with cementoblasts; c – dentin with obliquely cut tubules (PAS, magnification  $\times 100$ )  
PAS – periodic acid-Schiff.



**Fig. 10B.** Non-affected maxillary right first premolar. Apical cementum at a higher magnification: a – cellular cementum with cementocytes embedded inside hard tissue covered with the stratum of acellular cementum; b – dentin; c – periodontal ligament (PAS, magnification  $\times 200$ )  
PAS – periodic acid-Schiff.

presents a brighter color in each stain due to lower mineral content. Inside the predentin, the first darkly stained nuclei of calcification are seen (Fig. 3,4). The youngest, more than 100-micrometer-thick layer of the microdontal dentin seems to be the secondary dentin, with crispy-shaped tubules and empty spaces between them (Fig. 5A,5B). No irregular dentin is deposited in the sample of the physiologically developed tooth (Fig. 6A,6B).

The pulp cavity filled with loose connective tissue contains all the layers proper for the dental pulp in the 2 types of teeth (Fig. 7,8). The multilayer-looking line of odontoblasts in the crown region, which are more crowded in pulp extensions, changes when passing through the root canal, from initially cuboidal to flattened cells present in lower numbers. The pulp of the microdontal teeth var-

ies in the number of odontoblasts, as evidenced in the photographs showing dentin tubules (Fig. 3,4). Thin unmyelinated nerve fibers originating from the cell-free zone are visible between odontoblasts and penetrate into the tubules of the pulp-adjacent dentin (Fig. 6B). Below dentin-producing cells, the properly built cell-free zone of Weil, the cell-rich zone and the pulp core are situated. The pulp core consists of vascular fibrous tissue with star-shaped cells, shown in a higher magnification in Masson's trichrome stain (Fig. 6A).

The structure of cementum differs depending on the type of tooth. In the sections of regular-shaped premolars, typical 2-layer tissue is seen. Internal acellular fiber cementum is covered with multilayer tissue with cementocytes embedded in its structure in the apical third of the root. No traces of cellular cementum in the interradicular area were detected. Externally, the stratum of cementoblasts with dark blue nuclei is noted. In some sections, the layers of cementum are inverted (Fig. 10A,10B). Otherwise, in microdontal teeth, only acellular tissue with cementoblasts overlying its surface is present. Several layers of cellular cementum in the upper premolar were found atypically situated in the cervical part of the root, covering only its one surface (Fig. 9A,9B).

## Discussion

Development of permanent dentition is poorly understood in comparison with primary teeth due to the limitations connected with their postnatal formation.<sup>22</sup> There is no accurate information regarding the duration of particular developmental stages.

Thorough analysis of anticancer treatment time in relation to the type of tooth abnormality could make it possible to take a look at the mechanisms of odontogenesis.<sup>21</sup> Some histological studies in which the impact of cytotoxic drugs on dentinogenesis is presented may be found in the literature. Polarized microscopy appeared to be helpful in showing regular incremental lines in the dentin, corresponding to intravenous chemotherapy administration, although the tooth morphology was not changed.<sup>23,24</sup> The effects of tooth germ impairment occurring before the appositional growth of dental tissues are not well-documented. Medical sources explain that microdontia succeeds tooth germ injury in the bud stage.<sup>25,26</sup> The bud stage is described as critical for normal tooth development. Experimental studies have shown that explants from this proliferation stage continue to grow in tissue culture.<sup>27</sup> In spite of the fact that the tooth morphology pattern is dependent on appropriate gene expression, cytotoxic germ cell injury in an early developmental stage may lead to changes in the programmed developmental model. Among the different theories, a statement may be found that the dental shape is likely to be determined at the tooth initiation, when the epithelium and ectomesen-

chyme are the only germ components.<sup>28</sup> Thus, in the case studied, the cytotoxic treatment altered the programmed pattern of premolar formation, leading to the development of the peg-shaped tooth. The small size of first premolars only and the regular morphology of second premolars, developing 7–8 months later, indicates that the first bands of cells at the initiation and bud stage are not prone to injury. At the bell stage, by contrast, tooth shape formation, the so-called morphodifferentiation, is observed.<sup>27,28</sup> Thus, the duration of the early developmental stages seems to be relatively long compared to the bell stage. Damage can also take place at the bell stage, for example at its early phase. The beginning of apposition for permanent first premolars is reported to occur at the age of 1 year and 3 months up to 2 years.<sup>29</sup> The treatment was initiated when the patient turned 12 months and was finished at the age of 2 years, shortly before mineralization. In the authors' previous research, the majority of patients with microdontia started their antineoplastic treatment before or at the expected time of the onset of apposition.<sup>21</sup> This may be the evidence of a short period within the bell stage when the tooth shape is being determined.

The peg-shaped tooth is either small-sized or has no bicuspid features. Histological observations confirmed a narrow pulp cavity with a small number of odontoblasts, resulting in altered dentin appearance. In a study on rat incisors, 24 h after injection of VCR, almost all preodontoblasts were destroyed. And although after the next 24 h, newly formed vital germinative cells appeared and severely disturbed preodontoblasts were seen incisally, delayed tooth growth was observed. Moreover, the authors observed formation of the irregular dentin, originating from odontoblasts with altered secretion ability due to cytotoxic impairment of functional odontoblasts. The mentioned odontoblasts were not labelled, and thus they could not originate from the proliferative pool of the pulp.<sup>12</sup> Their function was impaired rather as a result of damaged microtubule proteins – important transport cytoplasmic structures.<sup>19,20</sup> Immediate lethal and sublethal effects on odontoblasts, non-dividing cells, has also been observed in other studies. Dentinal niche and irregular predentin formation were seen as a result of disturbed matrix synthesis and secretion. The authors also noted that the reparative activity of undifferentiated pulp cells resulted in predentinoid or osteodentin tissue production, corresponding to the area of the injured odontoblasts.<sup>13,14</sup> In the histological images, an incremental line between the dentin formed before and after VCR administration is additionally present. The irregular osteodentin is situated pulpally to the line.<sup>13</sup> In the case of our patient, VCR and other administered drugs severely destroyed undifferentiated germinative cells, to such an extent that development of physiologically-sized teeth appeared to be impossible. The abnormal shape was obviously due to the small size. A decreased number of dental papilla cells resulted in poor regeneration of functional onto-

blasts. Although they ensured regular dentin formation, the number of dentinal tubules in the field of view was smaller compared to the control.

Interestingly, the present study showed the presence of a dentin layer resembling the secondary dentin in all the microdontal samples. Many clinical studies have demonstrated alterations in the root developmental pattern after anticancer therapy. A premature apical closure with a decreased root-crown ratio is one of the disturbances described.<sup>1–3,5,30</sup> This anomaly usually appears when anticancer therapy takes place in the period of root formation. Our patient received chemotherapy a long time before this stage. But the early development of the microdontal crown was probably followed by short-time root formation. Before the extraction of the control teeth, their development had just finished and the secondary dentin could not be observed. After the early finished root development, odontoblasts of the microdontal teeth started secondary dentin production, although the teeth had been removed 1 year before the extraction of the control teeth. The secondary dentin is secreted very slowly; therefore, it is not possible to estimate the time needed for its formation.

Taking into account the above-mentioned findings, it is difficult to understand the differences in the cementum morphology shown in the histological images. The early developed microdontal teeth show no traces of cellular tissue, well-developed in the control group. It is known that the cellular cementum is mostly formed after the tooth reaches the occlusal surface of the opposite tooth. Wider research is needed to explain whether the reason is the severe impairment of ectomesenchymal cells of the dental sac following anticancer therapy. Takuma et al. used a transmission electron microscope to analyze the reaction of the cellular components of cementoblasts after VCR administration.<sup>19</sup> Based on an observation of a growing apical area of the rat first molar roots, the authors demonstrated the damage of microtubules, and thus transport impairment. However, high dose levels were used in the experiment and reliable results were not obtained.<sup>19</sup>

The dental pulp morphology, besides the shape and size, is similar for the 2 groups of teeth. The number of odontoblasts in the microdontal sample seems to be smaller; thus, dentin formative cells line the cavity in 1, almost regular layer. Therefore, the basement membrane seen between odontoblasts and the newly formed predentin is well-marked. Otherwise, rich in odontoblasts, the control pulp exhibits its multilayer appearance, although dentin precursor cells form a 1-stratum lining. A large number of dentinal tubules in the control teeth compared to the small number in the microdontal sample confirms this observation.

A comparative histological examination of abnormal peg-shaped premolars erupted in a patient treated for neuroblastoma and non-affected teeth extracted in a healthy child showed differences in tissue morphology.

Unlike the regular-shaped premolars, the microdental sections are characterized by the presence of an irregular dentin layer, a relatively smaller number of odontoblasts and the absence of cellular tissue in the cementum morphology. The anticancer therapy was initiated shortly before the onset of mineralization, at the early stage of first premolar development. Thorough analysis of drug administration effects visible in microscopic sections and of time of anticancer treatment can provide insight into the developmental mechanisms of tooth germ formation.

## References

- Avşar A, Darka O, Pinarli G. Long-term effects of chemotherapy on caries formation, dental development and salivary factors in childhood cancer survivors. *Oral Surg Oral Med Oral Pathol Oral Radiol Endod.* 2007;104(3):781–789.
- Marec-Berard P, Chauv-Bodard AG, Lagrange H, Azzi D, Gourmet R, Bergeron C. Long-term effects of chemotherapy on dental status in children treated for nephroblastoma. *Pediatr Hematol Oncol.* 2005;22(7):581–588.
- Höittä P, Alaluusua S, Saarinen-Pihkala UM, Peltola J, Hovi L. Agenesis and microdontia of permanent teeth as late adverse effects after stem cell transplantation in young children. *Cancer.* 2005;103(1):181–190.
- Minicucci EM, Lopes LF, Crocci AJ. Dental abnormalities in children after chemotherapy treatment for acute lymphoid leukemia. *Leuk Res.* 2003;27(1):45–50.
- Höittä P, Alaluusua S, Saarinen-Pihkala UM, Wolf J, Nyström M, Hovi L. Long-term adverse effects on dentition in children with high-dose chemotherapy and autologous stem cell transplantation with or without total body irradiation. *Bone Marrow Transplant.* 2002;29(2):121–127.
- Kaste SC, Hopkins KP, Jenkins JJ. Abnormal odontogenesis in children treated with radiation and chemotherapy: Imaging findings. *AJR Am J Roentgenol.* 1994;162(6):1407–1411.
- Pajari U, Lanning M, Larmas M. Prevalence and location of enamel opacities in children after anti-neoplastic therapy. *Community Dent Oral Epidemiol.* 1988;16(4):222–226.
- Dahllöf G, Rozell B, Forsberg CM, Borgström B. Histologic changes in dental morphology induced by high-dose chemotherapy and total body irradiation. *Oral Surg Oral Med Oral Pathol.* 1994;77(1):56–60.
- Remmers D, Bökkerink JPM, Katsaros C. Microdontia after chemotherapy in a child treated for neuroblastoma. *Orthod Craniofac Res.* 2006;9(4):206–210.
- Kaste SC, Hopkins KP, Bowman LC, et al. Dental abnormalities in children treated for neuroblastoma. *Med Pediatr Oncol.* 1998;30(1):22–27.
- Näsman M, Forsberg CM, Dahllöf G. Long-term dental development in children after treatment for malignant disease. *Eur J Orthod.* 1997;19(2):151–159.
- Stene T, Koppang HS. Autoradiographic investigation of proliferative responses in rat incisor pulp after vincristine administration. *Scand J Dent Res.* 1980;88(2):96–103.
- Stene T. Vincristine's effect on dentinogenesis in rat incisor. *Scand J Dent Res.* 1979;87(1):39–49.
- Stene T. Effect of vincristine on odontoblasts in rat incisors. *Scand J Dent Res.* 1978;86(5):346–356.
- Lyaruu DM, van Duin MA, Bervoets TJM, Wöltgens JH, Bronckers AL. Effects of actinomycin D on developing hamster molar tooth germs in vitro. *Eur J Oral Sci.* 1997;105(1):52–58.
- de Oliveira Nogueira T, Stene T, Koppang HS. Long-term effects of colchicine on dentinogenesis in rat incisors. *Scand J Dent Res.* 1980;88(1):15–21.
- Dahl JE. Influence of doxorubicin on rat incisor mesenchymal cells. *Scand J Dent Res.* 1984;92(1):6–13.
- Goho C. Chemoradiation therapy: Effect on dental development. *Pediatr Dent.* 1993;15(1):6–12.
- Takuma S, Sawada T, Yama S, Yanagisawa T. Ultrastructural changes in the cementoblasts of rat molars after injection of vincristine. *J Dent Res.* 1984;63(9):1108–1115.
- Takuma S, Sawada T, Yanagisawa T. Ultrastructural changes of secreting rat-incisor ameloblasts following administration of vincristine and vinblastine. *J Dent Res.* 1982;61(Spec No):1472–1478.
- Jodłowska A, Postek-Stefańska L, Pietraszewska D, et al. Tooth development in the light of cancer survivors' examination. *J Stoma.* 2016;69:659–666.
- Olley RC, Xavier GM, Seppala M, et al. Expression analysis of candidate genes regulating successional tooth formation in the human embryo. *Front Physiol.* 2014;5:445.
- Macleod RI, Welbury RR, Soames JV. Effects of cytotoxic chemotherapy on dental development. *J R Soc Med.* 1987;80(4):207–209.
- Maguire A, Craft AW, Evans RGB, et al. The long-term effects of treatment on the dental condition of children surviving malignant disease. *Cancer.* 1987;60(10):2570–2575.
- Bath-Balogh M, Fehrenbach MJ. *Illustrated Dental Embryology, Histology, and Anatomy.* Philadelphia, PA: W.B. Saunders Company; 1997:65.
- Fehrenbach MJ. Review of tooth development and associated developmental disturbances. *J Pract Hyg.* 2000;5–6:12–14.
- Kumar GS. *Orban's Oral Histology and Embryology.* 13<sup>th</sup> ed. Gurgaon, India: Elsevier India; 2011:27–38.
- Nanci A. *Ten Cate's Oral Histology. Development, Structure and Function.* 8<sup>th</sup> ed. St. Louis, MO: Mosby; 2012:70–89.
- Cameron AC, Widmer RP. *Handbook of Pediatric Dentistry.* 3<sup>rd</sup> ed. St. Louis, MO: Mosby Elsevier; 2008:458–459.
- Rosenberg SW, Kolodney H, Wong GY, Murphy ML. Altered dental root development in long-term survivors of pediatric acute lymphoblastic leukemia. *Cancer.* 1987;59(9):1640–1648.

Dental  
and Medical Problems

