

# Laparoscopic histological mapping for the determination of the length of aganglionic segment in children with Hirschsprung disease

Bartosz Bogusz<sup>1,A–D</sup>, Małgorzata Smolec-Zamora<sup>1,B,C,E</sup>, Andrzej Zajac<sup>1,B,E</sup>, Adam Mol<sup>2,B,E</sup>, Wojciech Górecki<sup>1,E,F</sup>

<sup>1</sup> Department of Pediatric Surgery, University Children's Hospital, Jagiellonian University Medical College, Kraków, Poland

<sup>2</sup> Department of Pediatric Surgery, University Children's Hospital, Kraków, Poland

A – research concept and design; B – collection and/or assembly of data; C – data analysis and interpretation;

D – writing the article; E – critical revision of the article; F – final approval of the article

Advances in Clinical and Experimental Medicine, ISSN 1899–5276 (print), ISSN 2451–2680 (online)

*Adv Clin Exp Med.* 2021;30(3):233–237

## Address for correspondence

Bartosz Bogusz

E-mail: [bjbart@poczta.onet.pl](mailto:bjbart@poczta.onet.pl)

## Funding sources

None declared

## Conflict of interest

None declared

Received on June 24, 2020

Reviewed on July 7, 2020

Accepted on October 29, 2020

Published online on March 23, 2021

## Abstract

**Background.** Modern approach to the surgical treatment of Hirschsprung's disease (HD) consists in the earliest possible repair and reduction of the number of surgical interventions. Primary one-stage transanal endorectal pull-through (TEPT) technique requires preoperative determination of the length of aganglionic segment. The efficacy of the standard method – contrast enema – is questionable in patients with a poorly defined transitional zone.

**Objectives.** To present the proposed laparoscopic method for the management pathway in patients with HD, in whom the determination of the length of aganglionic segment with contrast enema was not possible.

**Materials and methods.** A retrospective analysis of the diagnostic and therapeutic management employed in 14 patients, from 2 weeks to 55 months of age, with diagnosed HD, treated between January 2013 and May 2020. Laparoscopic histological mapping was performed with the use of 3 laparoscopic ports of 3–5 mm diameter.

**Results.** In all patients, laparoscopic mapping allowed for the determination of the length of aganglionic segment and the mode of surgical treatment. Four children with determined short-segment disease underwent TEPT, while 2 underwent temporary colostomy formation using the Duhamel–Martin–Ikeda method. Five patients with long-segment HD underwent laparoscopic-assisted TEPT. One patient with long-segment disease was treated with a temporary double-barrel colostomy and definitive surgery was performed 3 months later using the Duhamel–Martin–Ikeda method. In 2 patients with an initial diagnosis of HD established using current diagnostic pathway, HD pathology was later excluded based on the results of laparoscopic mapping and repeat rectal suction biopsy. No complications related to the laparoscopic procedure were identified.

**Conclusions.** The method of laparoscopic mapping is effective in the determination of the length of aganglionic segment in children with diagnosed HD. In doubtful cases, it can be the preferred option in establishing the final mode of surgical treatment.

**Key words:** laparoscopy, biopsy, Hirschsprung

## Cite as

Bogusz B, Smolec-Zamora M, Zajac A, Mol A, Górecki W. Laparoscopic histological mapping for the determination of the length of aganglionic segment in children with Hirschsprung disease. *Adv Clin Exp Med.* 2021;30(3):233–237. doi:10.17219/acem/129575

## DOI

10.17219/acem/129575

## Copyright

© 2021 by Wrocław Medical University

This is an article distributed under the terms of the Creative Commons Attribution 3.0 Unported (CC BY 3.0) (<https://creativecommons.org/licenses/by/3.0/>)

## Background

The modern approach to the definite surgical treatment of Hirschsprung's disease (HD) focuses on the earliest possible repair, and reducing the number of surgical interventions. Total transanal surgery for HD – transanal endorectal pull-through (TEPT) – represents the latest development in the concept of minimally invasive surgery for HD.<sup>1,2</sup> The feasibility, safety and efficacy of this approach has been established.<sup>3–5</sup> Nevertheless, it depends on the length of the aganglionic segment, as well as the general condition of the patient. The success of surgical correction of HD using the TEPT technique requires precise determination of the length of aganglionic segment before the operation. The efficacy and sensitivity of the standard method used for this purpose – contrast enema – is questionable, especially in the group of patients in whom, because of an early presentation of the disease, bowel distension above the transitional zone is not well demarcated. On the other hand, the lack of visible transitional zone in older children with confirmed HD does not necessarily represent long-segment disease.<sup>6,7</sup> The lack of precise determination of the length of aganglionic segment before operation using the TEPT technique can result in an unwanted intraoperative change of therapeutic strategy.

## Objectives

Following the idea of laparoscopic-assisted TEPT, presented by Georgeson,<sup>8–10</sup> the aim of this study was to present the current procedure employed in our institution for the determination of the length of aganglionic segment, as well as surgical treatment mode in patients with diagnosed HD, in whom the determination of the length of aganglionic segment was not possible with the use of contrast enema.

## Materials and methods

Between January 2013 and May 2020, HD was diagnosed in 56 patients treated in the Department of Pediatric Surgery of the University Children's Hospital in Kraków, Poland. The diagnostic scheme routinely employed in patients admitted with suspected HD included: plain abdominal X-ray, anorectal manometry and rectal suction biopsy for acetylcholinesterase (AChE) histochemical staining and hematoxylin & eosin (H&E) staining. In cases of uncertain results from the abovementioned studies, calretinin immunostaining of rectal biopsy was performed. Barium contrast enema was employed in order to determine the length of aganglionic segment (Fig. 1). In the studied group, contrast enema failed to show the length

of aganglionic segment in 14 children with HD diagnosed using the aforementioned diagnostic pathway. These patients were qualified for laparoscopic mapping. The mode of further treatment including, if possible, consecutive one-stage surgical treatment during the same procedure, depended on the results of histopathological evaluation of seromuscular intestinal biopsies. The age of patients on admission ranged from 2 weeks to 55 months.

## Technique of laparoscopic mapping

Patients were placed in supine position. The surgeon stood on the right side of the patient, near the head. Pneumoperitoneum was established using the Hasson technique. The applied intraabdominal pressure was 6–10 mm Hg. A 5-mm, 30° scope was introduced through the umbilical port. Two 3-mm or 5-mm working ports were introduced bilaterally at the level of the umbilicus, lateral to the mid-clavicular lines, or in the right epigastric region and right hypogastric area. Seromuscular intestinal biopsies were obtained using 3-mm or 5-mm instruments. If the transitional zone was visualized, biopsies were taken with endoshears distally and proximally to the suspected level of normal innervation of the intestine in order to confirm the diagnosis and length of aganglionic segment. In cases where the visualization of the transitional zone was not possible, biopsies were taken as follows:

- a) middle part of the sigmoid colon – normal innervation – confirmation of short-segment HD and possible TEPT;
- b) splenic flexure – normal innervation, with aganglionosis in biopsy taken from site a);
- c) proximal section of the transverse colon – normal innervation with aganglionosis in biopsies at sites a) and b) – possible laparoscopic-assisted TEPT with the mobilization of descending colon, splenic and hepatic flexures as well as the whole transverse colon;
- d) cecum – differentiation between long-segment HD if normal innervation; and total colonic aganglionosis if aganglionosis found in biopsy – in our experience requiring multistage treatment with temporary colostomy or ileostomy;
- e) ileum about 5–10 cm proximal to the ileocecal valve; and higher biopsies – determination of the level for ileostomy.

Biopsy sites were closed with absorbable, braided 4.0 or 5.0 sutures in the case of suspected perforation, or in order to mark the level of normal innervations (Fig. 2). All biopsy samples were evaluated intraoperatively for the decision-making results as described above, except for the first patient in the series – in this case, the decision concerning further procedures was made after receiving the results of histopathological examination. The waiting time for the intraoperative evaluation of each frozen specimen was less than 15 min for a single biopsy.

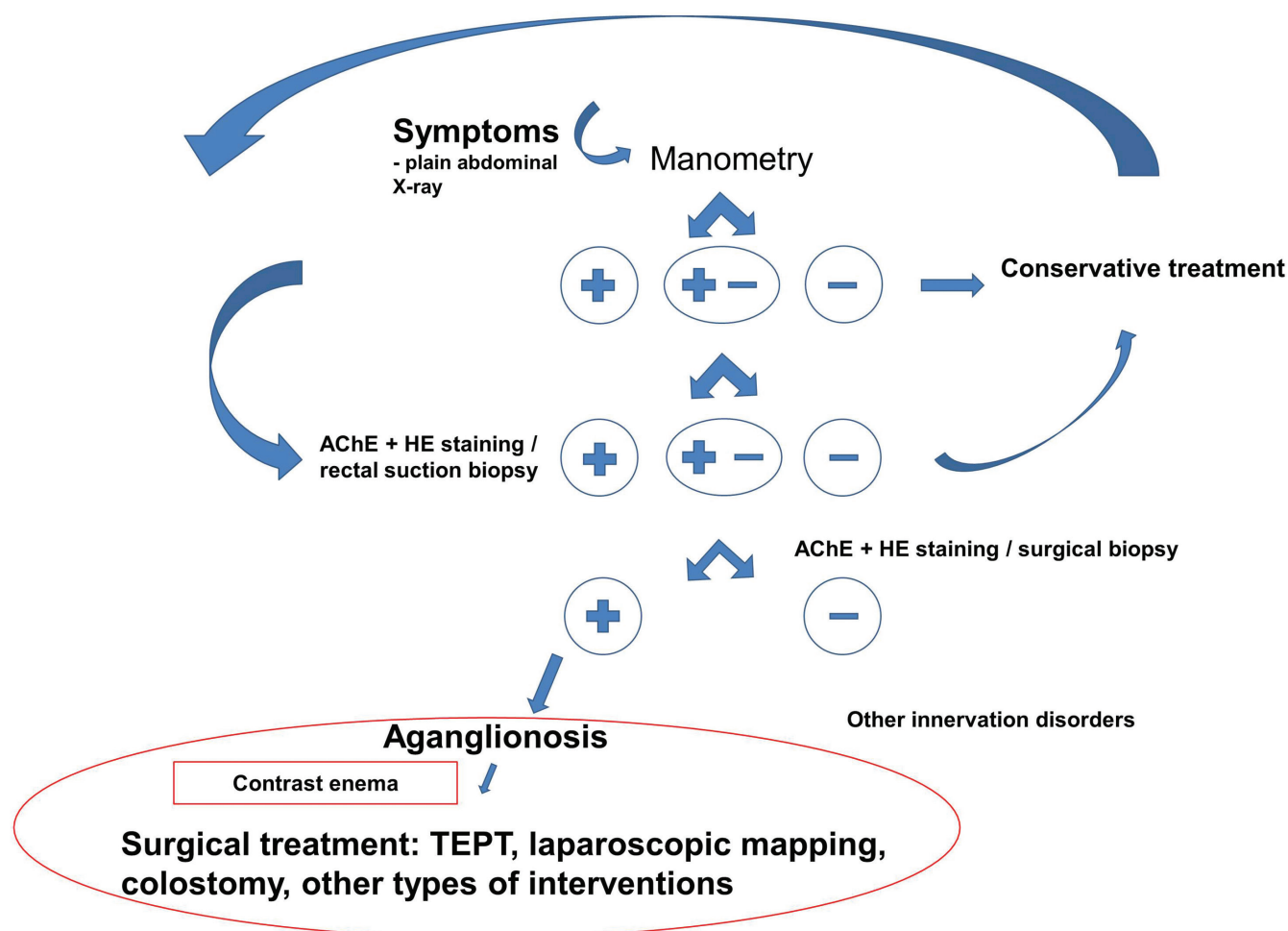


Fig. 1. Diagnostic/decision-making scheme for patients with suspected HD

## Results

Forty-nine biopsy samples were collected from 14 children. In 7 patients, it was necessary to collect 5 samples (including 1 case of unavailable intraoperative sample assessment, 5 cases with long-segment HD and 1 case finally diagnosed with immature ganglion cells). In 7 other patients, 2 biopsies were sufficient to establish the length of aganglionic segment (including 4 children with short-segment HD and 2 with long-segment HD). The last patient in this group was finally diagnosed with immature ganglion cells.

Out of 49 biopsy samples, 4 were intraoperatively assessed as unsuitable for histopathological analysis. Eighteen biopsy sites required intracorporeal suturing because of suspected perforation of the mucous membrane. Sites with normal innervation determined during intraoperative histological evaluation were marked with sutures to facilitate their identification during further procedures (transanal dissection or colostomy), without the need for additional biopsies.

In 12 patients, laparoscopic histological mapping allowed for the determination of final diagnosis and establishment of the mode of surgical treatment. Short-segment

aganglionosis (transitional zone determined in the medial or distal part of the sigmoid colon) was diagnosed in 6 cases, and long-segment aganglionosis in 6 cases (in 1 case, normal innervation determined in the descending colon biopsy and in 2 cases, within the samples from the middle section of transverse colon). In 2 patients, despite initial diagnosis of HD, this pathology was excluded on the basis of the results of laparoscopic mapping and repeat rectal biopsy. The results of preoperative contrast enema did not correspond with the histopathological picture in any of the presented patients.

Three children with determined short-segment disease underwent TEPT during the same procedure. Two children with determined short-segment disease underwent temporary colostomy and definite surgical treatment using the Duhamel–Martin–Ikeda method due being over the age of 12 months at diagnosis. One patient with short-segment HD underwent TEPT in a consecutive procedure (intraoperative evaluation of samples was unavailable at the time of laparoscopic mapping). Five patients with long-segment HD (innervation level between the descending colon and middle section of transverse colon) underwent laparoscopic-assisted TEPT. One patient

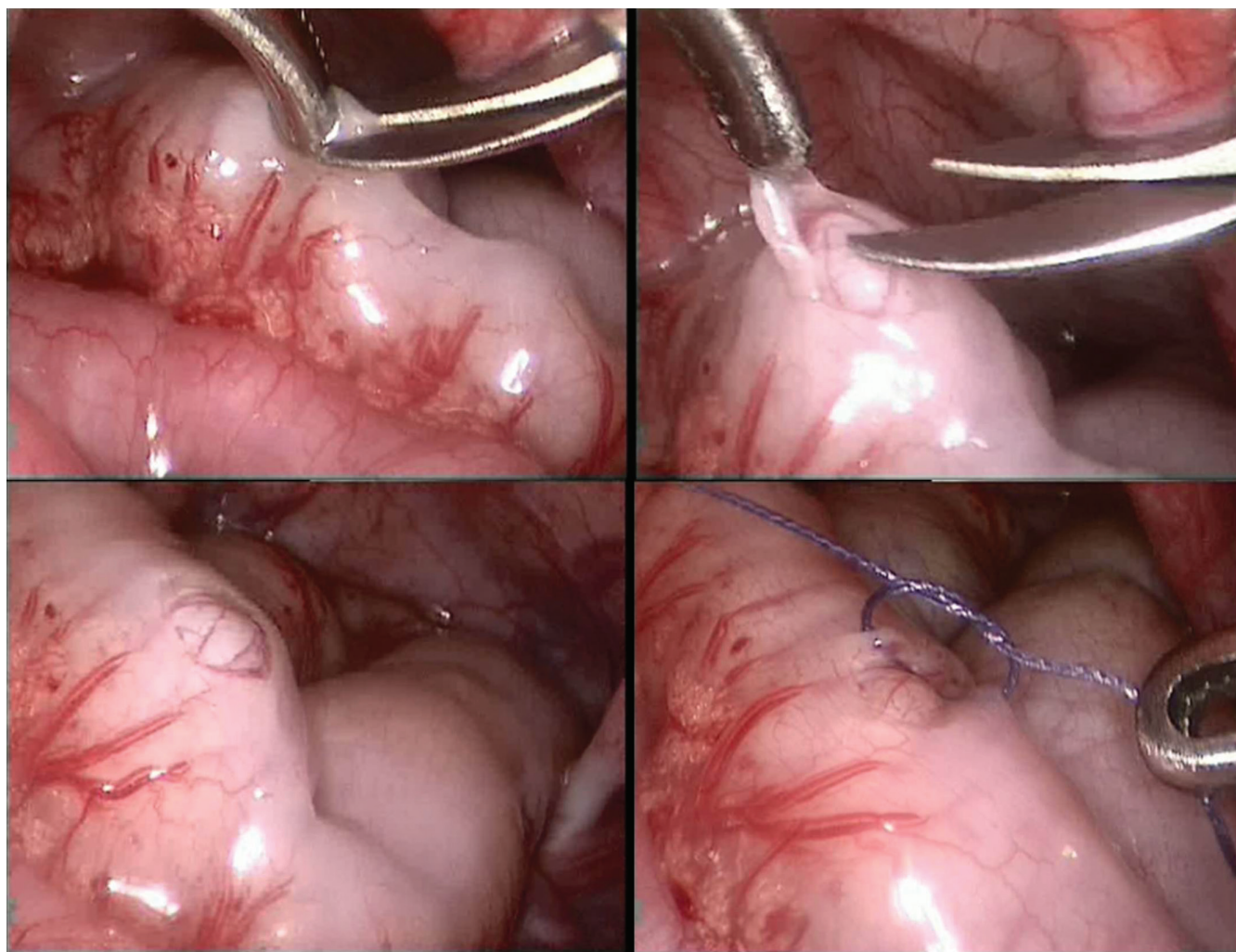


Fig. 2. Technique of seromuscular biopsy of the intestine (3-mm instruments)

with long-segment disease (with aganglionosis extending to the right section of the transverse colon) underwent a temporary double-barrel colostomy (directly after laparoscopic mapping, during the same procedure). The definite operation in this patient was performed 3 months later using the Duhamel–Martin–Ikeda method. There were no identified complications related to the laparoscopic mapping procedures.

## Discussion

The implementation of TEPT in the treatment of HD is connected with the problem of its application in children with long-segment HD or uncertain diagnosis concerning the length of aganglionic segment. A solely transanal approach technique in misdiagnosed long-segment HD disease can result in an unplanned open or laparoscopic intra-abdominal intervention. Thus, a sensitive method for the detection of the length of aganglionic segment seems necessary, particularly concerning the risk associated with attempts of transanal dissection of retroperitoneal colon sections.

A method we considered helpful to avoid the above-mentioned problem was developed by Georgeson et al.<sup>8,9</sup> The author emphasized the benefits of his method – laparoscopic-assisted transanal endorectal pull-through – such as the ability to verify the level of aganglionosis before endorectal dissection. We believe this is the most vital benefit of the method, and our observations have been confirmed by the reports of other authors.<sup>10,11</sup> Before the introduction of laparoscopic mapping, we encountered problems with the identification of the transitional zone on the basis of contrast enema, which resulted in the need for an unplanned laparotomy in 2 children operated with TEPT for misdiagnosed long-segment HD.

Numerous authors underline the benefits of laparoscopic intra-abdominal mobilization of the aganglionic segment, such as avoiding overdilation of the internal anal sphincter during TEPT (which may lead to possible weakening of the patient's fecal continence), a more definitive endpoint for endorectal dissection, and greater versatility in fashioning the ganglionated pedicle, allowing for pull-through operations in patients with longer aganglionic segments.<sup>9,12–14</sup> On the other hand, some researchers currently



question the deliberate use of laparoscopic assistance in diagnosed short-segment HD, because of longer operation time and additional incisions.<sup>15</sup> A meta-analysis published by Thomson et al. (405 patients), comparing short and long-term outcomes following total transanal endorectal pull-through with laparoscopic-assisted pull-through procedures, failed to show any advantages of either of these approaches.<sup>16</sup> This conclusion has been confirmed, particularly for rectosigmoid HD, in the European Reference Network for rare and inherited and congenital digestive disorders (ERNICA) guidelines.<sup>7</sup>




## Limitations

In our experience, consistent with the observations of other authors, the use of TEPT is connected with a postoperative tendency to constipation rather than incontinence.<sup>17</sup> Following the use of the De la Torre technique for almost 10 years in our department, we also did not find any additional benefit of laparoscopic assistance in children with diagnosed short-segment HD. However, marking the precise level of innervation with seromuscular sutures in doubtful cases appears helpful in the determination of the level of resection of the aganglionic segment during transanal dissection. Laparoscopic assistance not only shows the level of innervation, but also allows for the dissection of the aganglionic segment during the same surgical procedure. This makes possible to perform TEPT even in patients with aganglionosis involving the descending and transverse colon.

## Conclusions

The laparoscopic histological mapping of the colon and ileum is safe and effective in the determination of the length of aganglionic segment in neonates and infants with diagnosed HD, and in doubtful cases, it can be helpful in establishing the final mode of surgical treatment. Laparoscopic assistance makes one-stage treatment possible in selected patients with long-segment HD.

## ORCID iDs

Bartosz Bogusz  <https://orcid.org/0000-0002-8763-0990>  
 Małgorzata Smolec-Zamora  <https://orcid.org/0000-0001-8993-3867>  
 Andrzej Zajac  <https://orcid.org/0000-0003-4676-0446>  
 Adam Mol  <https://orcid.org/0000-0001-9378-549X>  
 Wojciech Górecki  <https://orcid.org/0000-0003-4907-0520>

## References

- De La Torre-Mondragon L, Ortega-Salgado JA. Transanal endorectal pull-through for Hirschsprung's disease. *J Pediatr Surg*. 1998;33(8):1283–1286. doi:10.1016/s0022-3468(98)90169-5
- Langer JC, Durrant AC, de la Torre L, et al. One-stage transanal Soave pull-through for Hirschsprung's disease: A multicenter experience with 141 children. *Ann Surg*. 2003;238(4):569–583, discussion 583–585. doi:10.1097/01.sla.0000089854.00436.cd
- Albanese CT, Jennings RW, Smith B, Bratton B, Harrison MR. Perineal one-stage pull-through for Hirschsprung's disease. *J Pediatr Surg*. 1999;34(3):377–380. doi:10.1016/s0022-3468(99)90480-3
- Gao Y, Li G, Zhang X, et al. Primary transanal rectosigmoidectomy for Hirschsprung's disease: Preliminary results in the initial 33 cases. *J Pediatr Surg*. 2001;36(12):1816–1819. doi:10.1053/jpsu.2001.28847
- Höllwarth ME, Rivosecchi M, Schleef J, et al. The role of transanal endorectal pull-through in the treatment of Hirschsprung's disease: A multicenter experience. *Pediatr Surg Int*. 2002;18(5–6):344–348. doi:10.1007/s00383-002-0747-x
- Smith GHH, Cass D. Infantile Hirschsprung's disease: Is barium enema useful? *Pediatr Surg Int*. 1991;6:318–321.
- Kyrklund K, Sloots CEJ, de Blaauw I, et al. ERNICA guidelines for the management of rectosigmoid Hirschsprung's disease. *Orphanet J Rare Dis*. 2020;15:164. doi:10.1186/s13023-020-01362-3
- Georgeson KE, Fuefner MM, Hardin WD. Primary laparoscopic pull-through for Hirschsprung's disease in infants and children. *J Pediatr Surg*. 1995;30(7):1017–1021, discussion 1021–1022. doi:10.1016/0022-3468(95)90333-x
- Georgeson KE, Cohen RD, Hebra A, et al. Primary laparoscopic endorectal colon pull-through for Hirschsprung's disease: A new gold standard. *Ann Surg*. 1999;229(5):678–682. doi:10.1097/00000658-199905000-00010
- Li X, Li X, Cheng J, et al. Laparoscopic-assisted endorectal pull-through for Hirschsprung's disease: A retrospective study. *Saudi Med J*. 2017;38(12):1255–1258. doi:10.15537/smj.2017.12.20859
- Fang Y, Bai J, Zhang B, Wu D, Lin Y, Liu M. Laparoscopic Soave procedure for long-segment Hirschsprung's disease: Single-center experience. *Videosurgery Miniinv*. 2020;15(1):234–238. doi:10.5114/wiitm.2019.86807
- Wulkan ML, Georgeson KE. Primary laparoscopic endorectal pull-through for Hirschsprung's disease in infants and children. *Semin Laparosc Surg*. 1999;5(1):9–13. doi:10.1177/155335069800500103
- El Sadat AM. Laparoscopic-assisted transanal endorectal pull-through for Hirschsprung's disease: Experience with 15 cases. *Ann Ped Surg*. 2009;5(3):181–186.
- El-Elah Ali KA. Transanal endorectal pull-through for Hirschsprung's disease during the first month of life. *Ann Ped Surg*. 2010;6(2):81–88.
- van de Ven TJ, Sloots CE, Wijnen MH, et al. Transanal endorectal pull-through for classic segment Hirschsprung's disease: With or without laparoscopic mobilization of the rectosigmoid? *J Pediatr Surg*. 2013;48(9):1914–1918. doi:10.1016/j.jpedsurg.2013.04.025
- Thomson D, Allin B, Long AM, Bradnock T, Walker G, Knight M. Laparoscopic assistance for primary transanal pull-through in Hirschsprung's disease: A systemic review and meta-analysis. *BMJ Open*. 2015;5(3):e006063. doi:10.1136/bmjopen-2014-006063
- De La Torre L, Langer JC. Transanal endorectal pull-through for Hirschsprung's disease: Technique, controversies, pearls, pitfalls, and an organized approach to the management of postoperative obstructive symptoms. *Semin Pediatr Surg*. 2010;19:96–106. doi:10.1053/j.sempedsurg.2009.11.016