

# Intra-aneurysm sac pressure measurement using a thin pressure wire during endovascular aneurysm repair

Maciej Antkiewicz<sup>1,A,C–F</sup>, Wiktor Kuliczowski<sup>2,A,C,E,F</sup>, Marcin Protasiewicz<sup>2,A,C,E,F</sup>, Magdalena Kobielarz<sup>3,C–F</sup>, Piotr Barć<sup>1,B,E,F</sup>, Maciej Malinowski<sup>1,B,E,F</sup>, Katarzyna Frączkowska<sup>1,C,D,F</sup>, Katarzyna Kulikowska<sup>1,B,E,F</sup>, Marcin Merenda<sup>1,B,E,F</sup>, Krzysztof Jacyna<sup>1,B,E,F</sup>, Tomasz Dawiskiba<sup>1,A,E,F</sup>, Dariusz Janczak<sup>1,A,C,E,F</sup>

<sup>1</sup> Department and Clinic of Vascular, General and Transplantation Surgery, Wrocław Medical University, Poland

<sup>2</sup> Department and Clinic of Cardiology, Wrocław Medical University, Poland

<sup>3</sup> Department of Mechanics, Materials Science and Biomedical Engineering, Wrocław University of Science and Technology, Poland

A – research concept and design; B – collection and/or assembly of data; C – data analysis and interpretation; D – writing the article; E – critical revision of the article; F – final approval of the article

Advances in Clinical and Experimental Medicine, ISSN 1899–5276 (print), ISSN 2451–2680 (online)

*Adv Clin Exp Med.* 2021;30(3):309–313

## Address for correspondence

Marcin Protasiewicz

E-mail: mprot@poczta.onet.pl

## Funding sources

Ministry of Health grants according to No. of SUB. C020.19.064 and STM.C021.20.036 from the IT Simple system of Wrocław Medical University, Poland.

## Conflict of interest

None declared

Received on December 10, 2020

Reviewed on December 31, 2020

Accepted on February 17, 2021

Published online on March 23, 2021

## Cite as

Antkiewicz M, Kuliczowski W, Protasiewicz M, et al. Intra-aneurysm sac pressure measurement using a thin pressure wire during endovascular aneurysm repair. *Adv Clin Exp Med.* 2021;30(3):309–313. doi:10.17219/acem/133425

## DOI

10.17219/acem/133425

## Copyright

© 2021 by Wrocław Medical University

This is an article distributed under the terms of the Creative Commons Attribution 3.0 Unported (CC BY 3.0) (<https://creativecommons.org/licenses/by/3.0/>)

## Abstract

**Background.** An endoleak is a typical complication of endovascular aneurysm repair (EVAR). It is characterized by persistent blood flow between a stent graft and the aneurysm sac. Usually, it can be visualized during primary EVAR, but in many cases, this remains impossible. Therefore, other methods of endoleak assessment are urgently needed. The measurement of aneurysm sac pressure (ASP) seems to be a promising direction of research in this area.

**Objectives.** We aimed to evaluate the safety and efficacy of a new method for invasive pressure measurement inside the abdominal aortic aneurysm (AAA) during EVAR. We also assessed a correlation between pressure values and early angiographic occurrence of an endoleak after the procedure.

**Materials and methods.** A total of 20 patients with AAA were included in this experimental prospective study. During EVAR, systolic, diastolic and mean pressure values were recorded both for ASP and aortic pressure (AP) before procedure, after stent graft opening and after final stent graft ballooning.

**Results.** The measurements were successfully obtained in all participants without any complications. There were no significant differences between all ASP and AP before procedure. After the procedure, blood pressure significantly decreased in the aneurysm sac but not in the aorta. Systolic ASP was significantly lower than systolic AP both after stent graft opening ( $80.4 \pm 20.9$  mm Hg compared to  $110.7 \pm 21.6$  mm Hg,  $p < 0.01$ ) and after its balloon post-dilatation ( $65.6 \pm 26.1$  mm Hg compared to  $107.4 \pm 22.1$  mm Hg,  $p < 0.001$ ). Diastolic ASP decreased significantly in comparison to diastolic AP only after stent graft ballooning ( $48.0 \pm 14.6$  mm Hg compared to  $56.4 \pm 13.6$  mm Hg,  $p < 0.05$ ).

**Conclusions.** Our study confirmed that the novel method for the measurement of ASP during EVAR, using a thin pressure wire, is feasible and safe.

**Key words:** endoleak, endovascular aneurysm repair, abdominal aortic aneurysm, aneurysm sac pressure

## Background

One of the most serious conditions in current vascular surgery is abdominal aortic aneurysm (AAA), which is defined as an enlargement of the aortic diameter by at least 50%. The major complication of AAA is rupture, which is a life-threatening condition that requires emergency treatment. The risk of aneurysm rupture grows exponentially with an increase in aneurysm diameter. Therefore, aneurysms of 55 mm in diameter are an indication for surgical treatment, even if they are asymptomatic.

Currently, there are 2 methods of surgical treatment for AAA: a classic open surgery and endovascular aneurysm repair (EVAR). The latter is becoming increasingly popular and is gradually replacing classic open surgeries. Endovascular repair involves implantation of a stent graft, that is, endovascular prosthesis, using common femoral artery access. The stent graft, which is deployed in the aneurysm lumen, creates a new channel for blood flow and closes its way to the aneurysm sac, thereby protecting it from high pulsatile blood pressure. The advantages of this method include less extensive trauma, faster recovery and a lower risk of infection than with open aortic repair.

Despite its obvious benefits, EVAR is not without limitations. A typical complication of the procedure is the so-called endoleak, which involves the presence of blood flow between a stent graft and the aneurysm sac. It is estimated that endoleaks occur in 17–26% of patients after EVAR,<sup>1–4</sup> especially those who show aneurysm growth and rupture.<sup>5</sup>

Although endoleaks can typically be visualized during primary EVAR, in many cases, this remains impossible. Therefore, there is an urgent need to develop novel methods of endoleak assessment. The measurement of aneurysm sac pressure (ASP) seems to be a promising direction of research. We postulate that continuation of ASP and its systolic–diastolic amplitude after EVAR may suggest the presence of endoleak while the decrease of these parameters indicates a correct result of the procedure.

## Objectives

In this study, we aimed to evaluate the efficacy and safety of a new method for the measurement of intra-aneurysm pressure during EVAR. We also assessed the correlation between ASP and early occurrence of an endoleak early after the procedure.

## Materials and methods

### Study design and population

This was a prospective study based on the analysis of invasive pressure measurements obtained during endovascular treatment of infrarenal AAAs. A total of 23 patients

(18 men and 5 women) at a mean age of  $71.8 \pm 6.6$  years (range: 58–85 years) were enrolled. The inclusion criteria were as follows: 1) a referral for primary surgical treatment of an AAA using EVAR; 2) the presence of an asymptomatic AAA; and 3) the length of the aneurysm neck of at least 20 mm. The demographic and clinical data of patients is presented in Table 1.

### Endovascular aneurysm repair

We performed a standard stent graft implantation in a hybrid operating room with a fixed C-arm system.<sup>6</sup> The procedure was carried out under local anesthesia of the inguinal region. Bilateral femoral artery access was used. The main body of the bifurcated stent graft was deployed, positioned and opened under angiographic guidance, just below the origin of the renal arteries. Then, the ipsilateral and contralateral arms of the stent graft were deployed. The EVAR outcome, including early endoleak, was monitored using angiography. Femoral punctures were sealed using an endovascular closure device. After the procedure, all patients received dual antiplatelet therapy (aspirin plus clopidogrel, both 75 mg daily) for 3 months, followed by lifelong 75 mg aspirin according to protocol.<sup>7</sup>

### Pressure measurement

The pressure measurements were taken with a 0.014-inch wire (COMET II Pressure Guidewire; Boston Scientific, Marlborough, USA). A 6F Judkins right guiding catheter (Boston Scientific) was inserted using percutaneous radial access and advanced proximally to the aneurysm. The guidewire was advanced through the catheter into the aneurysm sac before stent graft implantation to monitor the ASP (position of pressure guidewire is visible in Fig. 1). Aortic pressure (AP) was measured through the catheter. Pressure measurements were taken at each stage of the procedure – that is, before and after stent graft deployment – as well as after ballooning of the stent graft. Systolic, diastolic and mean pressure values were recorded both for ASP and AP. Once the stent graft implantation was completed, the guidewire and the catheter were removed.

### Ethics

All patients gave their written informed consent to undergo treatment, and the study protocol was approved by the local ethics committee. The study was conducted in line with the principles of the Declaration of Helsinki.

### Statistical analysis

The Shapiro–Wilk test for normality was performed, followed by the Student's *t*-test for comparison between the obtained coefficients (dependent samples).

Table 1. Patients enrolled in the study

Patient No.	Gender	Age [years]	BMI	Comorbidities	Model of implanted stent graft
1	F	71	25.3	HT, COPD	Gore Excluder
2	M	85	27.8	HT, CVD, DM	Gore Excluder
3	M	68	27.7	HT, NE	Terumo Aortic Treo
4	M	73	26.5	HT, KD, NE	Jotec E-tegra
5	M	69	21.8	HT	Terumo Aortic Treo
6	M	83	28.7	HT, CVD, NE	Terumo Aortic Treo
7	M	62	31.1	HT	Terumo Aortic Treo
8	F	72	31.1	HT	Terumo Aortic Treo
9	F	73	25.0	HT	Terumo Aortic Treo
10	M	66	38.1	HT	Terumo Aortic Treo
11	M	80	24.7	HT, CVD, COPD, DM	Jotec E-tegra
12	M	66	31.3	HT	Terumo Aortic Treo
13	M	80	29.4	HT, CVD	Gore Excluder
14	M	75	32.3	HT, CVD, DM	Gore Excluder
15	M	72	26.3	–	Cook Zenith Alpha
16	M	66	28.7	–	Gore Excluder
17	M	68	24.2	–	Gore Excluder
18	F	74	31.3	HT	Cook Zenith Alpha
19	M	58	34.7	HT	Medtronic Endurant
20	M	75	31.7	HT	Medtronic Endurant
21	F	72	23.5	HT, CVD	Cook Zenith Alpha
22	M	66	23.5	HT	Cook Zenith Alpha
23	M	78	30.9	HT, CVD	Cook Zenith Alpha

M – male; F – female; BMI – body mass index; COPD – chronic obstructive pulmonary disease; CVD – cardiovascular disease; DM – diabetes mellitus; HT – hypertension; KD – kidney disease; NE – neurologic events.

The significance level was set at a p-value of less than 0.05. The analysis of correlation was performed using Pearson's correlation coefficient. STATISTICA v. 13.3 software (StatSoft Inc., Tulsa, USA) was used for analysis.

## Results

The measurements were successfully obtained during EVAR in all patients without any complications.

Systolic, diastolic and mean pressure values for ASP and AP during the main stages of EVAR are shown in Fig. 2–4. Before stent graft deployment, all ASP and AP were almost equal. The systolic AP was maintained at the same level throughout the procedure ( $109.5 \pm 22.8$  mm Hg before procedure compared to  $110.7 \pm 21.6$  mm Hg after opening compared to  $107.4 \pm 22.1$  mm Hg after ballooning, not significant (NS)). Similar observation was noted for diastolic AP ( $58.7 \pm 13.2$  mm Hg compared to  $55.2 \pm 13.5$  mm Hg compared to  $56.4 \pm 13.6$  mm Hg, respectively, NS) and mean AP ( $74.2 \pm 14.8$  mmHg compared to  $74.8 \pm 14.1$  mm Hg compared to  $73.4 \pm 13.8$  mm Hg, respectively, NS). However, after the main body and limbs

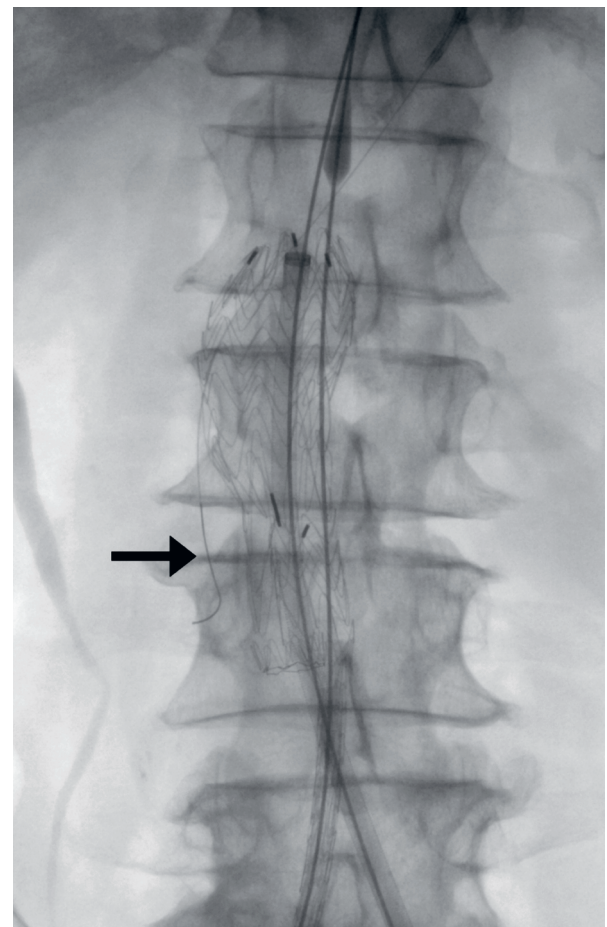


Fig. 1. Position of pressure guidewire during EVAR (black arrow)

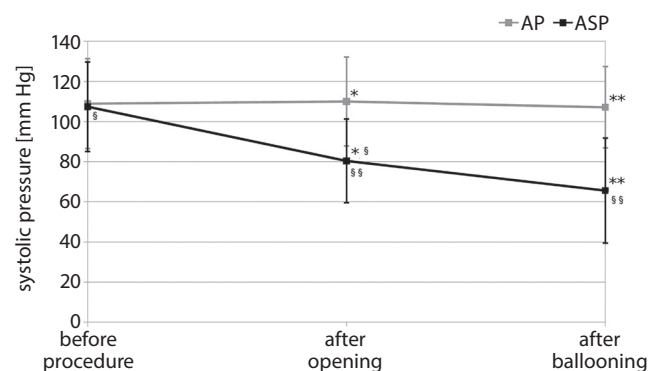


Fig. 2. ASP and AP values for systolic pressure on each stage of stent graft deployment. Data shown as means  $\pm$  95% confidence interval (95% CI); Student's t-test paired comparison

\*ASP after opening compared to AP after opening,  $p < 0.001$ ; \*\*ASP after ballooning compared to AP after ballooning,  $p < 0.001$ ; §ASP after opening compared to baseline ASP,  $p < 0.001$ ; §§ASP after opening compared to ASP after ballooning,  $p < 0.001$ .

of the stent graft were opened, systolic ASP was reduced significantly from  $107.4 \pm 22.3$  mm Hg to  $80.4 \pm 20.9$  mm Hg ( $p < 0.001$  compared to baseline systolic ASP and  $p < 0.001$  compared to AP after opening) and after ballooning

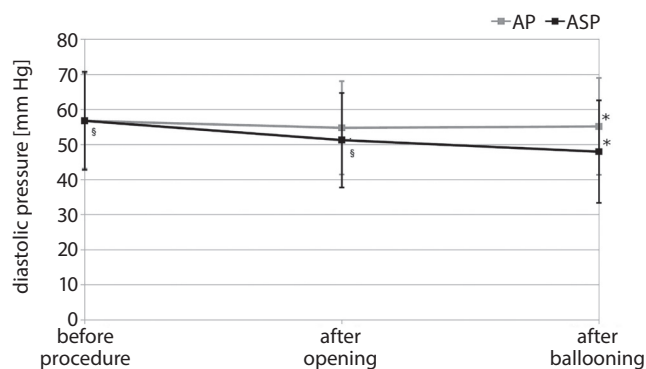


Fig. 3. ASP and AP values for diastolic pressure on each stage of stent graft deployment. Data shown as means  $\pm$  95% CI; Student's t-test paired comparison

\*ASP after ballooning compared to AP after ballooning,  $p < 0.05$ ;

§ASP after opening compared to baseline ASP,  $p < 0.05$ .

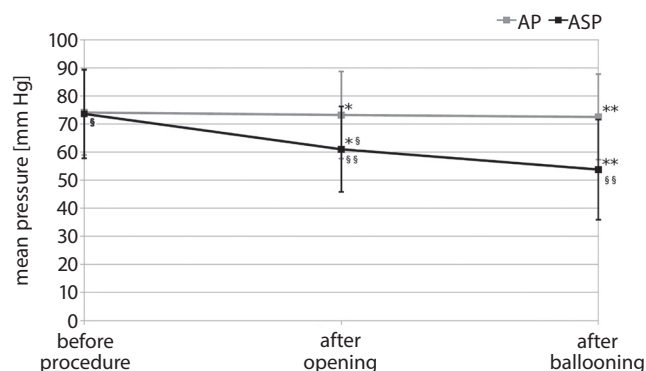


Fig. 4. ASP and AP values for mean pressure on each stage of stent graft deployment

Data shown as means  $\pm$  95% CI; Student's t-test paired comparison

\*ASP after opening compared to AP after opening,  $p < 0.001$ ; \*\*ASP after ballooning compared to AP after ballooning,  $p < 0.001$ ; §ASP after opening compared to baseline ASP,  $p < 0.001$ ; §§ASP after opening compared to ASP after ballooning,  $p < 0.01$ .

to  $65.6 \pm 26.1$  mm Hg ( $p < 0.001$  compared to ASP after opening and  $p < 0.01$  compared to AP after ballooning) (Fig. 2). Diastolic ASP after opening dropped from  $56.8 \pm 14.0$  mm Hg to  $51.3 \pm 13.5$  mm Hg ( $p < 0.05$  compared to baseline diastolic ASP) and after ballooning it decreased to  $48.0 \pm 14.6$  mm Hg ( $p = 0.06$  compared to diastolic ASP after opening and  $p < 0.05$  compared to AP after ballooning) (Fig. 3). Mean ASP after opening dropped from  $73.6 \pm 15.8$  mm Hg to  $61.0 \pm 15.2$  mm Hg ( $p < 0.001$  compared to baseline mean ASP and  $p < 0.001$  compared to AP after opening) and subsequently to  $53.8 \pm 17.8$  mm Hg ( $p < 0.01$  compared to mean ASP after opening and  $p < 0.001$  compared to AP after ballooning) (Fig. 4). The correlation results for AP and ASP are presented in Table 2.

Angiography performed after EVAR demonstrated the presence of an endoleak in 5 patients (1 endoleak type I and 4 endoleaks type II; please see the Discussion section for explanations of endoleak types). The ASP values for mean pressure in endoleak type II appeared to be

Table 2. Correlations between aneurysm sac pressure and aortic pressure

ASP and AP	r-value	p-value
Systolic baseline	0.98	<0.001
Systolic after stent graft opening	0.45	<0.05
Systolic after ballooning	0.47	<0.05
Diastolic baseline	0.99	<0.001
Diastolic after stent graft opening	0.74	<0.001
Diastolic after ballooning	0.64	<0.01

AP – aortic pressure; ASP – aneurysm sac pressure.

comparable with ASP mean pressure in group without endoleak ( $48.8 \pm 1.4$  mm Hg compared to  $54.1 \pm 19.7$  mm Hg, respectively,  $p = 0.06$ ). Mean ASP in 1 case of endoleak type I was higher (70.0 mm Hg) than in the other cases.

## Discussion

Our study showed that pressure wire usage to measure ASP is feasible and safe. It was free of complications, including those associated with radial artery access. The presence of the pressure wire in the aneurysm lumen had no influence on the efficacy of the EVAR procedure. Moreover, the use of a 0.0014-inch pressure wire instead of a standard catheter allowed us to avoid leakage between the stent graft and the aneurysm neck. We observed a significant decrease in ASP during EVAR. The value of ASP diminished both after stent graft opening and its ballooning.

As the measurement of ASP is invasive and its clinical significance remains unclear, it is still rarely performed in the patients with AAA. When it is performed, it is usually done within 6 months from EVAR. Velazquez et al. performed ASP measurement in 76 patients, 17% of whom were shown to develop an endoleak (mostly associated with patent inferior mesenteric artery). Two-thirds of patients with endoleak had equal ASP and AP values.<sup>2</sup> A similar study was conducted by Baum et al. in 27 patients. Endoleak was present in 17 patients; ASP and AP values were comparable in 15 patients, while in 2 patients, ASP was half as low as AP.<sup>8</sup>

Depending on etiology, there are 5 types of endoleak: type I is caused by a leak at the end of prosthesis; type II is a leak from the branches of the aneurysm; type III is the leak connected with the defect of the stent graft; type IV is a leak through the fabric microporosity of stent graft; and type V is associated with so-called endotension, which means an enlargement of the aneurysmal sac with no visible endoleak.<sup>9,10</sup> Type I and III endoleaks are considered high-pressure endoleaks, with a high risk of aneurysm sac rupture because of direct exposure of the aneurysm wall to aortic pressure. Type II, IV and V endoleaks are considered lower risk and many of them may close spontaneously over time.<sup>11,12</sup>



A number of studies demonstrated a positive relationship between increased ASP and aneurysm growth or endoleak presence.<sup>13,14</sup> Using the experimental model of endotension, Shawn Skillern et al. concluded that high ASP after EVAR might be associated with a need for re-intervention in the future.<sup>15</sup> Chaudhuri et al. studied the impact of an endoleak on the experimental aneurysm model and revealed that only some types of endoleak were related to higher ASP.<sup>16</sup> A pending issue is ASP response to the different types of endoleak. Due to an insufficient sample size, this question could not be adjudicated in this study; however, it is of note that 1 case of endoleak type I presented high ASP values after the procedure, while cases with no endoleak or endoleak type II presented a decrease of ASP.

In contrast to the aforementioned studies, our measurements were performed during EVAR. Such a measurement is much less invasive and may be performed intraoperatively. Previous findings were long-term results that were frequently associated with EVAR-related changes inside the aneurysm sac, such as thrombus formation. This may suggest that the early outcome of EVAR may be less satisfactory than we expected.

We believe that potential clinical application of pressure measurements during the EVAR could be detection of early endoleaks that cannot be visualized by angiography, which may be very important in case of high-pressure endoleaks. These measurements may also facilitate the identification of patients at risk of endoleak and aneurysm growth, who thus require closer monitoring.



## Limitations









Our study has several limitations. Most importantly, it was based on a small group of patients followed for a short time. However, we are planning to expand our study population and investigate the significance of correlations between the measured parameters and possible changes in aneurysm anatomy, the rate of re-interventions and the occurrence of endoleaks.

## Conclusions

Our study proved that the novel method for the measurement of aneurysm sac pressure using a pressure wire during EVAR is safe and feasible. Our planned research will compare the current results with follow-up computed tomography angiography of our patients, which should provide further important insights, with possible implications for future research and clinical practice.

### ORCID iDs

Maciej Antkiewicz  <https://orcid.org/0000-0003-1227-7720>  
 Wiktor Kuliczowski  <https://orcid.org/0000-0001-6284-0820>  
 Marcin Protasiewicz  <https://orcid.org/0000-0003-0253-0585>  
 Magdalena Kobielarz  <https://orcid.org/0000-0002-0191-6390>

Piotr Barć  <https://orcid.org/0000-0003-1080-227X>  
 Maciej Malinowski  <https://orcid.org/0000-0002-8443-0125>  
 Katarzyna Frączkowska  <https://orcid.org/0000-0002-1395-348X>  
 Katarzyna Kulikowska  <https://orcid.org/0000-0003-2427-4471>  
 Marcin Merenda  <https://orcid.org/0000-0003-2282-6228>  
 Krzysztof Jacyna  <https://orcid.org/0000-0001-6665-1402>  
 Tomasz Dawiskiba  <https://orcid.org/0000-0003-2329-2918>  
 Dariusz Janczak  <https://orcid.org/0000-0003-4671-9128>

## References

1. Frego M, Lumachi F, Bianchera G, et al. Risk factors of endoleak following endovascular repair of abdominal aortic aneurysm: A multicentric retrospective study. *In Vivo*. 2007;21(6):1099–1102. PMID:18210763
2. Velazquez OC, Baum RA, Carpenter JP, et al. Relationship between preoperative patency of the inferior mesenteric artery and subsequent occurrence of type II endoleak in patients undergoing endovascular repair of abdominal aortic aneurysms. *J Vasc Surg*. 2000;32(4):777–788. doi:10.1067/mva.2000.108632
3. Chuter TA, Faruqi RM, Sawhney R, et al. Endoleak after endovascular repair of abdominal aortic aneurysm. *J Vasc Surg*. 2001;34(1):98–105. doi:10.1067/mva.2001.111487
4. Corriere MA, Feurer ID, Becker SY, et al. Endoleak following endovascular abdominal aortic aneurysm repair: Implications for duration of screening. *Ann Surg*. 2004;239(6):800–805, discussion 805–807. doi:10.1097/01.sla.0000128300.60156.ab
5. Koole D, Moll FL, Buth J, et al. Annual rupture risk of abdominal aortic aneurysm enlargement without detectable endoleak after endovascular abdominal aortic repair. *J Vasc Surg*. 2011;54(6):1614–1622. doi:10.1016/j.jvs.2011.06.095
6. Nishibe T, Iwahashi T, Kamiya K, et al. Two-year outcome of the Endurant stent graft for endovascular abdominal aortic repair in Japanese patients: Incidence of endoleak and aneurysm sac shrinkage. *Int Angiol*. 2017;36(3):237–242. doi:10.23736/S0392-9590.16.03726-3
7. Protasiewicz M, Szymkiewicz P, Kuliczowski W, Mysiak A, Witkiewicz W. Modern antiplatelet therapy: Opportunities and risks. *Adv Clin Exp Med*. 2013;22(6):875–885. PMID:24431318
8. Baum RA, Carpenter JP, Cope C, et al. Aneurysm sac pressure measurements after endovascular repair of abdominal aortic aneurysms. *J Vasc Surg*. 2001;33(1):32–41. doi:10.1067/mva.2001.111807
9. Wacker FK, Valdeig S, Raatschen HJ, Meyer BC. C-arm CT: An adjunct to DSA for endoleak classification in patients with endovascular repair of abdominal aortic aneurysms. *Rofo*. 2014;186(3):247–252. doi:10.1055/s-0033-1350500
10. Phade SV, Garcia-Toca M, Kibbe MR. Techniques in endovascular aneurysm repair. *Int J Vasc Med*. 2011;2011:964250. doi:10.1155/2011/964250
11. Bashir MR, Ferral H, Jacobs C, McCarthy W, Goldin M. Endoleaks after endovascular abdominal aortic aneurysm repair: Management strategies according to CT findings. *AJR Am J Roentgenol*. 2009;192(4):W178–W186. doi:10.2214/AJR.08.1593
12. Stavropoulos SW, Charagundla SR. Imaging techniques for detection and management of endoleaks after endovascular aortic aneurysm repair. *Radiology*. 2007;243(3):641–655. doi:10.1148/radiol.2433051649
13. Dias NV, Ivancev K, Malina M, Resch T, Lindblad B, Sonesson B. Intra-aneurysm sac pressure measurements after endovascular aneurysm repair: Differences between shrinking, unchanged, and expanding aneurysms with and without endoleaks. *J Vasc Surg*. 2004;39(6):1229–1235. doi:10.1016/j.jvs.2004.02.041
14. Dias NV, Ivancev K, Resch TA, Malina M, Sonesson B. Endoleaks after endovascular aneurysm repair lead to nonuniform intra-aneurysm sac pressure. *J Vasc Surg*. 2007;46(2):197–203. doi:10.1016/j.jvs.2007.04.016
15. Shawn Skillern C, Stevens SL, Piercy KT, Donnell RL, Freeman MB, Goldman MH. Endotension in an experimental aneurysm model. *J Vasc Surg*. 2002;36(4):814–817. <https://doi.org/10.1067/mva.2002.127520>
16. Chaudhuri A, Ansdell LE, Grass AJ, Adiseshiah M. Intracystic pressure waveforms after endovascular aneurysm repair (EVAR) are a reliable marker of type I endoleaks, but not type II or combined types: An experimental study. *Eur J Vasc Endovasc Surg*. 2004;28(4):373–378. doi:10.1016/j.ejvs.2004.07.006