

# Immunoexpression of RANK, RANKL and OPG in sporadic odontogenic keratocysts and their potential association with recurrence

Konrad Kisielowski<sup>1,A–D,F</sup>, Bogna Drozdowska<sup>2,A,C,E,F</sup>, Rafał Koszowski<sup>3,A–C,E,F</sup>, Magdalena Rynkiewicz<sup>2,B,C,E</sup>, Mariusz Szuta<sup>1,C–F</sup>, Mansur Rahnama<sup>4,C,E,F</sup>, Karolina Babiuch<sup>5,C,E</sup>, Michał Tyrakowski<sup>1,C,E</sup>, Anna Bednarczyk<sup>1,C,E</sup>, Tomasz Kaczmarzyk<sup>1,A–D,F</sup>

<sup>1</sup> Department of Oral Surgery, Jagiellonian University Medical College, Kraków, Poland

<sup>2</sup> Department of Pathomorphology, Faculty of Medical Sciences in Zabrze, Medical University of Silesia, Poland

<sup>3</sup> Academic Centre of Dentistry and Specialized Medicine in Bytom, Poland

<sup>4</sup> Department of Oral Surgery, Medical University of Lublin, Poland

<sup>5</sup> Chair of Periodontics and Oral Medicine, Jagiellonian University Medical College, Kraków, Poland

A – research concept and design; B – collection and/or assembly of data; C – data analysis and interpretation;

D – writing the article; E – critical revision of the article; F – final approval of the article

Advances in Clinical and Experimental Medicine, ISSN 1899–5276 (print), ISSN 2451–2680 (online)

*Adv Clin Exp Med.* 2021;30(3):301–307

## Address for correspondence

Mariusz Szuta

E-mail: mariusz.szuta@uj.edu.pl

## Funding sources

The study was supported by a grant from the Medical University of Silesia, Poland.

## Conflict of interest

None declared

Received on October 22, 2020

Reviewed on November 17, 2020

Accepted on November 26, 2020

Published online on March 25, 2021

## Cite as

Kisielowski K, Drozdowska B, Koszowski R, et al. Immunoexpression of RANK, RANKL and OPG in sporadic odontogenic keratocysts and their potential association with recurrence. *Adv Clin Exp Med.* 2021;30(3):301–307. doi:10.17219/acem/130907

## DOI

10.17219/acem/130907

## Copyright

© 2021 by Wrocław Medical University

This is an article distributed under the terms of the Creative Commons Attribution 3.0 Unported (CC BY 3.0) (<https://creativecommons.org/licenses/by/3.0/>)

## Abstract

**Background.** Odontogenic keratocysts (OKCs) are clinically aggressive lesions with relatively high recurrence rates. Dysregulation of functional equilibrium in the RANK/RANKL/OPG system is responsible for osteolysis associated with the development of OKCs. Previously published findings imply that immunoexpression of these 3 proteins may correlate with bone resorption activity in OKCs.

**Objectives.** The rationale behind this study was to assess the potential for receptor activator of nuclear factor kappa-B (RANK), receptor activator of nuclear factor kappa-B ligand (RANKL) and osteoprotegerin (OPG) expression, as well as RANKL/OPG expression ratio, to serve as prognostic indicators for OKC recurrence.

**Materials and methods.** We investigated the immunoexpression patterns of RANK, RANKL and OPG, and their correlation with recurrence rates, in 41 patients with OKCs treated with enucleation.

**Results.** We found no statistically significant differences between recurrent and non-recurrent cysts in terms of either: epithelial ( $p = 0.404$ ) and stromal ( $p = 0.469$ ) immunoreactivity of RANK; epithelial ( $p = 0.649$ ) and stromal ( $p = 0.198$ ) immunoreactivity of RANKL; or epithelial ( $p = 1$ ) and stromal ( $p = 0.604$ ) immunoreactivity of OPG. We also did not find significant differences in the distribution of cases with respect to ratios of RANKL/OPG immunostaining scores between recurrent and non-recurrent OKCs, both in the epithelium and in the connective tissue ( $p = 1$  and  $p = 0.237$ , respectively).

**Conclusions.** Our results suggest that immunoexpression levels of RANK, RANKL and OPG at the time of pathological diagnosis, as well as the RANKL/OPG ratio, are not useful as prognostic markers for OKC recurrence.

**Key words:** OPG, RANK, RANKL, odontogenic keratocyst, keratocystic odontogenic tumor

## Background

Several histopathologically benign odontogenic tumors, including keratocystic odontogenic tumor (KCOT), ameloblastoma (AM), ameloblastic fibroma (AF), and odontogenic myxoma (OM), exhibit clinically aggressive progression with a tendency towards infiltrative growth. Recently, the World Health Organization (WHO) reclassified KCOT from the tumor category into the cyst category as odontogenic keratocyst (OKC).<sup>1</sup> However, published reports stress the significance of its aggressive growth and relatively high recurrence rate (approx. 25%).<sup>2,3</sup> Many attempts have been made to elucidate the biological mechanisms of OKC onset and development, and investigators have also evaluated various molecular markers as indicators of the potential for OKC to relapse. It has been suggested that expression of epithelial cell proliferation and apoptosis markers might be correlated with propensity for OKC recurrence, but these results are ambiguous. In our recent report, we demonstrated that expression levels of COX-2 (cyclooxygenase-2), BCL-2 (B-cell lymphoma 2), PCNA (proliferating cell nuclear antigen), and tumor protein p53 are not associated with OKC recurrence.<sup>4</sup> Thus, it is essential to continue to investigate other molecular factors in the search for prognostic candidates.

One key event responsible for the aggressiveness and progression of intraosseous lesions is bone resorption, which mainly depends on the formation and activation of osteoclasts.<sup>5</sup> Under physiological conditions, there is a delicate balance between the activities of osteoblasts and osteoclasts, through which the bone tissue is subjected to continuous remodeling.<sup>6–8</sup> Two members of the tumor necrosis factor (TNF) receptor superfamily, RANK (receptor activator of nuclear factor kappa-B) and RANKL (receptor activator of nuclear factor kappa-B ligand), are critical regulators of the bone remodeling process.<sup>7,9,10</sup> In vitro, the RANK/RANKL signaling pathway, together with macrophage colony-stimulation factor, promotes osteoclast differentiation from blood-born hemopoietic precursors, whereas the addition of the soluble receptor osteoprotegerin (OPG) into these culture systems prevents osteoclastogenesis.<sup>11</sup> Osteoprotegerin binds directly to RANKL and interrupts the activation of osteoclasts.<sup>12</sup> Hence, the balance between OPG and RANKL regulates bone resorption and formation.<sup>3,8</sup> The upregulation of RANKL and the downregulation of OPG are involved in various bone-associated diseases, including osteoporosis,<sup>13</sup> rheumatoid arthritis<sup>14</sup> and bone hereditary pathia.<sup>15</sup> This expression pattern also has a role in various bone tumors, including primary malignancies, such as multiple myeloma<sup>16</sup> and osteosarcoma,<sup>17</sup> as well as soft tissue malignant tumors with secondary bone invasion by metastasis<sup>7</sup> or direct infiltration.<sup>11</sup>

Several studies have demonstrated expression of RANK, RANKL and OPG in the epithelium and stroma of some odontogenic cysts and tumors, including OKC,<sup>5,12</sup> AM,<sup>5,12,18</sup> AF,<sup>19</sup> OM,<sup>19</sup> radicular cyst (RC),<sup>5,20</sup> and dentigerous cyst

(DC).<sup>5,12</sup> In 2013, de Matos et al.<sup>5</sup> suggested that higher immunodetection of RANKL and lower immunodetection of OPG could indicate greater bone and tooth resorption activity in OKC and AM in comparison with RC and DC, which present indolent clinical behavior. Likewise, Tekkesin et al.<sup>3</sup> revealed a greater number of RANK-positive cells in the epithelial component of OKC and AM than in RC. This may indicate that greater bone/tooth resorption activity occurs in OKC and AM as compared to RC, which is consistent with the clinical presentation of these lesions. However, little is known about the prognostic value of RANK, RANKL and OPG expression (as measured with immunohistochemical staining) in aggressive odontogenic lesions. Therefore, the aim of this study was to investigate the potential for RANK, RANKL and OPG expression, as well as the balance between levels of RANKL and OPG, as prognostic markers in patients with OKC.

## Materials and methods

### Samples

Original hematoxylin-and-eosin (H&E)-stained slides and formalin-fixed, paraffin-embedded specimen blocks representing 41 cases of OKC were retrieved from the archives of the Chair of Pathomorphology at the Jagiellonian University Medical College, Kraków, Poland, and the Chair of Pathomorphology of the Medical University of Silesia, Zabrze, Poland. The OKCs had been surgically removed from 20 females and 21 males, with a mean age of 40.24 ( $\pm 18.3$ ) years at the time of surgery. All lesions were treated between 1997 and 2015 at the Department of Oral Surgery at the Jagiellonian University Medical College or at the Academic Center of Dentistry and Specialized Medicine in Bytom, Poland. In all cases, surgical enucleation of the lesion was conducted by careful removal of the cyst lining, followed by primary closure. No bone regeneration graft materials were applied. Surgical technique was standardized between surgeons performing enucleation. Subjects with nevroid basal cell carcinoma syndrome (NBCCS)-associated OKCs were not included in this analysis. The recurrence period was defined as the time between diagnosis of the primary lesion and the time of detection of any recurrent lesion in the same location that was subsequently histopathologically confirmed to meet the WHO (2017) microscopic criteria for OKC.

### Immunohistochemistry

Formalin-fixed, paraffin-embedded archival blocks were sectioned and stained with H&E. Slides with 5- $\mu$ m thick tissue sections were used to confirm a diagnosis of OKC using a light microscope.

For immunohistochemical analysis, paraffin-embedded, 3- $\mu$ m thick tissue sections were placed on salinized slides.

Samples were deparaffinized with xylene, rehydrated in graded alcohol and washed in deionized water. Antigen retrieval was performed by heating slides in Heat-Induced Epitope Retrieval Buffer (Thermo Scientific, Fremont, USA), at pH 6 or pH 9, for 20 min at 95°C. Sections were then blocked by incubation with 3% H<sub>2</sub>O<sub>2</sub> and protein block (Thermo Scientific), and then slides were incubated overnight in a humidified chamber at 4°C with one of the following antibodies:

- mouse monoclonal anti-RANK (ab13918; Abcam Inc., Cambridge, USA; diluted 1:200);
- rabbit polyclonal anti-RANKL (ab169966; Abcam; 1:400);
- rabbit polyclonal anti-OPG (ab183910; Abcam; 1:400).

After washing in Tris-buffered saline (TBS), sections were treated according to the manufacturer's instructions with the Primary Antibody Amplifier Quanto system, followed by the HRP Polymer Quanto system (both Thermo Scientific). Slides were stained using a 3-3'-diaminobenzidine (DAB) Quanto kit (Thermo Scientific). Finally, tissue sections were counterstained with hematoxylin, dehydrated, and covered with coverslips for further analysis. A case of central giant cell granuloma was used as the positive control for expression of RANK, RANKL and OPG. For the negative control, sections were treated as above, but without primary antibody exposure. Cellular staining patterns for RANK, RANKL and OPG in the epithelium and stroma of OKC were cytoplasmic.

Semiquantitative assessment was conducted using a four-point scoring system:

- grade 0 (no reaction): 0% of cells stained;
- grade 1 (weak reaction): 1–25% of cells stained;
- grade 2 (moderate reaction): 26–50% of cells stained;
- grade 3 (strong reaction): >50% of cells stained.

All histopathological and immunohistochemical evaluations were made by board-certified specialists in pathomorphology.

Results were reported either as mean ( $\pm$  standard deviation (SD)), or as number of cases plus percentages, as appropriate. Differences in immunohistochemical data between recurrent and non-recurrent OKCs were analyzed using Fisher's exact test. The Cox proportional hazard model for time-dependent variables was implemented to evaluate hazard ratio, and 95% confidence intervals (95% CI) were used as estimates of hazard risk for a recurrence potential. Probability values (p-values) less than 0.05 were considered significant. All analyses were performed using R statistical software (the R Project for Statistical Computing; <http://www.R-project.org/>).

## Results

The number of cases included in the analysis totaled 41. The mean time until follow-up was 8.49 ( $\pm 4.34$ ) years. Recurrences were ascertained in 12 (29.27%) cases. The mean recurrence period was 3.92 ( $\pm 2.61$ ) years.

Positive immunohistochemical staining for RANK was identified in 15 (36.58%) cases in epithelium, and in 28 (68.29%) cases in stroma. In all but 1 positive case, only a weak reaction was observed. We did not find a single OKC case exhibiting a strong response for RANK within both epithelial and stromal components. There were no statistically significant differences between recurrent and non-recurrent cysts in terms of epithelial ( $p = 0.404$ ) or stromal immunoreactivity to RANK ( $p = 0.469$ ) (Table 1). Representative immunohistochemical images are shown in Fig. 1 and 2.

With respect to RANKL, all cases of OKCs were positive for expression within the epithelium, and all but 1 case also showed expression in the cystic connective tissue (Table 1). Epithelial samples exhibited moderate-to-strong reactions in 85.36% of cases, whereas stromal reactions were mostly weak (51.2% of cases) (Fig. 3). There were no statistically significant differences between recurrent and non-recurrent cysts in terms of epithelial ( $p = 0.649$ ) or stromal immunoreactivity to RANKL ( $p = 0.198$ ) (Table 1).

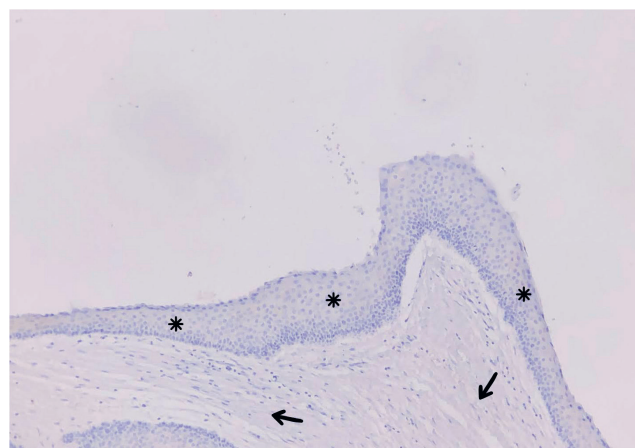


Fig. 1. Immunohistochemical reaction for RANK: no cytoplasmic staining in epithelium (\*) no reaction) or in stroma (→ no reaction) (×100 magnification)

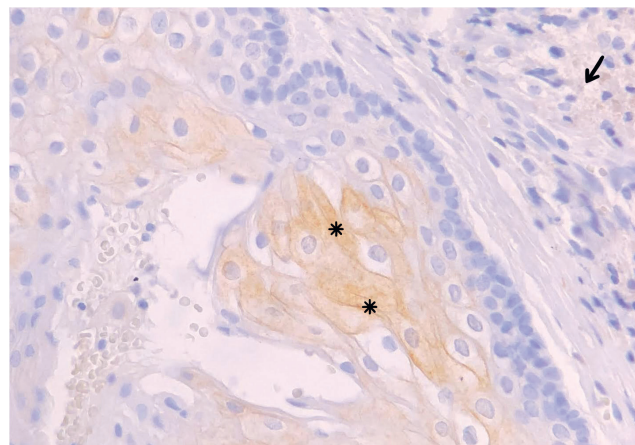


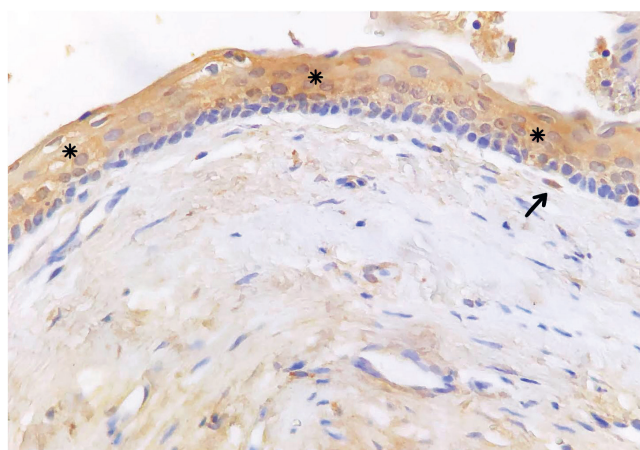
Fig. 2. Immunohistochemical reaction for RANK: cytoplasmic brown staining in epithelium (\*) weak reaction) and no staining in stroma (→ no reaction) (×200 magnification)



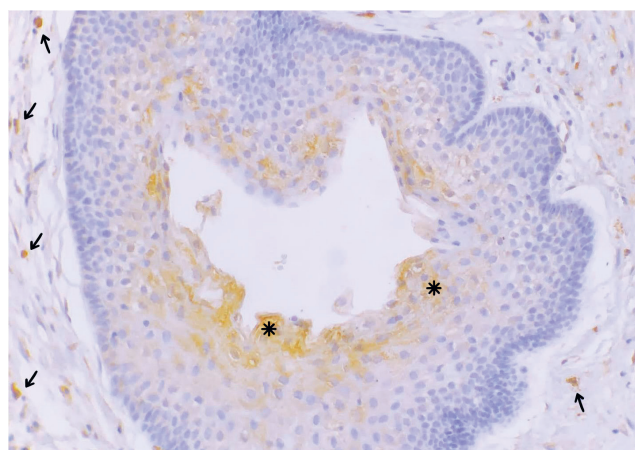
**Table 1.** Histopathological characteristics of cases, with hazard risks for recurrence of OKCs

Immuno-localization	Immunostain		Recurrent cysts (n = 12)		Non-recurrent cysts (n = 29)		p-value (Fisher's exact test)	Cox proportional hazard model	
	protein	type of reaction	n	%	n	%		HR (95% CI)	p-value
Epithelium	RANK	none	7	58.33%	19	65.52%	0.404	1.00	
		weak	4	33.33%	10	34.48%		0.917 [0.268–3.139]	0.891
		moderate	1	8.33%	0	0.00%		4.040 [0.488–33.435]	0.195
		strong	0	0.00%	0	0.00%		NA	
	RANKL	none	0	0.00%	0	0.00%	0.649	NA	
		weak	1	8.33%	5	17.24%		1.00	
		moderate	4	33.33%	12	41.38%		1.671 [0.187–14.963]	0.646
		strong	7	58.33%	12	41.38%		2.515 [0.309–20.451]	0.388
	OPG	none	1	8.33%	2	6.90%	1	1.00	
		weak	8	66.67%	19	65.52%		0.944 [0.118–7.559]	0.957
		moderate	1	8.33%	4	13.79%		0.606 [0.038–9.722]	0.724
		strong	2	16.67%	4	13.79%		0.856 [0.077–9.492]	0.899
Stroma	RANK	none	5	41.67%	8	27.59%	0.469	1.00	
		weak	7	58.33%	21	72.41%		0.633 [0.201–1.996]	0.435
		moderate	0	0.00%	0	0.00%		NA	
		strong	0	0.00%	0	0.00%		NA	
	RANKL	none	0	0.00%	1	3.45%	0.198	NR	
		weak	7	58.33%	14	48.28%		0.449 [0.116–1.743]	0.247
		moderate	2	16.67%	12	41.38%		0.169 [0.028–1.022]	0.053
		strong	3	25.00%	2	6.90%		1.00	
	OPG	none	1	8.33%	2	6.90%	0.604	1.00	
		weak	5	41.67%	18	62.07%		0.613 [0.071–5.252]	0.655
		moderate	4	33.33%	7	24.14%		1.140 [0.127–10.226]	0.907
		strong	2	16.67%	2	6.90%		1.356 [0.123–14.981]	0.804

OKCs – odontogenic keratocysts; RANK – receptor activator of nuclear factor kappa-B; RANKL – receptor activator of nuclear factor kappa-B ligand; OPG – osteoprotegerin; NR – no recurrence; NA – not applicable; HR – hazard ratio; 95% CI – 95% confidence interval.



**Fig. 3.** Immunohistochemical reaction for RANKL: cytoplasmic brown staining in epithelium (\* strong reaction) and in stroma (→ weak reaction) (×150 magnification)



**Fig. 4.** Immunohistochemical reaction for OPG: cytoplasmic brown staining in epithelium (\* weak reaction) and in stroma (→ moderate reaction) (×150 magnification)

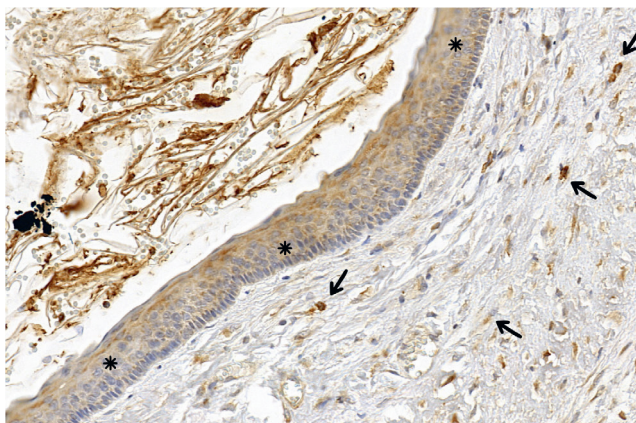
Immunoreactivity to OPG was observed in 92.68% of OKCs both within the epithelium and within the stroma. Epithelial expression of OPG was mostly weak, as found

in 27 cases (65.85%), as was stromal expression, which was weak in 23 cases (56.09%). There were no statistically significant differences between recurrent and non-recurrent

**Table 2.** RANKL/OPG ratio of immunostaining scores between recurrent and non-recurrent OKCs

Immuno-localization	RANKL/OPG ratio	Recurrent cysts (n = 12)	Non-recurrent cysts (n = 29)	Total (n = 41)	p-value (Fisher's exact test)	Cox proportional hazard model	
		n (%)	n (%)	n (%)		HR (95% CI)	p-value
Epithelium	RANKL > OPG	8 (66.67%)	19 (65.52%)	27 (65.86%)	1.00	1.00	0.997
	RANKL = OPG	4 (33.33%)	8 (27.59%)	12 (29.27%)		0.997 [0.3–3.316]	
	RANKL < OPG	0 (0.00%)	2 (6.90%)	2 (4.87%)		NR	
Stroma	RANKL > OPG	5 (41.67%)	10 (34.48%)	15 (36.59%)	0.237	1.00	0.254
	RANKL = OPG	3 (25.00%)	15 (51.72%)	18 (43.90%)		0.435 [0.104–1.821]	
	RANKL < OPG	4 (33.33%)	4 (13.79%)	8 (19.51%)		1.548 [0.415–5.772]	

RANKL – receptor activator of nuclear factor kappa-B ligand; OPG – osteoprotegerin; NR – no recurrence; HR – hazard ratio; 95% CI – 95% confidence interval.



**Fig. 5.** Immunohistochemical reaction for OPG: cytoplasmic brown staining in epithelium (\* moderate reaction) and in stroma (→ moderate reaction) (×150 magnification)

cysts in terms of epithelial ( $p = 1$ ) or stromal immunoreactivity to OPG ( $p = 0.604$ ) (Table 1). Representative immunohistochemical images are shown in Fig. 4 and 5.

We did not find any significant differences in the distribution of cases with respect to the ratio of RANKL/OPG immunostaining scores between recurrent and non-recurrent OKCs. This was true of both the epithelium and the connective tissue ( $p = 1$  and  $p = 0.237$ , respectively) (Table 2). Within the epithelial subset, most cases (65.86%) demonstrated higher immunoreactivity to RANKL than OPG, whereas within the stromal component, most cases demonstrated uniform immunoreactivity to each marker (43.90%) (Table 2). We therefore did not identify any prognostic significance of the RANKL/OPG ratio in either cystic component (Table 2).

## Discussion

Bone is a tissue that is continuously being rebuilt and remodeled.<sup>7</sup> Two types of cells are involved in this process: osteoblasts – bone building cells that deposit new bone tissue, and osteoclasts – bone-resorbing cells responsible for breaking tissue down. The RANK, RANKL and

OPG proteins are critical for the control of osteoclastogenesis and pathophysiological bone remodeling. Osteoprotegerin is a decoy receptor for RANKL that blocks osteoclast formation by inhibiting RANKL from binding to RANK.<sup>3,21</sup>

The dysregulation of functional equilibrium in the RANK/RANKL/OPG system is responsible for osteolysis associated with the development of intraosseous odontogenic lesions, including AM, OKC, DC, and RC, to name but a few.<sup>3,5,12</sup> Various lesions exhibit different levels of aggressiveness and tendency towards infiltrative growth. Accordingly, we attempted to elucidate a relationship between level of clinical aggressiveness and modulated expression of RANK, RANKL and OPG in the epithelial and stromal components of lesions.

Most previous studies have compared the immun-expression levels of these markers across various lesions exhibiting different levels of clinical aggressiveness. In particular, the results of disturbances in the RANK/RANKL/OPG triad were compared between AM, OKC, DC, and/or RC pathologies.<sup>3,5,12</sup> From a comparative point of view, AM represents a locally aggressive odontogenic neoplasm with a high tendency to infiltrative growth and recurrence, with OKC (previously also classified as neoplasm) representing a cystic lesion with a moderate potential for destructive growth and infiltrative growth, and both DC and RC as benign odontogenic cysts with relatively little tendency for local destruction. Tekkesin et al.<sup>3</sup> found a greater number of RANK-positive cells in OKCs than in AM or RC (in both epithelial and stromal lesion components) as well as a greater number of RANK-positive cells in AM than in RC (but only in epithelial tissue). The expression of RANKL was similar (strong) in both components of all 3 types of lesion. Moreover, all lesions showed very low expression of OPG.<sup>3</sup> The authors concluded that the variable most strongly determining osteoclastogenesis was RANK expression, since it was upregulated in lesions exhibiting aggressive behavior (AM and OKC) as compared with benign RC.<sup>3</sup>

Surprisingly, we did not find even 1 case of OKC exhibiting strong expression of RANK within either epithelial or stromal components. In fact, most cases presented with

a negative RANK-reaction in epithelial tissue, and merely weak reactions within stroma. The reasons for the discrepancy between our findings and those of Tekkesin et al.<sup>3</sup> are obscure. It is likely that the different antibodies and methods used for immunohistochemical analyses are a contributing factor. We also did not include syndromic cases, which may exhibit higher local aggressiveness,<sup>22</sup> in our investigation.

In this study, the majority of OKC cases exhibited positive immunoexpression of RANKL. Specifically, epithelial components showed moderate to strong reactions in as many as 85.4% cases. These findings are in line with those of de Matos et al.,<sup>5</sup> who revealed higher expression of RANKL in the epithelium of AM and OKC than in RC and DC, deducing that increased epithelial expression of RANKL would be related to elevated osteoclast activity, thus favoring bone resorption.<sup>5</sup> Moreover, in the present study, most cases exhibited merely weak immunohistoactivity for OPG in both cystic components. The downregulation of OPG may also suggest elevated osteolytic activity, since lack of this molecule allows for interaction between RANK and RANKL, thereby promoting bone resorption. Accordingly, our findings suggest that it is strong expression of RANKL accompanied by weak expression of OPG that may facilitate the local aggressiveness of OKC.

Interestingly, elevated RANKL/OPG ratios were mostly found in the epithelial rather than the stromal components. This suggests that osteolytic activity of OKC may be related to the epithelium of the lesion rather than its capsule. Some previous studies hypothesized that the expansive potential of OKC is most likely explained by increased RANK and RANKL activity in the lesional connective tissue, as indicated by higher immunoreactivity levels. It was suggested that this might have indirectly indicated the presence in the lesion capsule of osteoclast precursors that are able to interact with the receptor, leading to osteoclast differentiation and maturation.<sup>23,24</sup> Our findings, however, do not corroborate this hypothesis, and are in line with results of the study by da Silva,<sup>12</sup> who also found that the stroma of OKCs contained a higher number of OPG-positive cells than RANKL-positive cells. Hence, it is likely that enhanced epithelial expression of RANKL and/or decreased levels of OPG play an important role in cyst-associated bone destruction (which was also suggested by da Silva<sup>12</sup>).

## Limitations

To the best of our knowledge, the present study was the first to evaluate immunoexpression levels of RANK, RANKL and OPG in the epithelium and stroma of OKCs as potential prognostic markers for recurrence. We did not, however, demonstrate any significant association between cyst relapse and levels of these immunostains. Likewise, RANKL/OPG ratios in both histological components

of OKC were not correlated with recurrence. Although RANK, RANKL and OPG are critical for osteoclastogenesis, and although levels of their immunoexpression may be associated with local aggressiveness of intraosseous lesions, our findings suggest that they would not serve as useful prognostic indicators of OKC relapse.

There are other markers of local OKC invasiveness involved in bone metabolism and cyst progression. Among them, podoplanin, osteopontin and its receptors CD44v6 and integrin  $\alpha_v$  have recently generated much research interest<sup>25</sup>; however, their relevance in terms of OKC recurrence is still unknown. It is also possible that the immunoreactivity of the bone reabsorption regulators studied here (RANK/RANKL/OPG) should be measured along with that of proteins which participate in epithelial invasion into the cyst capsule and into adjacent structures (e.g., CD138).<sup>26</sup>

## Conclusions

The results presented here suggest that immunoexpression levels of RANK, RANKL and OPG at the time of pathological diagnosis, as well as RANKL/OPG ratio, are not useful as prognostic indicators of OKC recurrence. The local aggressiveness of OKCs may be related to upregulation of RANKL and downregulation of OPG in the cystic epithelium. Further investigation is necessary to identify the precise molecular factors behind OKC relapse.

## ORCID iDs

Konrad Kisielowski  <https://orcid.org/0000-0001-7894-0105>  
 Bogna Drozdowska  <https://orcid.org/0000-0002-2287-6842>  
 Rafał Koszowski  <https://orcid.org/0000-0002-9533-549X>  
 Magdalena Rynkiewicz  <https://orcid.org/0000-0001-8002-7366>  
 Mariusz Szuta  <https://orcid.org/0000-0002-7182-4811>  
 Mansur Rahnema  <https://orcid.org/0000-0002-5622-7330>  
 Karolina Babiuch  <https://orcid.org/0000-0001-8899-9880>  
 Michał Tyrakowski  <https://orcid.org/0000-0002-7669-9650>  
 Anna Bednarczyk  <https://orcid.org/0000-0001-9891-0157>  
 Tomasz Kaczmarzyk  <https://orcid.org/0000-0003-3024-9926>

## References

1. Wright JM, Vered M. Update from the 4<sup>th</sup> Edition of the World Health Organization Classification of Head and Neck tumours: Odontogenic and maxillofacial bone tumours. *Head Neck Pathol.* 2017;11(1):68–77. doi:10.1007/s12105-017-0794-1
2. Shear M, Speight PM. *Cysts of the Oral and Maxillofacial Regions*. 4<sup>th</sup> ed. Hoboken, NJ: Wiley-Blackwell; 2009:6–58.
3. Tekkesin MS, Mutlu S, Olgac V. The role of RANK/RANKL/OPG signaling pathways in osteoclastogenesis in odontogenic keratocysts, radicular cysts, and ameloblastomas. *Head Neck Pathol.* 2011;5(3):248–253. doi:10.1007/s12105-011-0271-1
4. Kaczmarzyk T, Kisielowski K, Koszowski R, et al. Investigation of clinicopathological parameters and expression of COX-2, bcl-2, PCNA, and p53 in primary and recurrent odontogenic keratocysts. *Clin Oral Investig.* 2018;22(9):3097–3106. doi:10.1007/s00784-018-2400-7
5. de Matos FR, de Moraes M, das Neves Silva EB, Galvão HC, de Almeida Freitas R. Immunohistochemical detection of receptor activator nuclear  $\kappa$ B ligand and osteoprotegerin in odontogenic cysts and tumors. *J Oral Maxillofac Surg.* 2013;71(11):1888–1892. doi:10.1016/j.joms.2013.05.023



6. Charles JF, Aliprantis AO. Osteoclasts: More than “bone eater”. *Trends Mol Med*. 2014;20(8):449–459. doi:10.1016/j.molmed.2014.06.001
7. Sigl V, Jones LP, Penninger JM. RANKL/RANK: From bone loss to the prevention of breast cancer. *Open Biol*. 2016;6(11):160230. doi:10.1098/rsob.160230
8. Rahnema M, Jastrzebska-Jamrogiewicz I, Jamrogiewicz R, Nogalski A, Jagielak M. Influence of hormone replacement therapy on osteoprotegerin and receptor activator of nuclear factor kappa-B ligand concentrations in menopausal women. *J Interferon Cytokine Res*. 2013;33(9):485–492. doi:10.1089/jir.2012.0149
9. Dougall WC, Glaccum M, Charrier K, et al. RANK is essential for osteoclast and lymph node development. *Genes Dev*. 1999;13(18):2412–2424. doi:10.1101/gad.13.18.2412
10. Kong YY, Yoshida H, Sarosi I, et al. OPGL is a key regulator of osteoclastogenesis, lymphocyte development and lymph-node organogenesis. *Nature*. 1999;397(6717):315–323. doi:10.1038/16852
11. Jimi E, Shin M, Furuta H, Tada Y, Kusakawa J. The RANKL/RANK system as a therapeutic target for bone invasion by oral squamous cell carcinoma (review). *Int J Oncol*. 2013;42(3):803–809. doi:10.3892/ijo.2013.1794
12. da Silva TA, Batista AC, Mendonça EF, Leles CR, Fukada S, Cunha FQ. Comparative expression of RANK, RANKL, and OPG in keratocystic odontogenic tumors, ameloblastomas and dentigerous cysts. *Oral Surg Oral Med Oral Pathol Oral Radiol Endod*. 2008;105(3):333–341. doi:10.1016/j.tripleo.2007.06.009
13. Vega D, Maalouf NM, Sakhaee K. The role of receptor activator of nuclear factor- $\kappa$ B (RANK)/RANK ligand/osteoprotegerin: Clinical implications. *J Clin Endocrinol Metab*. 2007;92(12):4514–4521. doi:10.1210/jc.2007-0646
14. Pettit A, Walsh N, Manning C, Goldring S, Gravallese E. RANKL protein is expressed at the pannus–bone interface at sites of articular bone erosion in rheumatoid arthritis. *Rheumatol (Oxford)*. 2006;45(9):1068–1076. doi:10.1093/rheumatology/kei045
15. Sobacchi C, Frattini A, Guerrini MM, et al. Osteoclast-poor human osteopetrosis due to mutations in the gene encoding RANKL. *Nat Genet*. 2007;39(8):960–962. doi:10.1038/ng2076
16. Giuliani N, Colla S, Sala R, et al. Human myeloma cells stimulate the receptor activator of nuclear factor- $\kappa$ B ligand (RANKL) in T lymphocytes: A potential role in multiple myeloma bone disease. *Blood*. 2002;100(13):4615–4621. doi:10.1182/blood-2002-04-1121
17. Mori K, Le Goff B, Berreur M, et al. Human osteosarcoma cells express functional receptor activator of nuclear factor-kappa B. *J Pathol*. 2007;211(5):555–562. doi:10.1002/path.2140.
18. Kumamoto H, Ooya K. Expression of parathyroid hormone-related protein (PTHrP), osteoclast differentiation factor (ODF)/receptor activator of nuclear factor-kappaB ligand (RANKL) and osteoclastogenesis inhibitory factor (OCIF)/osteoprotegerin (OPG) in ameloblastomas. *J Oral Pathol Med*. 2004;33(1):46–52. doi:10.1111/j.1600-0714.2004.00204.x
19. Andrade FR, Sousa DP, Mendonça EF, da Silva TA, Lara VS, Batista AC. Expression of bone resorption regulators (RANK, RANKL, and OPG) in odontogenic tumors. *Oral Surg Oral Med Oral Pathol Oral Radiol Endod*. 2008;106(4):548–555. doi:10.1016/j.tripleo.2008.05.042
20. Menezes R, Bramante CM, da Silva Paiva KB, et al. Receptor activator NFkappaB-ligand and osteoprotegerin protein expression in human periapical cysts and granulomas. *Oral Surg Oral Med Oral Pathol Oral Radiol Endod*. 2006;102(3):404–409. doi:10.1016/j.tripleo.2005.10.054
21. Suda T, Takahashi N, Udagawa N, Jimi E, Gillespie MT, Martin TJ. Modulation of osteoclast differentiation and function by the new members of the tumor necrosis factor receptor and ligand families. *Endocr Rev*. 1999;20(3):345–357. doi:10.1210/edrv.20.3.0367
22. Kahraman D, Gunhan O, Celasun B. A series of 240 odontogenic keratocysts: Should we continue to use the terminology of “keratocystic odontogenic tumour” for the solid variant of odontogenic keratocyst? *J Craniomaxillofac Surg*. 2018;46(6):942–946. doi:10.1016/j.jcms.2018.04.007
23. de Moraes M, De Lucena HF, De Azevedo PR, Queiroz LM, Costa Ade L. Comparative immunohistochemical expression of RANK, RANKL and OPG in radicular and dentigerous cysts. *Arch Oral Biol*. 2011;56(11):1256–1263. doi:10.1016/j.archoralbio.2011.05.009
24. de Moraes M, de Matos FR, de Souza LB, de Almeida Freitas R, de Lisboa Lopes Costa A. Immunoexpression of RANK, RANKL, OPG, VEGF, and vWF in radicular and dentigerous cysts. *J Oral Pathol Med*. 2013;42(6):468–473. doi:10.1111/jop.12036
25. Kechik KA, Siar CH. Spatial distribution of osteopontin, CD44v6 and podoplanin in the lining epithelium of odontogenic keratocysts, and their biological relevance. *Ann Diagn Pathol*. 2018;32:17–22. doi:10.1016/j.anndiagpath.2017.08.002
26. Brito-Medoza L, Bologna-Molina R, Irigoyen-Camacho ME, Martinez G, Sanchez-Romero C, Mosqueda-Taylor A. A comparison of Ki67, Syndecan-1 (CD138), and molecular RANK, RANKL, and OPG triad expression in odontogenic keratocysts, unicystic ameloblastoma, and dentigerous cysts. *Dis Markers*. 2018;2018:7048531. doi:10.1155/2018/7048531