

# CBCT and modern intraoral scanners as tools for developing comprehensive, interdisciplinary treatment plans

Wojciech Frąckiewicz<sup>B–D,F</sup>, Aleksandra Jankowska<sup>B–D,F</sup>, Monika E. Machoy<sup>A,E,F</sup>

Department of Periodontology, Faculty of Medicine and Dentistry, Pomeranian Medical University in Szczecin, Poland

A – research concept and design; B – collection and/or assembly of data; C – data analysis and interpretation;

D – writing the article; E – critical revision of the article; F – final approval of the article

Advances in Clinical and Experimental Medicine, ISSN 1899–5276 (print), ISSN 2451–2680 (online)

*Adv Clin Exp Med.* 2024;33(11):1267–1276

## Address for correspondence

Monika E. Machoy

E-mail: m.machoy@gmail.com

## Funding sources

None declared

## Conflict of interest

None declared

Received on June 5, 2023

Reviewed on August 6, 2023

Accepted on November 24, 2023

Published online on February 20, 2024

## Abstract

The aim of this narrative literature review is to present the possibilities of using cone beam computed tomography (CBCT) and 3D dental scanners to prepare comprehensive, interdisciplinary treatment plans. Scanners are instruments whose usage seems to be a key element of modern digital dentistry. Their importance in orthodontic treatment with overlay appliances, planning modern prosthetic treatments (CAD/CAM) and implantology cannot be overestimated. These scanners allow for accurate imaging of the tooth structures and their positioning independently in the maxilla and mandible as well as in the occlusion. As a result, dentists can plan treatment, e.g., in the case of the need to implant dental implants, prosthetic crowns or orthodontic braces. Dentistry was revolutionized to a similar extent by the introduction of CBCT to everyday diagnostics, which is the most advanced imaging technology that provides even more detailed images in 3 dimensions. Its use has enabled a wider and more precise range of diagnostics, which in turn has improved the quality of multidisciplinary treatment planning. This paper explains how scanners and CBCT can be used in orthodontics and prosthetics based on the articles found in 3 databases: PubMed, Scopus and Embase. The review included 28 articles on the aforementioned topics and was presented with a brief description of the content of each article.

**Key words:** orthodontics, prosthodontics, CBCT, scanners, modern dentistry

## Cite as

Frąckiewicz W, Jankowska A, Machoy ME. CBCT and modern intraoral scanners as tools for developing comprehensive, interdisciplinary treatment plans. *Adv Clin Exp Med.* 2024;33(11):1267–1276. doi:10.17219/acem/175817

## DOI

10.17219/acem/175817

## Copyright

Copyright by Author(s)

This is an article distributed under the terms of the Creative Commons Attribution 3.0 Unported (CC BY 3.0) (<https://creativecommons.org/licenses/by/3.0/>)

## Introduction

Modern dentistry provides many new tools for carrying out diagnostics allowing for the preparation of the safest, interdisciplinary treatment plans. They include, e.g., cone-beam computed tomography (CBCT) and modern intraoral scanners.<sup>1</sup>

Cone beam computed tomography can be used in almost every field of dentistry as it allows for determining the spatial conditions of the jaw bones, which is used, among others, in dental surgery, orthodontics and maxillofacial surgery, but also enables precise assessment of alveolar processes, the quality and density of their bones, the course of individual tooth structures, such as root canals, which greatly facilitates endodontic treatment or endodontic re-treatment, and also makes it possible to detect even the smallest periapical inflammatory foci or external and internal resorption<sup>2</sup>. In orthodontics, CBCT makes it possible to assess bone conditions and plan the range of possible tooth movements while avoiding complications such as fenestrations, dehiscences or recessions.<sup>3</sup>

In implant prosthetics, CBCT can be used to assess the possibility of implantation without additional procedures, such as sinus floor elevation or bone grafting, and if the procedure is necessary, to design its scope and architectonics.<sup>4</sup> After the initial planning of the implant insertion position and path, another digital element facilitating the complicated implantation procedure is the use of a Dynamic Navigation system or specially prepared surgical templates in CAD/CAM technology.<sup>5</sup> Cone beam computed tomography also increases the safety of performed procedures, allowing for precise determination of the location of individual nerve canals, which are anatomically variable.<sup>6</sup>

In addition to CBCT, 3D scanners are also widely used in today's dentistry. Intraoral scanners make it possible to reproduce the patient's occlusion without the use of impression materials.<sup>7</sup> This ensures accurate mapping of the mutual arrangement of teeth, which is necessary for proper diagnosis before orthodontic treatment and assessment of the correctness of the treatment effects, as well as minimizes the impression-taking procedure, which is unpleasant for patients. As a result, it is also possible to avoid distortions in models cast from impressions, when they are stored under inappropriate physical conditions. Owing to scanners, this problem can also be eliminated in prosthetics. They enable to accurately map the tooth preparation border for permanent restorations (inlays, onlays, crowns) directly in the patient's oral cavity, or indirectly, by applying extraoral scanners used in prosthetic laboratories.<sup>8</sup> Using special computer software, it is possible to determine the insertion path, and then fabricate the finished prosthetic appliance (e.g., in CAD/CAM technology) and transfer it into the patient's mouth.

Nowadays, CBCT and scanners are auxiliary tools commonly used in various fields of dentistry, which is the aim

of this article. It presents their principles, types, and applications based on academic knowledge and provides the current knowledge contained in articles from the last 5 years available in the US National Library of Medicine National Institutes of Health (PubMed), as well as Scopus and Web of Science databases. The last search was performed on May 10, 2023. Two authors selected and described the articles (WF, AJ), and the 3<sup>rd</sup> author reviewed them in accordance with the guidelines (MM). The results of their review are presented later in the article.

## Objectives

The aim of this study was to present the advantages and possibilities of using CBCT and intraoral scanners in clinical practice during dental procedures, to show their usefulness in planning prosthetic and orthodontic procedures as a tool of modern digital dentistry.

## Materials and methods

The present systematic review was conducted in accordance with the Preferred Reporting Items for Systematic Reviews and Meta-Analyses (PRISMA) statement.<sup>9</sup> The study took into account articles from 3 databases: PubMed, Scopus and Web of Science. The initial search took place on March 15, 2023, and included a total of 421 articles. After removing duplicates, 273 articles advanced to the next stage. Articles had to meet criteria such as being written in English and not being older than 5 years. After a deeper analysis, 214 articles were excluded due to a topic other than the main one discussed by the authors. Overall, 28 articles were included for the final description in the review if they met all the criteria, i.e., they referred to CBCT and/or dental scanners used in dentistry. A PRISMA 2022 Flow Diagram representing the study selection process is presented in Fig. 1.

## Cone beam tomography in dentistry

It is very interesting to observe how innovative technologies are increasingly applied in dentistry and orthodontics. Cone beam computed tomography, in particular, is becoming the imaging technique of choice in comprehensive orthodontic treatment.<sup>10</sup>

Over the past 2 decades, CBCT, a versatile 3D X-ray imaging technique, has become increasingly popular in the field of dental radiology.<sup>11</sup> Since the development of the first CBCT device specifically for maxillofacial imaging in 1998, the variety of models has increased significantly, especially in the last 10 years.<sup>12</sup>

The CBCT technology uses a conical source of ionizing radiation and a 2-dimensional (2D) monitor.<sup>13</sup> It offers

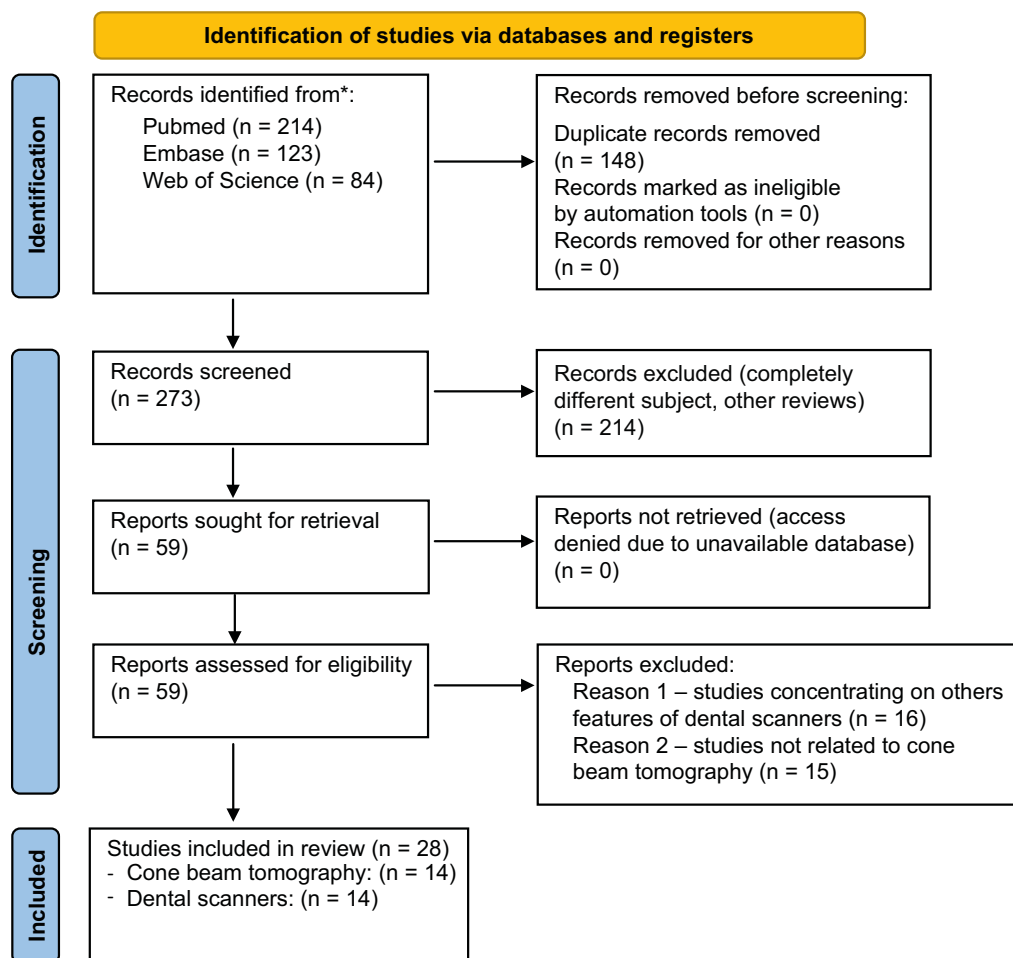


Fig. 1. Search strategy – Preferred Reporting Items for Systematic Reviews and Meta-Analyses (PRISMA) flow diagram

dimensionally accurate multi-dimensional images for diagnosis and treatment planning. The isotropic voxels (volume elements) in these images provide accurate multiplanar images in any direction.<sup>14</sup> Each volume element has equal dimensions in each of the 3 perpendicular planes.

## Principles of CBCT

The principle of CBCT scanning is based on the rotation of a gantry with an X-ray tube and an image detector. The X-ray cone beam is attenuated by the patient's tissues and the imaging area is exposed during scanning. Partial tissue exposure occurs in a rotating region around the imaging area, as the X-ray beam cone sweeps the necessary angular range to obtain the raw projection images used to reconstruct the final 3D CBCT images.<sup>15</sup>

Radiation doses from CBCT devices can be determined using an optically stimulated luminescence dosimeter (OSLD) or the Monte Carlo method. In the first method, a phantom simulating human body tissues in the maxillo-facial area was equipped with OSLD and subjected to 4 different test conditions using 2 different devices. The irradiated portion of the skin, lymph nodes and muscles

of the head and neck area was estimated to be 5%, and the irradiated portion of the esophagus was estimated at 10%. In both cases, the oral mucosa and salivary glands were the most frequently irradiated organs.<sup>16</sup>

## The use of CBCT in prosthetics and orthodontics

The digitization of orthodontic and prosthetics procedures is increasing due to the use of the latest technologies. Currently, better and more individualized treatment planning is possible, largely due to the use of overlays, digital dental models and wider access to CBCT images.<sup>17</sup>

In addition, CBCT offers applications for surgical procedures, such as conducting CT scans with computer-generated surgical templates used in implant prosthetics, as well as enhanced in-office diagnostic capabilities. Current practice requires a thorough understanding of the basics of CBCT science and the ability to accurately and fully interpret images.<sup>18</sup>

The tables below summarize the potential applications and current knowledge on some types and selected properties of CBCT, which is increasingly used in dental prosthetics (Table 1) and orthodontics (Table 2).

**Table 1.** The use of cone beam computed tomography in prosthodontics in the last 5 years of publications

Number	Author and year	Title	Significance
1.	Al-Humairi et al., 2022 <sup>19</sup>	Visual grading experiments and optimization in CBCT dental implantology imaging: Preliminary application of integrated visual grading regression	Optimization of the radiation dose used in the examination in dental implantology – CBCT was used as a tool for visualizing a human skull phantom using a real skull as bone and a plexiglass-like material as soft tissues. Using integrated visual grading regression (IVGR), it was assessed whether it was possible to reduce the amount of radiation during the examination without significantly affecting the image quality. The dose reduction was estimated at 31%, proving that IVGR can be an effective tool to determine reduction not only in CBCT but also in computed tomography (CT) – but more research is needed to confirm it.
2.	Chandran et al., 2022 <sup>20</sup>	Guided implant surgery with R2Gate®: A multicenter retrospective clinical study with 1 year of follow-up	Cone beam computed tomography was used to study the patient's anatomy and bone condition before planning implant treatment. The prosthetic laboratory, based on Digital Imaging and Communications in Medicine (DICOM) files, made surgical guides without a guide sleeve in a new, keyless system.
3.	Derksen et al., 2019 <sup>21</sup>	The accuracy of computer-guided implant surgery with tooth-supported, digitally designed drill guides based on CBCT and intraoral scanning. A prospective cohort study	Implantation using surgical templates – the initial qualification of patients included 68 study participants. Based on CBCT results, 2 patients were excluded due to insufficient bone width and the need for horizontal bone augmentation. Cone beam computed tomography was also used to determine the standard deviation of the implant position. Digitally designed and printed 3D drill guides/surgical templates were created based on both (intra-oral scans (IOS) and CBCT data.
4.	Horsch et al., 2021 <sup>22</sup>	Predictability and image quality of low-dose cone-beam computed tomography in computer-guided implantology: An experimental study	The study was designed to test the predictability and image quality of low-dose cone beam computed tomography (LD-CBCT). The aim was to reduce the radiation dose without compromising image quality and its usefulness in clinical analysis. The apex deflection and deflection angle of LD-CBCT were greater than in the case of high-definition cone beam computed tomography (HD-CBCT), whereas no significant differences were noticed in entry point deviation. Despite the differences, the authors claimed that the advantages of HD-CBCT could be balanced with a higher radiation dose.
5.	Kauling et al., 2019 <sup>23</sup>	Can lithium disilicate ceramic crowns be fabricated on the basis of CBCT data?	The fit of lithium disilicate CAD/CAM crowns fabricated on the basis of direct (IOS), indirect (CBCT) digitization of impressions and indirect digitization of plaster cast (extraoral scanners (EOS)) was assessed. Unfortunately, although the marginal fit of CBCT is within the clinically acceptable range, it is significantly inferior to EOS and IOS.
6.	Leisner et al., 2022 <sup>24</sup>	Measuring peri-implant bone lesions using low-dose cone-beam computed tomography	The aim of this study was to determine whether peri-implant bone changes could be accurately measured with LD-CBCT, even when the influence of surrounding tissues was taken into account. Although the surrounding tissue degrades the quality of CBCT with an LD image, the differences between the 2 technologies in terms of absolute differences are negligible. Taking into account the limitations of the in vitro study, LD-CBCT may become a useful imaging technique for tracking peri-implantation lesions while exposing patients to much less radiation.
77.	Mauad et al., 2021 <sup>25</sup>	Quantitative assessment of artefacts and identification of gaps in prosthetic crowns: A comparative in vitro study between periapical radiography and CBCT images	Determination of the diagnostic precision of CBCT scans and periapical radiographs in identifying gaps in prosthetic crowns and the number of artifacts produced in vitro by 2 separate regenerating materials. Periapical radiography remained the most economical method of identifying the maladjustment of prosthetic restorations. CBCT examinations, although more expensive than ordinary radiography (RVG), did not increase the accuracy of identifying defects in prosthetic crowns. However, they can serve as an additional diagnostic tool.
8.	Polara et al., 2022 <sup>26</sup>	Digital immediate tooth restoration: Fabricating acrylic resin interim crowns from CBCT scans for immediate implant-supported prostheses: A case series	The purpose of this clinical study was to describe a method for creating a temporary acrylic resin crown using CBCT information. Using the technique of rapid implant placement and provisional restoration, information from CBCT scans resulted in temporary acrylic resin crowns, which required fewer corrections, thus shortening the time of performing the procedure.

## Scanners in dentistry

Intraoral scanners are used to visualize the maxillary and mandibular dental processes together with their soft tissues.<sup>33</sup> They allow for digitization of dental arches to create virtual models that replace conventional dental impressions.

The scanner works by projecting a light source in the form of a laser or structured light to capture 2D images of the object

being scanned. The scanner software then processes the captured 2D images to create point clouds, which are triangulated to create a 3D surface model (mesh) of the scanned object.<sup>34</sup>

The history of intraoral scanners dates back to 1985, when a scanner called CEREC 1 was developed by Dentsply Sirona. However, the system created over 30 years ago had its limitations – it provided a 2D view of scanned images and was only used to create posts for immediate cementation.<sup>35</sup>

**Table 2.** The use of cone beam computed tomography in orthodontics in the last 5 years of publications

Number	Author and year	Title	Significance
1.	Alsino et al., 2022 <sup>27</sup>	The diagnostic accuracy of cone-beam computed tomography (CBCT) imaging in detecting and measuring dehiscence and fenestration in patients with class I malocclusion: A surgical-exposure-based validation study	The authors of the article intended to check how CBCT could increase the rate of fenestration and dehiscence detection among patients. Unfortunately, no study evaluated diagnostic accuracy, so pre-orthodontic status was assessed against the gold standard, i.e., actual clinical detection of bone defects during surgical exposure. Compared to the gold standard, the crack detection percentage was 2.5 times higher, and the fenestration detection rate was almost 3 times higher.
2.	Chun et al., 2022 <sup>28</sup>	Skeletal and alveolar changes in conventional rapid palatal expansion (RPE) and mini-screw-assisted RPE (MARPE): A prospective randomized clinical trial using low-dose CBCT	Cone beam computed tomography was used to define and visualize skeletal and alveolar changes in conventional rapid palatal expansion (RPE) and mini-screw-assisted RPE (MARPE). The main outcome of this study was the opening of the mid-palatal suture, and the secondary findings were the assessment of the skeleton, dento-alveoli and periodontium, imaged with CBCT.
3.	Halim et al., 2021 <sup>29</sup>	Preliminary study: Evaluating the reliability of CBCT images for tongue space measurements in the field of orthodontics	The aim of the study was to assess the accuracy of tongue space measurement, including tongue volume and oral air volume, using CBCT. According to the earliest findings of the study, the landmarks used to calculate the total language space are repeatable and easy to detect using CBCT.
4.	Ruetters et al., 2022 <sup>30</sup>	Low-dose CBCT imaging of alveolar buccal bone adjacent to mandibular anterior teeth: A pilot study	The aim of the study was to assess whether CBCT could be used to measure the thickness of the buccal bone in the mandible and in the anterior segment, which would be useful during orthodontic and periodontal treatment. It was noted that low-dose cone beam computed tomography (LD-CBCT) is a sufficiently accurate and practical method for measuring the bone of the buccal alveolar process adjacent to the anterior teeth of the human lower jaw.
5.	van Bunningen et al., 2022 <sup>31</sup>	Precision of orthodontic cephalometric measurements on ultra-low dose-low dose CBCT reconstructed cephalograms	The authors of the study aimed to assess whether the use of CBCT could replace the standard radiovisiography (RVG) image/radiograph during cephalometric measurements. Low-dose CBCT was used for this purpose. It turned out that CBCT allows for cephalometric measurements with small differences. However, the significant advantage is the avoidance of a high radiation dose, so using it for these purposes should be considered by orthodontists in the future.
6.	Wang et al., 2021 <sup>32</sup>	Multiclass CBCT image segmentation for orthodontics with deep learning	The study describes the use of CBCT for maxillary and mandibular segmentation, necessary to plan the correct orthodontic treatment. This is usually a long-term process performed manually/semi-automatically by the physician, which is why the authors are looking for a new method of segmentation. The study used a new MS-D network (multi-class segmentation) for CBCT scans of the jaw, teeth and background – it achieved segmentation accuracy comparable to binary segmentation, i.e., the one used by default.

Since then, the shortcomings of the scanner have been removed and the device has been improved. The current version of the system is CEREC 3D, and there is a whole list of intraoral scanners available on the market. These include, i.a., Trios 3 and Trios 4, iTero Element, iTero 2, iTero 5D Element, Dental Wings, Panda, Medit i500, Planmeca Emerald™ and Aoralscan. Of these, the Trios series shows the highest scanning accuracy. It should be noted that regardless of the type of scanner used, moving the device away from the scanned image has a negative effect and reduces the accuracy of measurements. The same happens when scanning from a different angle. It has been shown that diagonal scanning reduces the precision of mapping, so it should always be done carefully and in accordance with the manufacturer's recommendations.<sup>36</sup>

In addition to the scanning technique, the operator's experience is important. The more experienced the operator and the smaller the area to be scanned, the more precise the effect is.<sup>37</sup>

Orthodontic scanners are used at the beginning, during and after treatment. There is often a need to obtain

an image of full dental arches together with the fixed orthodontic appliances. There may be doubts about the accuracy of the obtained scan. Studies have shown that the presence of orthodontic brackets has no clinically significant effect on the scanning precision.<sup>38</sup>

### The use of scanners in prosthetics and orthodontics

For prosthetic reconstruction planning or malocclusion diagnosis, it is important to register occlusal contacts. The intraoral scanner minimizes the need to use occluding papers for this purpose, because the interocclusal record made with intraoral scanners is more accurate than the measurement using traditional physical methods.<sup>39</sup>

An important procedure in both prosthetics and orthodontics is reporting the mutual position of the maxilla and mandible at various stages of treatment. In the case of conventional methods, such registration may give false measurement results due to the deformation of the materials



**Table 3.** The use of scanners in prosthodontics in the last 5 years of publications

Number	Author and year	Title	Significance
1.	Ashraf et al., 2022 <sup>41</sup>	Influence of preparation type and tooth geometry on the accuracy of different intraoral scanners	In the case of complex tooth preparations and non-standard geometries, scanning accuracy decreases. The type of scanner also affects precision – when comparing the 3 Shape Trio, Medit i500 and Cerec Omnicam, there were no significant differences between the first 2, but they showed significantly higher accuracy than Cerem Omnicam, even when the preparation was simple.
2.	Fraille et al., 2022 <sup>42</sup>	Clinical study comparing the accuracy of interocclusal records, digitally obtained by three different devices	When comparing the accuracy of occlusal contact measurements made with the intraoral scanner, the extraoral scanner and the T-Scan III system, it was found that the intraoral scanner was the most accurate. The intraoral scanner can be successfully used to examine occlusal contacts.
3.	Park et al., 2021 <sup>43</sup>	A digital approach to the evaluation of mandibular position by using a virtual articulator	The use of an intraoral scanner together with CBCT makes it possible to assess the centric relation occlusion (CRO) and the maximal intercuspal position (MIP). This eliminates the need to wear a facebow.
4.	Park et al., 2020 <sup>44</sup>	Clinical evaluation of time efficiency and fit accuracy of lithium disilicate single crowns between conventional and digital impression	The impression of abutments for lithium silicate crowns was made by conventional and digital methods using 2 scanners – AEGIS, PO and CEREC Omnicam. The scanning time was shorter compared to the traditional method of taking impressions, which made it possible to make a single crown during one visit. The difference in the accuracy of fitting between the 2 mentioned methods was not statistically significant.
5.	Ren et al., 2020 <sup>45</sup>	Accuracy of virtual interocclusal records for partially edentulous patients	The study showed that the intraoral scanner in a partially edentulous arch can be used without fear of a decrease in the accuracy of the virtual record when a single tooth in the posterior segment is missing. When the edentulous area is more extended (3 or more teeth in the anterior and posterior parts of the arch), the record accuracy decreases.
6.	Son et al., 2021 <sup>46</sup>	Comparison of intaglio surface adjustment in the oral cavity for lithium disilicate crowns fabricated using different scanners	The intra-oral fitting of crowns made on the basis of a scan taken with 3 scanners was compared with crowns made on the basis of conventional impressions. Intraoral scanners can be used to make fitted crowns instead of the conventional method. However, the study proved that those prepared with impressions require fewer intraoral adjustments.

used. Intraoral scanners overcome this problem – there is no need for materials, so there is no deformation and the results become repeatable.<sup>40</sup>

The following tables summarize the current knowledge on the selected types as well as properties of scanners used in prosthetics (Table 3) and orthodontics (Table 4).

## Discussion

Three-dimensional models designed on the basis of CBCT can be used to perform various types of procedures, such as crown lengthening, making a surgical template, or redesigning the patient's occlusion using specialized software. This is possible by converting CBCT images from Digital Imaging and Communications in Medicine (DICOM) files to STL, which in turn can be applied to stereolithographic (STL) files from intraoral scans, and then, using 3D printers, a specific drill guide can be prepared.<sup>55,56</sup> Cone beam computed tomography is also helpful in implant prosthetics. The accuracy of imaging of bone defects around implants using CBCT was assessed by Song et al.<sup>57</sup> The study showed that CBCT is more accurate and reliable than intraoral imaging in detecting, classifying and measuring peri-implant bone defects. Based on the data obtained, it is possible

to take actions whose righteousness could not be confirmed with intraoral imaging alone.

Cone beam computed tomography tools also have their drawbacks as their accuracy can be affected by factors such as patient's movement, metal artifacts, device-specific exposure parameters, software, and manual and automated procedures.<sup>58</sup> They can reduce the precision and reliability of linear measurements in CBCT images.

The development of CBCT and CAD/CAM technologies has made it possible to create partial dentures and single crowns with precise mapping of tooth, arch and bone anatomy. Direct transfer of CBCT data to CAM software can eliminate a number of manufacturing processes. After tooth preparation, crowns can be restored directly on the prepared natural teeth, without the need to take final intraoral impressions thanks to CBCT with a voxel size of 0.125 mm, which is necessary for diagnosis and/or treatment planning.<sup>59</sup> However, CAD/CAM technology is not without its disadvantages, because prosthetic restorations are milled from large blocks and about 90% of the prefabricated blocks are lost during their machining.<sup>60</sup>

Intraoral scanners have significantly shortened the time from the patient's first visit to the completion of treatment. Omitting the stage of making a conventional impression shortens the time needed to send it to the prosthetic

**Table 4.** The use of scanners in orthodontics in the last 5 years of publications

Number	Author and year	Title	Significance
1.	Burzynski et al., 2018 <sup>47</sup>	Comparison of digital intraoral scanners and alginate impressions: Time and patient satisfaction	An intraoral scanner can be a solution for patients who experience discomfort and pain when using standard alginate masses.
2.	Ferraro et al., 2022 <sup>48</sup>	Accuracy of three-dimensional printed models derived from cone-beam computed tomography	Intraoral scanners and cone beam computed tomography (CBCT) can be used to measure tooth width and intercanine molar width, giving clinically insignificant discrepancy in results. Most deviations are noted in the area of the molars.
3.	Koch et al., 2022 <sup>49</sup>	Accuracy of indirect bonding trays – a measurement algorithm	TRIOS® 3 Shape was used to make a transfer splint, which turned out to be a digital alternative to the conventional one.
4.	Pellitteri et al., 2022 <sup>50</sup>	Comparative analysis of intraoral scanners accuracy using 3D software: An in vivo study	An intraoral scanner provides information about the shape and width of dental arches. Among CS3600, CEREC Omnicam and Trios 3Shape, the latter reproduces single teeth most accurately. Comparing the use of scanners to conventional impressions, it can be observed that scanners deform the molar area more than conventional impressions.
5.	Pellitteri et al., 2021 <sup>51</sup>	Comparison of the accuracy of digital face scans obtained by two different scanners	The Face Hunter extraoral scanner gives the opportunity to compare key parameters before and after treatment, which is why it is a very good clinical tool for routine assessment of treatment effectiveness. It can also replace the X-ray in the youngest patients. The image obtained from this scanner can be compared with the image of hard tissues obtained from computed tomography.
6.	Sfondrini et al., 2018 <sup>52</sup>	Computerized casts for orthodontic purpose using powder-free intraoral scanners: Accuracy, execution time, and patient feedback	Intraoral scanners show accuracy comparable to alginate impressions. They can be used to reduce the waiting time for the final product to be picked up from the lab. Scanning takes less time than taking a conventional impression, which is especially important for patients with a gag reflex.
7.	Schnailendran et al., 2022 <sup>53</sup>	Accuracy and reliability of tooth widths and Bolton ratios measured by ClinCheck Pro	The Clincheck Pro scanner was used to measure the tooth width and Bolton ratio. This scanner, compared to the 3D OP and a calibrated digital caliper, underestimates the tooth width.
8.	Song and Kim, 2020 <sup>54</sup>	Accuracy on scanned images of full arch models with orthodontic brackets by various intraoral scanners in the presence of artificial saliva	The accuracy of mapping full arches with 3 types of brackets – ceramic, metal, resin, and without brackets using CS3600, i500, Trios3 was compared. Metal or resin brackets showed greater discrepancies. Regardless of the bracket type, CS3600 and Trios3 gave more accurate results than i500.

laboratory, as well as the time needed for corrections caused by a communication error between the doctor and the technician.<sup>61</sup> Regarding the aforementioned communication, the scanner is also a tool that helps in mutual understanding between the doctor and the patient. Presentation of a prosthetic or orthodontic problem by means of a scan displayed on the monitor screen better illustrates the scale of the problem to the patient and makes it possible to avoid misunderstandings resulting in the failure to meet the patient's expectations or irreversible damage to the patient's tissues. In the patient–doctor–technician relationship, the mapping of the patient's oral tissues using a scanner instead of conventional impressions reduces the risk of cross-infection, which is important given the existing problem of unsatisfactory awareness of dental technicians about infection control.<sup>62</sup> Al-Mortadi et al. assessed the knowledge of dental technicians in Jordan about infection control and their practice of disinfection.<sup>63</sup> Over 40% of laboratories admitted that they did not adequately disinfect both alginate and silicone impressions. Most (more than half) of the laboratory owners believe that disinfection of impressions is only the dentist's responsibility before sending them to laboratory, and 38%

of the respondents declared that they did not use gloves in the laboratory.

Specialists from all fields of dentistry, especially orthodontics and prosthetics, would not be able to fully solve the patient's problems without imaging. Scanners are a very good clinical tool for routine assessment of treatment effectiveness. Due to the fact that data are collected in files on a computer, there is no problem with the lack of space for the required storage of plaster models for 20 years after treatment. Nevertheless, the CBCT scanner is quite large, which is its disadvantage, as is its price.<sup>64</sup>

Scanned images provide essential information needed for digitally assisted design and even fabrication of full dentures. Data obtained with scanners are often more precise and accurate than those obtained with analogue impressions.<sup>65</sup> Al-Atyaa and Majeed proved that the impression technique had a significant impact on the marginal and internal seal of CAD/CAM monolithic zirconia crowns.<sup>66</sup>

Differences in mean values of marginal fissures caused by the impression technique were statistically significant. Zirconium oxide crowns made using an intraoral scanner showed a better marginal and internal fit than crowns made

with conventional impression techniques. The authors also noted that, among conventional impressions, a better fit of the crowns is obtained with the use of a two-step rather than one-step impression-taking method. In turn, when comparing the discrepancy in the marginal seal of lithium disilicate crowns made in CAD/CAM technology using conventional impressions and with the use of intraoral scanners, it was found<sup>67</sup> that there is no statistically significant difference in the effects between the above-mentioned impression techniques.

A similar level of accuracy is achieved in the case of crowns made using conventional and digital impressions.

In reviews with meta-analyses performed by other authors, we can find information that IOSs are precise enough to provide full-arch digital impressions that meet clinical requirements. The accuracy of IOSs for complete arches can change depending on the clinical situation. Based on information from articles examined in another systematic review, objectives could not be precisely and objectively defined. The authors do not know which implant impression approach results in a superior passive fit of the superstructure.<sup>68,69</sup>

## Limitations

When scanners and CBCT are used, we can count on more accurate imaging of tissues and anatomical structures within the patient's head, but unfortunately there are also limitations to this technology. A large number of studies indicate the advantages of using these devices in everyday clinical practice.

However, taking into account the opinion of many prosthetic technicians working in prosthetic laboratories, it can be noticed that not all scans allow for as accurate reflection of the patient's oral cavity conditions as impressions taken, e.g., with silicone or polyether masses. They believe that impressions prepared with the use of scanners often need additional corrections, which extends the treatment time and causes additional visits to the dentist's office.<sup>46</sup>

In the case of CBCT, the main limitations that may occur during the examination are the high cost of the device, which translates into a higher cost of the examination, limited access to the radiology laboratory, and exposure of the patient to ionizing radiation.<sup>14</sup> The limitation for the physician is mainly the additional need for training, which also generates costs for the office.

## Conclusions

Cone beam computed tomography is a tool for in vivo and in vitro examinations of oral cavity tissues. Despite the existing doubts and discussions regarding the safe dose of radiation, it has been proven that cone beam tomography can be applied in various fields of dentistry, from maxillofacial surgery through prosthetics to orthodontics.

Early detection of changes in the bone and its more accurate image help to plan a safe range of tooth movements and to notice early periapical changes that are a contraindication to moving the teeth.

Intraoral scanners allow for hard tissue imaging, which can be useful in prosthetics to determine the margin of preparation during tooth preparation procedures for permanent restorations, and in both prosthetics and orthodontics to determine and design the occlusion.

Despite the discussed applications for both tools, there are still many fields of dentistry and other applications that have not been described so far, and future research may enable their widespread use in everyday dentistry.

## ORCID iDs

Wojciech Frąckiewicz  <https://orcid.org/0009-0007-0394-820X>  
Aleksandra Jankowska  <https://orcid.org/0009-0006-5268-301X>  
Monika E. Machoy  <https://orcid.org/0000-0001-5787-222X>

## References

1. Mangano FG, Admakin O, Lerner H, Mangano C. Artificial intelligence and augmented reality for guided implant surgery planning: A proof of concept. *J Dent*. 2023;133:104485. doi:10.1016/j.jdent.2023.104485
2. Setzer FC, Lee SM. Radiology in endodontics. *Dent Clin North Am*. 2021;65(3):475–486. doi:10.1016/j.cden.2021.02.004
3. Kapila SD, Nervina JM. CBCT in orthodontics: Assessment of treatment outcomes and indications for its use. *Dentomaxillofac Radiol*. 2015;44(1):20140282. doi:10.1259/dmfr.20140282
4. Jacobs R, Salmon B, Codari M, Hassan B, Bornstein MM. Cone beam computed tomography in implant dentistry: Recommendations for clinical use. *BMC Oral Health*. 2018;18(1):88. doi:10.1186/s12903-018-0523-5
5. Panchal N, Mahmood L, Retana A, Emery R. Dynamic navigation for dental implant surgery. *Oral Maxillofac Surg Clin North Am*. 2019;31(4):539–547. doi:10.1016/j.coms.2019.08.001
6. Del Llano NC, Ribeiro RA, Martins CC, Assis NMSP, Devito KL. Panoramic versus CBCT used to reduce inferior alveolar nerve paresthesia after third molar extractions: A systematic review and meta-analysis. *Dentomaxillofac Radiol*. 2020;49(4):20190265. doi:10.1259/dmfr.20190265
7. Abduo J. Accuracy of intraoral scanners: A systematic review of influencing factors. *Eur J Prosthodont Restor Dent*. 2018;(26):101–121. doi:10.1922/EJPRD\_01752Abduo21
8. Memari Y, Mohajerfar M, Armin A, Kamalian F, Rezayani V, Beyabanaki E. Marginal adaptation of CAD/CAM All-ceramic crowns made by different impression methods: A literature review. *J Prosthodont*. 2019;28(2):e536–e544. doi:10.1111/jopr.12800
9. Page MJ, McKenzie JE, Bossuyt PM, et al. The PRISMA 2020 statement: An updated guideline for reporting systematic reviews. *BMJ*. 2021;372:n71. doi:10.1136/bmj.n71
10. Machado GL. CBCT imaging: A boon to orthodontics. *Saudi Dent J*. 2015;27(1):12–21. doi:10.1016/j.sdentj.2014.08.004
11. Kaasalainen T, Ekholm M, Siiskonen T, Kortessniemi M. Dental cone beam CT: An updated review. *Phys Med*. 2021;88:193–217. doi:10.1016/j.ejmp.2021.07.007
12. Gaêta-Araujo H, Leite AF, Vasconcelos KDF, Jacobs R. Two decades of research on CBCT imaging in DMFR: An appraisal of scientific evidence. *Dentomaxillofac Radiol*. 2021;50(4):20200367. doi:10.1259/dmfr.20200367
13. De Vos W, Casselman J, Swennen GRJ. Cone-beam computerized tomography (CBCT) imaging of the oral and maxillofacial region: A systematic review of the literature. *Int J Oral Maxillofac Surg*. 2009;38(6):609–625. doi:10.1016/j.ijom.2009.02.028
14. Abdelkarim A. Cone-beam computed tomography in orthodontics. *Dent J*. 2019;7(3):89. doi:10.3390/dj7030089
15. Kiljunen T, Kaasalainen T, Suomalainen A, Kortessniemi M. Dental cone beam CT: A review. *Phys Med*. 2015;31(8):844–860. doi:10.1016/j.ejmp.2015.09.004



16. Lee C, Yoon J, Han SS, et al. Dose assessment in dental cone-beam computed tomography: Comparison of optically stimulated luminescence dosimetry with Monte Carlo method. *PLoS One*. 2020;15(3): e0219103. doi:10.1371/journal.pone.0219103
17. Bianchi J, Mendonca G, Gillot M, et al. Three-dimensional digital applications for implant space planning in orthodontics: A narrative review. *J World Fed Orthod*. 2022;11(6):207–215. doi:10.1016/j.ejwf.2022.10.006
18. Greenberg AM. Cone beam computed tomography scanning and diagnosis for dental implants. *Oral Maxillofac Surg Clin North Am*. 2015;27(2):185–202. doi:10.1016/j.coms.2015.01.002
19. Al-Humairi A, Ip RHL, Spuur K, Zheng X, Huang B. Visual grading experiments and optimization in CBCT dental implantology imaging: Preliminary application of integrated visual grading regression. *Radiat Environ Biophys*. 2022;61(1):133–145. doi:10.1007/s00411-021-00959-x
20. Chandran S, Sers L, Picciocchi G, et al. Guided implant surgery with R2Gate®: A multicenter retrospective clinical study with 1 year of follow-up. *J Dent*. 2022;127:104349. doi:10.1016/j.jdent.2022.104349
21. Derksen W, Wismeijer D, Flügge T, Hassan B, Tahmaseb A. The accuracy of computer-guided implant surgery with tooth-supported, digitally designed drill guides based on CBCT and intraoral scanning: A prospective cohort study. *Clinical Oral Implants Res*. 2019;30(10): 1005–1015. doi:10.1111/clr.13514
22. Horsch L, Labis C, Trebing CT, et al. Predictability and image quality of low-dose cone-beam computed tomography in computer-guided implantology: An experimental study. *J Dent*. 2021;112:103744. doi:10.1016/j.jdent.2021.103744
23. Kauling AEC, Keul C, Erdelt K, Kühnisch J, Güth JF. Can lithium disilicate ceramic crowns be fabricated on the basis of CBCT data? *Clin Oral Invest*. 2019;23(10):3739–3748. doi:10.1007/s00784-019-02802-6
24. Leisner LC, Tasaka A, Trebing CT, et al. Measuring peri-implant bone lesions using low-dose cone-beam computed tomography. *J Prosthodont Res*. 2022;66(2):326–332. doi:10.2186/jpr.JPR\_D\_20\_00110
25. Mauad LQ, Doriguêto PVT, Almeida DD, Fardim KAC, Machado AH, Devito KL. Quantitative assessment of artefacts and identification of gaps in prosthetic crowns: A comparative in vitro study between periapical radiography and CBCT images. *Dentomaxillofac Radiol*. 2021;50(3):20200134. doi:10.1259/dmfr.20200134
26. Polara G, Pistone F, Giorgio Alfredo S. Digital immediate tooth restoration: Fabricating acrylic resin interim crowns from CBCT scans for immediate implant-supported prostheses. A case series. *J Prosthet Dent*. 2022;127(4):578–584. doi:10.1016/j.prosdent.2020.09.042
27. Alsino HI, Hajee MY, Alkhouri I, Murad RMT. The diagnostic accuracy of cone-beam computed tomography (CBCT) imaging in detecting and measuring dehiscence and fenestration in patients with class malocclusion: A surgical-exposure-based validation study. *Cureus*. 2022;14(3):e22789. doi:10.7759/cureus.22789
28. Chun JH, De Castro AC, Oh S, et al. Skeletal and alveolar changes in conventional rapid palatal expansion (RPE) and miniscrew-assisted RPE (MARPE): A prospective randomized clinical trial using low-dose CBCT. *BMC Oral Health*. 2022;22(1):114. doi:10.1186/s12903-022-02138-w
29. Halim IA, Park JH, Liou EJW, Zeinalddin M, Al Samawi YS, Bay RC. Preliminary study: Evaluating the reliability of CBCT images for tongue space measurements in the field of orthodontics. *Oral Radiol*. 2021;37(2):256–266. doi:10.1007/s11282-020-00443-0
30. Ruetters M, Gehrig H, Kronsteiner D, et al. Low-dose CBCT imaging of alveolar buccal bone adjacent to mandibular anterior teeth: A pilot study. *Clin Oral Invest*. 2022;26(5):4173–4182. doi:10.1007/s00784-022-04389-x
31. Van Bunningen RH, Dijkstra PU, Dieters A, Van Der Meer WJ, Kuijpers-Jagtman AM, Ren Y. Precision of orthodontic cephalometric measurements on ultra low dose-low dose CBCT reconstructed cephalograms. *Clin Oral Invest*. 2022;26(2):1543–1550. doi:10.1007/s00784-021-04127-9
32. Wang H, Minnema J, Batenburg KJ, Forouzanfar T, Hu FJ, Wu G. Multi-class CBCT image segmentation for orthodontics with deep learning. *J Dent Res*. 2021;100(9):943–949. doi:10.1177/00220345211005338
33. Goodacre B, Goodacre C, Baba N. Using intraoral scanning to capture complete denture impressions, tooth positions, and centric relation records. *Int J Prosthodont*. 2018;31:377–381. doi:10.11607/ijp.5741
34. Osman RB, Alharbi NM. Influence of scan technology on the accuracy and speed of intraoral scanning systems for the edentulous maxilla: An in vitro study [published online ahead of print on December 26, 2022]. *J Prosthet Dent*. 2022. doi:10.1111/jopr.13633
35. Sannino G, Germano F, Arcuri L, Bigelli E, Arcuri C, Barlattani A. CEREC CAD/CAM chairside system. *Oral Implantol (Rome)*. 2014;7(3):57–70. PMID:25992260. PMCID:PMC4402686.
36. Amornvit P, Rokaya D, Sanohkan S. Comparison of accuracy of current ten intraoral scanners. *Biomed Res Int*. 2021;2021:2673040. doi:10.1155/2021/2673040
37. Kustrzycka D, Marschang T, Mikulewicz M, Grzebieluch W. Comparison of the accuracy of 3D images obtained from different types of scanners: A systematic review. *J Healthcare Eng*. 2020;2020:8854204. doi:10.1155/2020/8854204
38. Kang SJ, Kee YJ, Lee KC. Effect of the presence of orthodontic brackets on intraoral scans. *Angle Orthod*. 2021;91(1):98–104. doi:10.2319/040420-254.1
39. Solaberrieta E, Otegi JR, Goicoechea N, Brizuela A, Pradies G. Comparison of a conventional and virtual occlusal record. *J Prosthet Dent*. 2015;114(1):92–97. doi:10.1016/j.prosdent.2015.01.009
40. Li J, Galli M, Chen Z, Venezia P, Mangano F, Lepidi L. A novel digital technique for maintaining maxillomandibular relations in fixed prosthetic rehabilitations. *J Dent*. 2021;114:103798. doi:10.1016/j.jdent.2021.103798
41. Ashraf Y, Sabet A, Hamdy A, Ebeid K. Influence of preparation type and tooth geometry on the accuracy of different intraoral scanners. *J Prosthodont*. 2020;29(9):800–804. doi:10.1111/jopr.13202
42. Fraile C, Ferreira A, Romeo M, Alonso R, Pradies G. Clinical study comparing the accuracy of interocclusal records, digitally obtained by three different devices. *Clin Oral Invest*. 2022;26(2):1957–1962. doi:10.1007/s00784-021-04174-2
43. Park JH, Lee GH, Moon DN, Kim JC, Park M, Lee KM. A digital approach to the evaluation of mandibular position by using a virtual articulator. *J Prosthet Dent*. 2021;125(6):849–853. doi:10.1016/j.prosdent.2020.04.002
44. Park JS, Lim YJ, Kim B, Kim MJ, Kwon HB. Clinical evaluation of time efficiency and fit accuracy of lithium disilicate single crowns between conventional and digital impression. *Materials (Basel)*. 2020;13(23): 5467. doi:10.3390/ma13235467
45. Ren S, Morton D, Lin WS. Accuracy of virtual interocclusal records for partially edentulous patients. *J Prosthet Dent*. 2020;123(6):860–865. doi:10.1016/j.prosdent.2019.08.013
46. Son K, Yu B, Lee J, Son Y, Lee K. Comparison of Intaglio surface adjustment in the oral cavity for lithium disilicate crowns fabricated using different scanners. *J Prosthodont*. 2021;30(3):276–281. doi:10.1111/jopr.13259
47. Burzynski JA, Firestone AR, Beck FM, Fields HW, Deguchi T. Comparison of digital intraoral scanners and alginate impressions: Time and patient satisfaction. *Am J Orthod Dentofacial Orthop*. 2018;153(4): 534–541. doi:10.1016/j.ajodo.2017.08.017
48. Ferraro JM, Falter J, Lee S, et al. Accuracy of three-dimensional printed models derived from cone-beam computed tomography. *Angle Orthod*. 2022;92(6):722–727. doi:10.2319/021122-128.1
49. Koch P, Albrecht M, Lin W, Jost-Brinkmann P. Accuracy of indirect bonding trays: A measurement algorithm. *Int J Comput Dent*. 2022; 25(3):295–302. doi:10.3290/j.jicd.b2599775
50. Pellitteri F, Albertini P, Vogrig A, Spedicato GA, Siciliani G, Lombardo L. Comparative analysis of intraoral scanners accuracy using 3D software: An in vivo study. *Prog Orthod*. 2022;23(1):21. doi:10.1186/s40510-022-00416-5
51. Pellitteri F, Bruculeri L, Spedicato GA, Siciliani G, Lombardo L. Comparison of the accuracy of digital face scans obtained by two different scanners. *Angle Orthod*. 2021;91(5):641–649. doi:10.2319/092720-823.1
52. Sfondrini MF, Gandini P, Malfatto M, Di Corato F, Trovati F, Scribante A. Computerized casts for orthodontic purpose using powder-free intraoral scanners: Accuracy, execution time, and patient feedback. *Biomed Res Int*. 2018;2018:4103232. doi:10.1155/2018/4103232
53. Shailendran A, Weir T, Freer E, Kerr B. Accuracy and reliability of tooth widths and Bolton ratios measured by ClinCheck Pro. *Am J Orthod Dentofacial Orthop*. 2022;161(1):65–73. doi:10.1016/j.ajodo.2020.06.048
54. Song J, Kim M. Accuracy on scanned images of full arch models with orthodontic brackets by various intraoral scanners in the presence of artificial saliva. *Biomed Res Int*. 2020;2020:2920804. doi:10.1155/2020/2920804

55. Gialain IO, Pinhata-Baptista OH, Cavalcanti MGP, Cortes ARG. Computer-aided design/computer-aided manufacturing milling of allogeneic blocks following three-dimensional maxillofacial graft planning. *J Craniofac Surg*. 2019;30(5):e413–e415. doi:10.1097/SCS.00000000000005353
56. Passos L, Soares FP, Choi IGG, Cortes ARG. Full digital workflow for crown lengthening by using a single surgical guide. *J Prosthet Dent*. 2020;124(3):257–261. doi:10.1016/j.prosdent.2019.06.027
57. Song D, Shujaat S, De Faria Vasconcelos K, et al. Diagnostic accuracy of CBCT versus intraoral imaging for assessment of peri-implant bone defects. *BMC Med Imaging*. 2021;21(1):23. doi:10.1186/s12880-021-00557-9
58. Fokas G, Vaughn VM, Scarfe WC, Bornstein MM. Accuracy of linear measurements on CBCT images related to presurgical implant treatment planning: A systematic review. *Clinical Oral Implants Res*. 2018;29(S16):393–415. doi:10.1111/clr.13142
59. Şeker E, Özcelik TB, Rathi N, Yilmaz B. Evaluation of marginal fit of CAD/CAM restorations fabricated through cone beam computerized tomography and laboratory scanner data. *J Prosthet Dent*. 2016;115(1):47–51. doi:10.1016/j.prosdent.2015.08.006
60. Wang W, Yu H, Liu Y, Jiang X, Gao B. Trueness analysis of zirconia crowns fabricated with 3-dimensional printing. *J Prosthet Dent*. 2019;121(2):285–291. doi:10.1016/j.prosdent.2018.04.012
61. Mangano F, Gandolfi A, Luongo G, Logozzo S. Intraoral scanners in dentistry: A review of the current literature. *BMC Oral Health*. 2017;17(1):149. doi:10.1186/s12903-017-0442-x
62. Al-Aali K, Binalrimal S, AlShedokhi A, Al Saqer E, AlHumaid M. Infection control awareness level among dental laboratory technicians, Riyadh, Saudi Arabia. *J Family Med Prim Care*. 2021;10(4):1540. doi:10.4103/jfmpc.jfmpc\_2258\_20
63. Al Mortadi N, Al-Khatib A, Alzoubi KH, Khabour OF. Disinfection of dental impressions: Knowledge and practice among dental technicians. *Clin Cosmet Investig Dent*. 2019;11:103–108. doi:10.2147/CCIDE.S205144
64. Nasseh I, Al-Rawi W. Cone beam computed tomography. *Dent Clin North Am*. 2018;62(3):361–391. doi:10.1016/j.cden.2018.03.002
65. Impellizzeri A, Horodyski M, De Stefano A, et al. CBCT and intra-oral scanner: The advantages of 3D technologies in orthodontic treatment. *Int J Environ Res Public Health*. 2020;17(24):9428. doi:10.3390/ijerph17249428
66. Al-Atyaa TZ, Majeed AM. Comparative evaluation of the marginal and internal fitness of monolithic CAD/CAM zirconia crowns fabricated from different conventional impression techniques and digital impression using silicone replica technique (an in vitro study). *Biomed Pharmacol J*. 2018;11(1):477–490. doi:10.13005/bpj/1397
67. Abdel-Azim T, Rogers K, Elathamna E, Zandinejad A, Metz M, Morton D. Comparison of the marginal fit of lithium disilicate crowns fabricated with CAD/CAM technology by using conventional impressions and two intraoral digital scanners. *J Prosthet Dent*. 2015;114(4):554–559. doi:10.1016/j.prosdent.2015.04.001
68. García-Gil I, Cortés-Bretón-Brinkmann J, Jiménez-García J, Peláez-Rico J, Suárez-García M. Precision and practical usefulness of intraoral scanners in implant dentistry: A systematic literature review. *J Clin Exp Dent*. 2020;12(8):e784–e793. doi:10.4317/jced.57025
69. Vitai V, Németh A, Sólyom E, et al. Evaluation of the accuracy of intraoral scanners for complete-arch scanning: A systematic review and network meta-analysis. *J Dent*. 2023;137:104636. doi:10.1016/j.jdent.2023.104636